FIRST AID FOR THE®

ORTHOPAEDIC BOARDS

SECOND EDITION

- Proven high-yield facts, mnemonics, and visual aids
- Written by graduates from a top residency program who aced the OITE and the boards
- Completely updated and includes 30 pages of new high-yield material

ROBERT A. MALINZAK • MARK J. ALBRITTON • TREVOR R. PICKERING

FIRST AID FOR THE®

ORTHOPAEDIC BOARDS

Second Edition

Robert A. Malinzak, MD
Mark J. Albritton, MD
Trevor R. Pickering, MD

McGraw Hill Medical

New York / Chicago / San Francisco / Lisbon / London / Madrid / Mexico City
Milan / New Delhi / San Juan / Seoul / Singapore / Sydney / Toronto

The McGraw·Hill Companies

First Aid for the® Orthopaedic Boards, Second Edition

Copyright © 2009, 2006 by The McGraw-Hill Companies, Inc. All rights reserved. Printed in the United States of America. Except as permitted under the United States Copyright Act of 1976, no part of this publication may be reproduced or distributed in any form or by any means, or stored in a data base or retrieval system, without the prior written permission of the publisher.

First Aid for the® is a registered trademark of The McGraw-Hill Companies, Inc.

1 2 3 4 5 6 7 8 9 0 QPD/QPD 12 11 10 9

ISBN 978-0-07-159894-1
MHID 0-07-159894-4
ISSN 1554-3196

NOTICE

Medicine is an ever-changing science. As new research and clinical experience broaden our knowledge, changes in treatment and drug therapy are required. The authors and the publisher of this work have checked with sources believed to be reliable in their efforts to provide information that is complete and generally in accord with the standards accepted at the time of publication. However, in view of the possibility of human error or changes in medical sciences, neither the authors nor the publisher nor any other party who has been involved in the preparation or publication of this work warrants that the information contained herein is in every respect accurate or complete, and they disclaim all responsibility for any errors or omissions or for the results obtained from use of the information contained in this work. Readers are encouraged to confirm the product information sheet included in the package of each drug they plan to administer to be certain that the information contained in this work is accurate and that changes have not been made in the recommended dose or in the contraindications for administration. This recommendation is of particular importance in connection with new or infrequently used drugs.

This book was set in Electra LH by International Typesetting and Composition, Inc.
The editors were Catherine A. Johnson and Peter J. Boyle.
The production supervisor was Sherri Souffrance.
Project management was provided by Preeti Longia Sinha, International Typesetting and Composition, Inc.
Quebecor World Dubuque was printer and binder.

This book is printed on acid-free paper.

CONTENTS

Preface		v
Acknowledgments		vii
Introduction		ix
Chapter 1	Basic Science	1
Chapter 2	Orthopaedic Anatomy	17
Chapter 3	Orthopaedic Trauma	31
Chapter 4	Joint Arthroplasty	73
Chapter 5	Sports Medicine	105
Chapter 6	The Hand	125
Chapter 7	Foot and Ankle	149
Chapter 8	Orthopaedic Tumors	167
Chapter 9	Pediatric Orthopaedics	193
Chapter 10	The Spine	217
Chapter 11	Miscellaneous Facts	231
Index		247

PREFACE

The first edition of *First Aid for the Orthopaedic Boards* was five years in the making. Over the past eighteen months, we have revised the material for this edition to reflect the changing emphasis of the Board exam and to incorporate new data relevant to those seeking Board certification or recertification. Our aim—to provide orthopaedic exam takers with a concise resource of the most important testable orthopaedic facts—has not changed. The topics cover the high-yield subject matter on the Boards, presented in bullet-point format to facilitate easy and rapid appropriation of facts needed to answer frequently tested questions. Any minutia presented has been important on previous exams and is included to help maximize your scores. Overall, the facts presented have been collected and organized in the best manner we know possible. We invite any and all advice, criticism, and insight to help make this resource even better for you and all future test takers. We certainly have a vested interest in improving this text, as we will be preparing for recertification in just a few years ourselves!

Best of luck on examination day and it is our sincere wish that *First Aid for the Orthopaedic Boards* has enabled you to overshoot your examination goals.

Robert A. Malinzak, MD
Mark J. Albritton, MD
Trevor R. Pickering, MD

ACKNOWLEDGMENTS

Rob, Mark, and Trevor would like to thank the residents, faculty, and staff of the outstanding Duke Orthopaedic Residency Program who assisted in their orthopaedic journey. We strongly feel Duke Orthopaedics is one of the outstanding institutions in the country and are very thankful for having been a part of something so strong.

Rob thanks his lovely and brilliant wife, Dr. Sandy Moreira, for strongly standing by his side and remaining the most remarkable person he knows. Also, he gives thanks to his wonderful children, Mackenzie and Jacob, as they provide the ultimate strength for his days. And he is thankful to Mom, Dad, Dave, and Ann as they provided the structure and vision for him to arrive at this day.

Mark thanks his amazing wife, Laura, for her patience and encouragement during this process; he truly cherishes her. He also thanks his two great children, Dylan and Drake, for being the greatest inspiration in his life, and he is indebted to his parents for all of their love and support.

Trevor thanks Cris and Nora for their love and support. He thanks the Center for Hip and Knee Surgery for a wonderful opportunity. Finally, he wishes to thank Oxford Orthopaedics and Sports Medicine in Oxford, Mississippi, for a terrific partnership.

INTRODUCTION

Congratulations on continuing your journey toward orthopaedic board credentialing. The trek began with SATs, MCATs, and USMLEs only now to include the very relevant OITE, our Step I Orthopaedic Board Examination and the 10-year Recertification Examination. No matter which portion of the journey you are currently traversing, *First Aid for the Orthopaedic Boards* will prepare you for your current exam by offering the detailed high-yield facts popular on such exams. We have not prepared a thorough orthopaedic encyclopedia, as there are several excellent resources that provide this amount of orthopaedic detail. The thrust of our composition is to provide medical professionals, medical students, orthopaedic residents, and orthopaedic surgeons with the relevant key, testable orthopaedic information. This concise compilation of orthopaedic facts will certainly benefit your understanding of orthopaedics, not only for the exam, but also for your medical practice.

We have scoured the popular examinations and are presenting the most recent frequently tested facts required for passing such examinations. Also included are mnemonics, tables, charts, and figures that we found helpful in keeping certain obtuse, yet important facts in the rapid recall portion of our cranium.

▶ BACKGROUND

The *Orthopaedic In-Training Examination* (OITE) is given each November and is an excellent measuring stick of your progress through residency. This examination is administered at your local training program and is an untimed examination. Different institutions vary the test-day format, but the overall purpose of this annual examination is for the resident to take note of his/her orthopaedic progress. The quick rule is that if you score in the lower third of your class's scale, you have a high chance of failing the real board examination. On the other hand, if you score in the top third, you are almost assured of passing the real examination. Those in the middle third have more variable chances. Overall, the better prepared you are throughout residency and the OITE, the more likely you will be able to perform very well on the day of your Step I examination.

After completing residency you will be expected to take and pass Step I of the orthopaedic certification process. Step I is administered each July in Chicago. Registration needs to be completed by March of your testing year. The American Board of Orthopaedic Surgery (ABOS) has an excellent Web site (www.abos.org) for you to check dates and progress, as well as hotel and travel arrangements. We recommend making your hotel and travel plans well in advance. Everyone has heard of examinees traveling and arriving the night before the test in

a frenzy as their flight, car, or other travel plans ran amok. If possible, arrive 2 days in advance to alleviate that portion of possible stress and get the lay of the land.

Step I of the orthopaedic board exam is a one-day written examination including 320 questions administered in two 3.5-hour sessions. An hour is allocated for lunch. The board offers that there is no curve and no predetermined failure rate. Approximately 30–35% of the questions are known as they have been given on prior tests, and the Board knows how these questions should play out. A score of 70% correct answers (or 224 out of 320) should get you through the passing door. First-time test takers from the United States and Canada have a pass rate of around 93% and repeat takers a 40% pass rate (but that was before this book was available!). After successfully taking the Step I examination, you go home and await your scores, which arrive in about 8 long weeks.

Step II of the orthopaedic board certification process is the oral examination, which occurs on completion of your second full year in practice. You will provide to the Board at your expense a complete list of every surgical case you performed from July through December. Then you will be expected to bring with you to the exam all the relevant information on 10 of the 12 cases the Board asks you to discuss. This list includes clinic notes, operative reports, x-rays (pre- and postop), and follow-up notes. Thorough documentation is crucial, and prompt organization is vital for your oral board examination.

Recertification is now required every 10 years for orthopaedic surgeons. Although there are several courses to quickly relearn the minutia required for the exam, *First Aid for the Orthopaedic Boards* will enable you to have the most important facts at your fingertips. You can study in between cases during room turnover, in clinic, and in any other few minutes you find.

In the end, your preparedness for the examination will pay huge dividends. *First Aid for the Orthopaedic Boards* will enable you to feel secure in your ability to handle the key testable orthopaedic information. Remember that guessing cannot hurt you on the few questions that you are not sure of and that most would offer that your first choice is usually the better of your responses. We hope to have provided you with a resource that allows you to improve your orthopaedic knowledge in a way that best uses what little "free" time you may have.

We wish you the very best on your voyage toward the examination. Our goal is for every reader of *First Aid for the Orthopaedic Boards* to not only pass the examination but to do significantly better than his/her initial expectation. We trust that the facts and information provided here are true to the best of our ability. Any mistakes are our sole responsibility and are absolutely unintended. We appreciate any and all constructive criticism, noted omissions, future mnemonics, or other ideas that can make *First Aid for the Orthopaedic Boards* a stronger text for future Step I and recertification candidates.

CHAPTER 1

Basic Science

Bone 2

- Bone Matrix 2
- Bone Metabolism 3
- Bone Disorders 3
- Fracture 5
- Bone Grafts 5
- Physeal Zones (RPHM) 6

Cartilage 6

- Articular Cartilage Layers 6
- Collagen Types 7

Muscle 7

Ligaments 8

Nerves 8

- Encapsulated Skin Receptors 8
- Nonencapsulated Skin Receptors 9

Genetics, Immunology, Molecular Biology 9

- Microbiology, Infections, Antibiotics, and Other Medications 11
- Antibiotic Mechanisms of Action 12

Coagulation 13

- Biomechanics 14

Bone Matrix

- 40% organic: Primarily collagen I, gives tensile strength.
- 60% inorganic: Primarily hydroxyapatite, gives compressive strength.
- Proteoglycans: Compressive strength, made of glycosaminoglycans (GAG) complexes.
- Osteocalcin: Made by osteoblasts; attract osteoclasts, inhibited by parathyroid hormone (PTH), stimulated by 1,25-dihydroxy vitamin D (1,25-[OH_2]D). Regulates bone density.
- Osteonectin: Secreted by platelets and osteoblasts, matrix mineralization.
- Osteopontin: Cell binding protein.
- Important cytokines and growth factors for bone:
  - Transforming growth factor-β (TGF-β): Causes mesenchymal cells to differentiate into osteoblasts; present in fracture callus.
  - Insulin-like growth factor (IGF): Stimulates type I collagen, involved in cartilage matrix synthesis.
  - Interleukin-1 (IL-1): Stimulates osteoclasts.
  - Bone morphogenic protein (BMP).

Osteoblasts produce type I collagen; high alkaline phosphatase activity.

- From undifferentiated mesenchymal cells (controlled by *Cbfa*, platelet-derived growth factor [PDGF], and insulin-derived growth factor [IDGF]).
- Downregulated directly by PTH, glucocorticoids, prostaglandins (PGEs), and leptin.
- Upregulated by estrogens.
- Produce osteocalcin when stimulated by 1,25-(OH_2)D, which in turn upregulates osteoblasts.

Osteoclasts resorb bone and are irregularly shaped giant cells.

- Ruffled boarders increase surface area.
- Binds to bone via integrins.
- IL-1 is a potent stimulator.
- Produce tartrate-resistant acid phosphatase.
- Receptors for calcitonin which inhibit bone resorption.
- Pamidronate inhibits osteoclasts.
- Resorbs bone in multiple myeloma and metastatic disease.

RANKL:

- Released by osteoblasts.
- Binds to RANK receptor on osteoclast.
- Activates osteoclast.
- Leads to bone resorption.
- Important in bone metabolism and tumors—especially multiple myeloma.
- Osteoprotegerin (**OPG**) is a decoy inhibitor and stops osteoclast activation.
- **Upregulate RANKL and downregulate OPG (increase bone resorption/destruction):**
  - PTH
  - 1,25-(OH_2)D
  - IL-1β
  - Tumor necrosis factor-α (TNF-α)
  - PGE2
- Downregulate RANKL and upregulate OPG (decrease bone resorption/destruction):

- IL-4
- TNF-β
- Interferon N gamma

Bone is resorbed by osteoclasts not only in bone homeostasis but bone-destroying tumors.

Bone Metabolism

- Vitamin D strongly stimulates absorption of calcium (Ca) and phosphateinositol (PO_4) from intestines.
- *1-α hydroxylase activates* vit D (25[OH]-VitD to 1,25[OH_2]-VitD).
- PTH stimulates production of 1,25-(OH_2) vitamin D, Ca elevated, Pi lowered.
- Calcitonin from clear cells of the thyroid gland:
  - Decreases osteoclast activity and number while decreasing the tubular resorption of Ca and PO_4.
  - Lowers serum Ca levels.
  - Osteoclasts have receptors for calcitonin.
  - Inhibits osteoclast bone resorption (i.e., lowers Ca).
- Corticosteroids cause low bone formation and high resorption, but retain normal trabecular osteoid volume.
  - Increased Ca loss, reduced Ca absorption.
- Estrogen reduces femoral neck fracture rate and increases bone density in the femoral neck.
  - Limits bone loss by limiting bone resorption.
  - Ca and PO_4 metabolism involves skin, liver, kidney, intestines, thyroid, parathyroid glands.
  - Ca requirements:
    - Lactating women, 2000 mg/d.
    - Pregnant women, 1500 mg/d.
    - Postmenopausal woman with healing fracture, 1500 mg/d.

RANKL is the primary mediator of osteoclast activation.

Bone Disorders

- *Osteomalacia* is due to an inability to maintain serum Ca and phosphate levels.
- Most patients will have normal hemoglobin and low Ca and PO_4.
- Osteomalacia in renal osteodystrophy is most often the result of aluminum-containing phosphate-binding antacids.
- *Osteopetrosis*: Failure of osteoclastic and chondroclastic resorption.
  - Autosomal dominant.
  - Lack of marrow-derived osteoclast precursor cells (Albers-Schönberg disease).
- *Osteoporosis* has *normal* bone mineralization and abnormal osteoclast function.
- World Health Organization (WHO) definition is > 2.5 standard deviations (SD) below peak bone mass of a 25-year-old.
- T score below -2 SD from "normal" young female, initiate treatment.
  - If -1.5 and risk factors, start treatment.
  - Z score is versus own age-matched controls.
- Menopause associated with 2%–3% per year bone loss for 6–10 years.
- **Type I postmenopausal:** Trabecular bone; distal radius and vertebral fractures.
- **Type II senile:** Trabecular and cortical bone; hip and pelvic fractures.
  - Senile osteoporosis is the uncoupling of bone formation and resorption.
- *Idiopathic transient osteoporosis* (ITOH) (see Figure 1-1):
  - Unknown etiology affecting pregnant females or late-middle-aged males.

1-α hydroxylase activates vit D (25[OH]-VitD to 1,25[$OH]_2$-VitD)

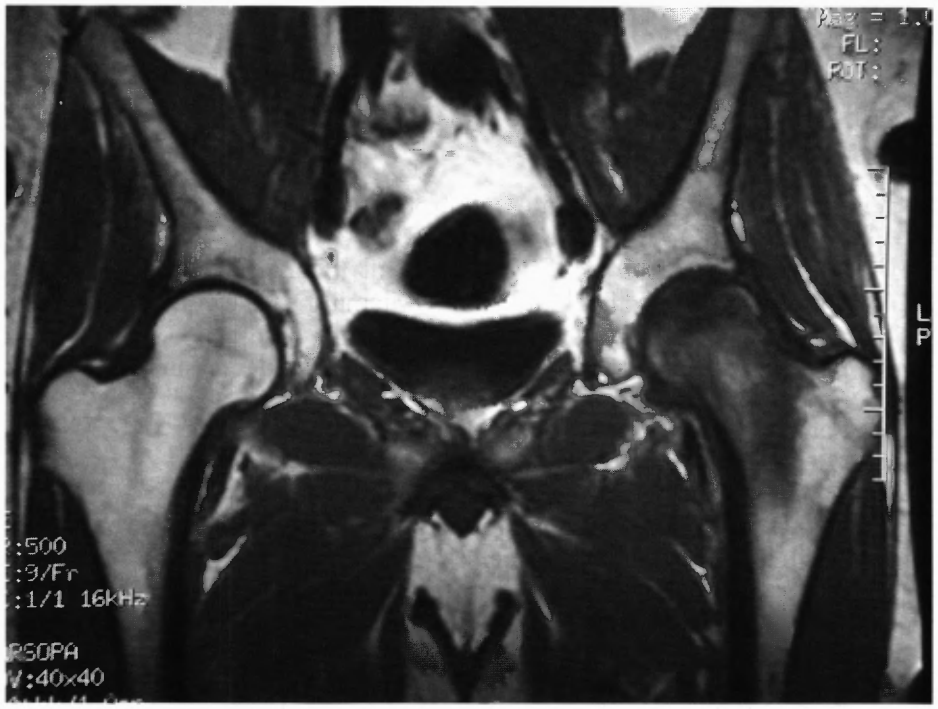

FIGURE 1-1. Idiopathic transient osteoporosis of the hip (ITOH). Notice the decreased signal in the affected left hip.

- Presents with a painful hip and magnetic resonance imaging (MRI) evidence of diffuse osteoporosis.
- Treat with protected weight bearing.
- Some advocate calcitonin to alleviate the pain.
- Resolves with time.

- *Rickets:* Failure in zone of provisional calcification (i.e., a part of the hypertrophic zone).
- **Primary hyperparathyroidism: parathyroid adenoma:**
  - Increased: Serum Ca, PTH, 1,25-VitD, urine Ca, Alk Phos (or normal)
  - Decreased: Serum Phos
  - Normal: 25 VitD
- **Hypoparathyroidism:**
  - Increased: Serum Phos
  - Decreased: Serum Ca, PTH, 1,25-Vit D, urine Ca
  - Normal: Alk Phos
- **Pseudohypoparathyroidism** (genetic disorder, resistance to PTH):
  - Increased: PTH (or normal), Serum Phos
  - Decreased: Serum Ca, 1,25-VitD, urine Ca
  - Normal: PTH (or increased), Alk Phos, 25 VitD
- **Vit D deficiency rickets:**
  - Increased: PTH, Alk Phos
  - Decreased: Serum Ca (or normal), Serum Phos, 25 VitD, 1,25-VitD, urine Ca
- **Hypophosphatemic rickets** ("phosphate diabetes")
  - X-linked dominant
  - Most common form of rickets
  - Decreased: Serum Phos

Osteoporosis is a quantitative problem, whereas osteomalacia is a qualitative problem.

- Normal: Serum Ca, PTH, 25 VitD, 1,25-VitD, urine Ca
- Treatment: Phosphate and vit D (to offset effect of phosphate supplementation)

Fracture

- Fracture repair: Inflammation, soft callus, hard callus, then remodeling.
- Initial response: Decreased blood flow.
- Maximum vascularization at the fracture occurs around 2 weeks.
  - Blood flow normal at 3–5 months.
  - Inflammation 24–72 hours.
  - Primary callus repair happens within 2 weeks.
  - Soft callus is converted to hard callus by *enchondral* ossification.
  - Amount of callus indirectly proportional to amount the fracture is immobilized.
  - Remodeling up to 7 years.
- Unstable fracture repair has type II collagen early, then type I collagen later.
- Bone is weaker in tension than compression, thus get transverse fracture with three-point bending.
- Bending forces result in transverse with butterfly fracture.
- Torsion causes spiral fracture.
- Cast: Periosteal bridging callus, enchondral ossification.
- Rigid compression plate: Primary bone healing, cutting cone remodeling.
  - Near cortex: Direct Haversian remodeling, inhibits callus formation.
  - Far cortex: Often, there is a gap. Gap healing: Lamellar bone is 90 degrees to longitudinal axis of bone.
- IM nail:
  - Early: Periosteal callus
  - Late: Medullary callus
- Enchondral ossification.
- Ex-fix: If rigid: Primary healing; less rigid: Periosteal callus.
- Hypertrophic nonunion: Failed endochondral ossification, no osteoid, mostly type II cartilage.
- Smoking decreases the eventual strength of the healed fracture.
- *Blood flow* is the main determinant in fracture healing.
- Medial clavicle ossifies at 25 years old.

Fracture healing is most affected by vascularization, and smoking decreases healing fracture strength.

Amount of callus indirectly proportional to amount the fracture is immobilized.

Bone Grafts

- Osteoinduction: Signals local factors to stimulate bone formation.
- Osteoconduction:
  - Scaffold for new bone
  - Includes Ca phosphate, Ca sulfate, Ca carbonate, coralline hydroxyapatite
- Osteogenic cells lead the rebuilding effort.
- Cortical bone graft:
  - Structural support
  - Remodels existing Haversian system by resorption then deposition of new bone
  - Weak during resorption phase
- Cancellous bone graft:
  - No resorption of old trabeculae.
  - Osteoblasts put down new bone on old trabeculae (creeping substitution).
  - Quickly revascularized.

- Fresh versus fresh frozen versus freeze-dried.
- Intercalary allografts: Most common complication is nonunion (–38%).
- Frozen syngeneic allografts have best incorporation.
- **Distraction osteogenesis:** Anterior tibial artery shows significant increase in the number of *vaso vasorum*.
- Latency phase, distraction phase, consolidation phase.
- Ideal growth is 1 mm/d (lengthen 0.25 mm four times a day).
- Host repair after avascular necrosis (AVN) is **creeping substitution**.

Bone Grafts

Graft	Osteoconduction	Osteoinduction
Autograft		
Cancellous	Excellent	Good
Cortical	Fair	Fair
Allograft	Fair	Fair
Ceramics	Fair	None
DBM	Fair	Good
Bone Marrow	Poor	Poor

Physeal Zones (RPHM)

Various diseases that affect the physis occur at specific areas of the physis.

- **Reserve zone: PK GD** (Reserve Place Kicker has Good Distance)
  - Pseudoachondroplasia
  - Kneist syndrome
  - Gaucher disease
  - Diastrophic dysplasia
- **Proliferative zone: GPA** (big and small)
  - Gigantism
  - Achondroplasia
- **Hypertrophic zone: MORE Sex Please**
  - Mucopolysaccharidoses
  - Osteomalacia
  - Rickets
  - Enchondroma
  - Slipped capital femoral epiphysis (SCFE)
  - Physeal fracture
- **Metaphysis**
  - SCFE *with endocrinopathy*

▶ CARTILAGE

Articular Cartilage Layers

See Table 1-1.

TABLE 1-1. Articular Cartilage Layers

Zone	Specific Characteristics	Shear Vs. Compression
Superficial zone (gliding)	Decreased metabolic activity	vs. Shear
Middle zone (transitional)	Increased metabolic activity	vs. Compression
Deep zone (radial)	Increased collagen size	vs. Compression
Tidemark	Undulating barrier	vs. Shear
Calcified zone	Hydroxyapatite crystals	Anchor

- Greatest tensile stiffness in the superficial zone.
- Proteoglycans are responsible for retaining water in the matrix.
- Link proteins: Link hyaluronate and proteoglycans.
- Fibrocartilage and type I collagen are at areas of articular cartilage injury that goes deep across the tidemark.
- Anchorin II: Binds to chondrocytes.
- COMP (cartilage oligometric protein): Binds to chondrocytes.
- Protect cartilage: TGF-β, Smad3, IGF, BMP-2, BMP-7.
- Breakdown cartilage: IL-1, TNF-α, cyclooxygenase-2 (COX-2), nitric oxide synthase (NOS).

Proteoglycans retain water in cartilage.

Collagen Types

- Type I: Meniscus, bone, tendon, skin, and annulus fibrosis.
- Type II: Main contributor in articular cartilage and nucleus pulposus.
- Type VI: Increased in osteoarthritis (OA).
- Type X: Endochondral ossification.

▶ MUSCLE

- Isotonic: Eccentric and concentric phases; tension constant, length changes (biceps curl).
- Isokinetic: Velocity constant, measures dynamic strength, most efficient way to strengthen muscles; use Cybex.
- Isometric: Length constant, tension changes; measures static strength; push on a wall.
- Slow-twitch type I muscle fibers: "Slow red ox(idative)":
  - Low strength of contraction, more mitochondria, aerobic.
  - Endurance activities.
- Fast-twitch type II muscle fibers:
  - High anaerobic capacity, large motor unit size, high strength, fast speed of contraction.
  - Low aerobic capacity, low capillary density, and most fatigable.
  - Sprinting activities.
- Irreversible side effects of anabolic steroids include:
  - Growth retardation.
  - Male pattern baldness.
  - Deepening of voice.
- Fatigue reduces a muscle's ability to absorb energy.
- Muscle laceration midsubstance: Dense scar connective tissue (recover 50% tension ability).
- Muscle–tendon junction is most common site of strains.

Slow-twitch muscles are red and have more mitochondria; fast-twitch muscles are white with less mitochondria and therefore are anaerobic.

- Myasthenia gravis: Decreased number of acetylcholine receptors.
- Myofibroblast has intracellular actin microfilaments (stress fibers); found in Dupuytren disease.
- Paracrine: Local cell produces molecule to act on nearby cell.
- Autocrine: Stimulates same cell that produced the molecule.

▶ LIGAMENTS

- Type I collagen
- MRI: Ligaments low signal on T1 and low signal on T2.
- Ligament healing is with type III collagen early and then type I collagen.
- Children have avulsion injuries more often.
- Adults have midsubstance injuries more often.
- **Ligament insertion:**
  - Ligament → fibrocartilage → mineralized fibrocartilage → bone.
  - Avulsion occurs between unmineralized and mineralized fibrocartilage layers.

▶ NERVES

- Sensory axon carries impulse from periphery to cell body located in the **dorsal root ganglion.**
- **Neurapraxia:**
  - Fiber failure sequence → motor, proprioception, touch, temperature, pain.
  - Axon continuity maintained
  - Reversible, no Wallerian degeneration
- **Axonotmesis:**
  - Axon severely damaged or severed.
  - Endoneural tube (Schwann cells) intact.
  - Wallerian degeneration.
  - Good recovery.
  - Preserve conduction velocities for up to 7 days, 2–5 weeks, have fibrillations with positive sharp waves.
- **Neurotmesis:**
  - Loss of endoneural continuity.
  - Perineurium and fascicle arrangement intact.
  - Wallerian degeneration.
  - Recovery variable.
- **Neuropathic joint** (3 Ds—dislocation, destruction, and degeneration).
  - Shoulder: Consider syrinx.
  - Hip and knee: Tabes dorsalis.
  - Foot and ankle: Diabetic neuropathy.

Encapsulated Skin Receptors

See Table 1-2.

TABLE 1-2. Characteristics of Encapsulated Skin Receptors

Pacinian corpuscles	Flutter	Fast adapting, high frequency
Meissner corpuscles	Touch	Fast adapting, low frequency
Ruffini end organs	Vibration	Slow adapting, low frequency

TABLE 1-3. Characteristics of Nonencapsulated Skin Receptors

Merkel cells	Steady skin indentation	Sustained response to pressure
Free nerve endings	Mechanical, thermal, noxious	Warm, cold, sharp, dull

Nonencapsulated Skin Receptors

See Table 1-3.

- Vibration-induced peripheral neuropathy: Increased vibration and temperature thresholds.
- Posterior columns: Pain and temp (crossover two levels up).
- Anterior columns: Vibration, proprioception, and light touch.
- Sciatic nerve usually lies anterior to piriformis and posterior to quadratus femoris, obturator internus and externus, and superior gemellus.
- Superficial peroneal nerve: Medial dorsal cutaneous nerve (to the dorsal medial great toe metatarsophalangeal joint [MTP]) commonly injured during approach for hallux valgus.
- Axillary nerve: Deltoid and teres minor (injured in open Bankart repair).
- Suprascapular nerve: Spinoglenoid notch entrapment with infraspinatus weakness (suprascapular notch = supra- and infraspinatus weakness).

▶ GENETICS, IMMUNOLOGY, MOLECULAR BIOLOGY

See Table 1-4 for genetic keys.

- **Marfan syndrome:** Fibrillin defect on *chromosome 15*.
- **Homocystinuria:** Autosomal recessive, deficiency of *cystathionine*.
- **Ankylosing spondylitis:** Back pain associated with morning stiffness, improves with exercise.
- **Rheumatoid arthritis** has nodules on the posterior ulnar border and pulp surfaces.
  - Implicated cytokines involve TNF and interleukin-1 (IL-1).
- **Juvenile rheumatoid arthritis (JRA):** Positive rheumatoid factor (RF) < 15%.
- **Gaucher disease:** Elevated *glucocerebrosides*; Erlenmeyer flask distal femur, AVN of femoral heads, anemia, hepatosplenomegaly, abnormal liver function, neurologic symptoms, pathologic fractures, bone infarcts. Treat with splenectomy and enzyme replacement.
- **Alkaptonuria** (ochronosis): Elevated *homogentisic acid*.
- **Reiter syndrome:** Reactive arthritis—polyarthritis, uveitis (cervicitis), and conjunctivitis.
  - "Can't see, can't pee, and can't climb a tree."
  - Bilateral heel pain often; treat with nonsteroidal anti-inflammatory drugs (NSAIDs).
- **Achondroplasia:** *Fibroblast growth factor-3 (FGF-3) receptor* alteration; trident hand, rhizomelic (proximal) shortening.
- **Calcium pyrophosphate deposition (CPPD):** Positive birefringence, short-trapezoidal/positive/blue.
- **Gout:** Monosodium urate crystals, inhibited by colchicine, negative birefringence, long needle shaped/yellow.
- FGF-3 receptor changes (**AD**): Achondroplasia, hypochondroplasia, thanatophoric dysplasia.
- Fat emboli syndrome seen sooner than pulmonary embolus.

TABLE 1-4. Genetic Keys

COMP	Pseudoachondroplasia, MED (type I), OA
FGF-3	Achondroplasia, hypochondroplasia, thanatophoric dysplasia
FGF-2	Apert's syndrome, Jackson-Weiss, Crouzon's, most Pfeiffer's syndromes
Collagen II	SED congenital, DD, Kneist syndrome, Stickler syndrome, hypochondrogenesis, type II achondrogenesis, precocious osteoarthropathy
Collagen IX	MED (type II)
SEDL gene	SED tarda
PTH-related protein	Jansen's metaphyseal chondrodysplasia
Collagen X	Schmid's metaphyseal chondrodysplasia
EXT1, EXT2 genes	MHE
Sulfate transport gene	DD
Core-binding factor	Cleidocranial dysplasia
Carbonic anhydrase II proton pump mutation	Osteopetrosis/osteoclasts
COL 1A1 (pro-alpha 1 (I) collagen gene)	Osteogenesis imperfecta
COL 2A1	Kneist syndrome (PTH receptor problem)
PEX	X-linked hypophosphotemic rickets
t(X;18)	Synovial sarcoma (lymphatic spread)
t(2;13)	Rhabdomyosarcoma, alveolar
t(12;16)	Myxoid liposarcoma
t(9;22)	Chondrosarcoma
t(12;22)	Clear cell chondrosarcoma
t(11;22)	Ewing's sarcoma
Dystrophin absent	Duchenne MD
Dystrophin abnormal	Becker MD

TABLE 1-4. Genetic Keys (*continued*)

Survival motor neuron	Spinal muscular atrophy
Peripheral myelin protein 22	CMT type IA
Connexin 32	CMT X-linked
Neurofibromin (tumor suppressor gene)	NF1
Merlin	NF2
Schwannomin	NF2
Fritaxin	Friedreich's ataxia
Fibrillin	Marfan syndrome
G protein activated	Fibrous dysplasia
Elastin	Fragile X
Bone sialoprotein	RA, advanced
Hyaluronan-binding protein	RA, advanced
Glucocerebroside elevated	Gaucher disease
Homogentisic acid	Ochronosis (alkaptonuria)
CPPD	Pseudogout
Hydroxyproline elevated	Paget disease
Cystathionine	Homocystinuria

CMT = Charcot-Marie-Tooth; COMP = cartilage oligomeric matrix protein; CPPD = calcium pyrophosphate deposition; DD = diastrophic dysplasia; FGF = fibroblast growth factor; MD = muscular dystrophy; MED = multiple epiphyseal dysplasia; NF = neurofibromin; OA = osteoarthritis; PTH = parathyroid hormone; RA = rheumatoid arthritis; SED = spondyloepiphyseal dysplasia.

Microbiology, Infections, Antibiotics, and Other Medications

- Infection: Mixed cell population.
- **Toxic shock syndrome:** *Staphylococcus aureus* in a benign-looking wound.
- **Gas gangrene:** Infection of muscle most often from contaminated injury.
  - *Clostridium perfringens;* treat with clindamycin and penicillin (PCN) G.
- Metaphyseal osteomyelitis: Pediatric metaphyses within their joint capsules.
  - Proximal femur, proximal humerus, radial neck, distal fibula
- Osteomyelitis: Cierney's classification (medullary, superficial, localized, and diffuse).
- Wound healing requirements: Albumin > 3, total lymphocyte count > 1500, ankle-brachial index > 0.45 or 0.35, transcutaneous O_2 > 35.

- ***Sporothrix:*** Treat with potassium iodide solution; occurs in plant handlers (roses).
- ***Bartonella:*** Cat scratch disease (palpable epitrochlear nodes).
- **Lyme disease:** *Borrelia burgdorferi* is the bacteria from the tick *Ixodes*—bull's-eye rash.
  - Treat with doxycycline or amoxicillin.
  - Polyarticular septic arthritis.
  - "Great mimicker" and erythema chronicum migrans.
- **Sickle cell disease:** *Salmonella* infections more common.
- Intravenous (IV) drug abusers: *Serratia* and *Pseudomonas*.
- Meat handlers: *Brucella*.
- Rheumatoid arthritis: S. *aureus*.
- Total joint infection late: After dental procedure, think of *Peptostreptococcus*.
- Shoe puncture: *Staphylococcus* is most common, but *Pseudomonas* is most characteristic.
- Electrical burns: Concern for meningococcemia.
- Paget disease: Associated with paramyxovirus.
- Ankylosing spondylitis: Associated with *Yersinia* or *Klebsiella*.

Cat scratch disease has palpable epitrochlear lymph nodes and is caused by Bartonella. *Cat bites often inoculate with* Pasteurella multocida.

Antibiotic Mechanisms of Action

- **Inhibit cell wall synthesis**
  - PCN inhibits peptidoglycan synthesis.
  - Cephalosporins inhibit peptidoglycan synthesis.
  - Vancomycin.
  - Bacitracin.
  - Aztreonam.
  - Imipenem.
  - Beta-lactams bind to surface of cell membrane.
- **Increase cell membrane permeability**
  - Polymyxin—gram-negative
  - Nystatin—antifungal
  - Amphotericin—antifungal
- **Ribosomal inhibition**
  - Bacteriostatic: Aminoglycosides, clindamycin, erythromycin, tetracycline
    - Inhibit protein synthesis by binding to ribosomal RNA.
  - Bactericidal: Gentamicin, streptomycin, tobramycin, amikacin, neomycin.
    - Bind 30S subunit (or 50S, 80S), misread messenger RNA.
    - Mostly gram-negative.
  - Rifampin inhibits RNA synthesis in bacteria.
- **DNA transcription and translation**
  - Quinolones—tendon ruptures; do not give to children (inhibit DNA gyrase).
  - Rifampin—inhibits RNA polymerase.
  - Metronidazole—for anaerobes.
- **Complications**
  - Aminoglycosides: Ears and kidneys.
  - Tetracycline: Stains teeth; do not give to children.
  - Cephalosporins: Relatively nontoxic, good in orthopaedics.
  - Clindamycin: Obtains highest bone concentrations.
  - Rising concern for gentamicin-resistant organisms due to antibiotics in primary cemented joints.
  - Ciprofloxacin: Tendon ruptures.
  - Imipenem: Seizures.

Beware of renal problems with aminoglycosides.

▶ COAGULATION

- Coumadin:
  - Potentiators (FEAST BCD HSP)
    - Flagyl
    - Erythromycin
    - Aspirin
    - Sulfa
    - Tagamet (cimetidine)
    - Bactrim
    - Cefamandole
    - Disulfamide
    - Heparin
    - Septra
    - Phenytoin
  - Inhibitors (CPR-VD)
    - Cholestyramine
    - Phenobarbital
    - Rifampin
    - Vitamin K
    - Diuretics
- **Warfarin** affects vitamin K metabolism in the liver, limiting the production of factors II, VII, IX, and X and proteins C and S.
  - Intrinsic pathway: Prothrombin time (PT)/international normalized ratio (INR).
  - Inhibits vitamin K–dependent proteins from being carboxylated.
- **Heparin** enhances ability of antithrombin (AT-III) to inhibit factors IIa, IXa, and Xa.
  - Extrinsic pathway: Partial thromboplastin time (PTT).
- **Aspirin:** Half-life is 1 week.
  - Inhibits thromboxane A_2, synthesis by irreversibly binding COX in platelets and blocking platelet aggregation
- **Lovenox:** Complexes formed between AT-III and factors IIa and Xa.
- **Low-molecular-weight heparins** (**LMWHs**) inhibit factors Xa and IIa.
- **NSAIDs:** Anti-inflammatory action due to inhibiting COX.
- Three anticoagulation pathways:
  - Heparin → AT-III.
  - Protein C–thrombomodulin–protein S.
  - Tissue factor inhibitor.
- **Fibrinolytic system:** Plasminogen to plasmin.
- **von Willebrand factor** promotes platelet binding to vessel walls; carrier for factor VIII.
  - Treat deficiency with cryoprecipitate and desmopressin.
- **Hypercoagulable state**
  - Lower: Protein C, protein S, AT-III, plasminogen.
  - Higher: Lipoprotein A, homocysteine.
  - Present:
    - Activated protein C resistance (APCR).
    - Prothrombin G20210A mutation.
    - Lupus anticoagulant.
    - Hypofibrinolysis.
- **Virchow's triad:** Venous stasis, endothelial damage, hypercoagulability.

Biomechanics

- Free body analysis (must know these; practice them):
  - $M = F \times d$ (torque/moment)
  - $F = M \times A$
- Piezoelectric effect:
  - Concave compression side is electronegative.
  - Convex tension side is electropositive.
- Increase rigidity of external fixators:
  - Bone-to-bone contact (most important).
  - Larger-diameter pins.
  - Additional pins.
  - Decreased bone–rod distance.
  - Increased mass of the rods (or stack the rods).
  - Increased space between pins.
  - Circular fixators.
- **Young's modulus:**
  - Ceramic
  - Cobalt chrome
  - Stainless steel
  - Titanium
  - Cortical bone
  - Polymethylmethacrylate (PMMA)
  - Polyethylene
  - Cancellous bone
  - Tendon
  - Ligament
  - Cartilage
- **Modulus of elasticity:** Linear relationship between applied stress and resultant deformation.
- **Toughness:** Resistance to fracture.
- Torsional load in cylindrical bone: Max tensile load if generated at 45 *degrees* to the long axis.
- **Biomaterials:** Stress: Force/area (N/m^2). Strain: (change in length)/(original length) proportion.
- Young's modulus E = stress/strain.
  - Ceramic > cobalt chrome > stainless steel > titanium > cortical bone > PMMA > ultra-high-molecular-weight polyethylene (UHMWPE) > cancellous bone > tendon > ligament > skin > cartilage
- (1) **Elastic limit:** Point at which stain is no longer recoverable.
- (2) **Yield point:** Transition point from elastic to plastic deformation.
- (3) **Yield strength:** Amount of stress necessary to produce a specific amount of permanent deformation, usually 0.2%.
- (4) **Ultimate strength:** Maximum stress obtained to failure.
- (5) **Elastic (linear) region:** Proportional to stress applied.
- (6) **Plastic region:** Curve beyond yield point in which stress is not reversible (see Figure 1-2).
- **Ductile:** "Tough," large plastic curve.
- **Brittle:** "Hard," limited ability to deform before failure, small plastic curve.
- **Fatigue failure:** Number of cycles to material failure at a specific stress level.
- **Endurance limit:** Stress level at which a material can be cyclically loaded an infinite number of times without failing.
- Torsional bending strength not affected by < 10% of bone diameter. Strength decreases up to 50% if there is a hole that is 20% of the bone's diameter.

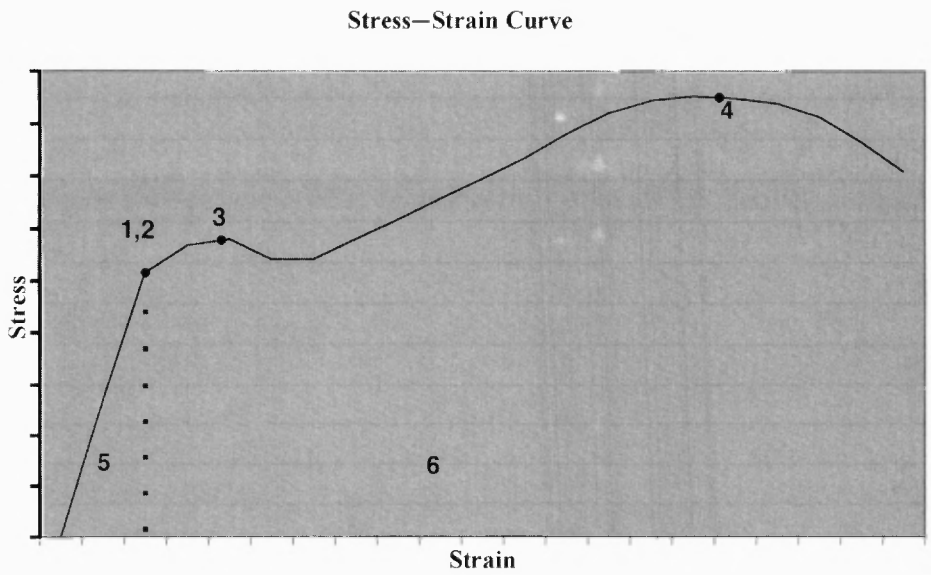

FIGURE 1-2. Stress–strain graph with references to definitions of elastic limit (1), yield point (2), yield strength (3), ultimate strength (4), elastic region (5), and plastic region (6).

- Resorbable polymers:
  - Polyglycolide (PGA): Gone by 3 months.
  - Polydioxanone (PDS): Gone by 6 months.
  - Poly-L-lactic acid (PLLA): Gone in years.
- Wear types:
  - **Adhesive:** Chemical; fragments from each surface adheres to each other.
  - **Abrasive:** Mechanical; material mismatch in which the soft surface creates debris.
  - **Fatigue:** Material; high local stress causes fracture.
  - **Third body:** Mechanical; wear debris or other particles (cement, metal, bone, etc).
- Gamma irradiation can increase the number of cross-links in UHMWPE, yet can decrease strength.
- Ceramics: Best wear resistance, high elastic modulus, high compressive strength, brittle.
  - High conductiveness due to high surface wettability and high surface tension.

NOTES

CHAPTER 2

Orthopaedic Anatomy

Shoulder 19

- Muscle Insertions 19
- Coracoacromial (CA) Ligament 19
- Sternoclavicular (SC) Joint 19
- Buford Complex 19
- Shoulder Stabilizers 19
- Arcuate Artery 20
- Axillary Artery 20
- Quadrangular Space 20
- Triangular Space 21
- Triangular Interval 21
- Distal Clavicle Osteolysis 21

Arm/Forearm 21

Elbow 21

Hand 22

- Deep Motor Branch of Ulnar Nerve 23
- Parona's Space 23
- Carpal Ossification Order 23
- Lumbrical Plus Hand 23

Spine 23

- Brachial Plexus 23
- Vertebral Artery 24
- Halo Pins 24
- Recurrent Laryngeal Nerve 24
- Artery of Adamkiewicz 24
- Common Lumbar Radiculopathies 25
- Incomplete Spinal Cord Injuries 25
- Complete Spinal Cord Injuries 26

Pelvis 26

- Hip Approaches 26
- Zones with Acetabular Screw Placement 27
- Femoral Triangle 27

Nontraumatic Avascular Necrosis (AVN) 27
Superficial Circumflex Iliac (SCI) Artery 27
Knee 27
Anterior Cruciate Ligament (ACL) 28
Posterior Cruciate Ligament (PCL) 28
Popliteus 28
Discoid Lateral Meniscus 28
Foot and Ankle 28
High Ankle Sprain 29
Plantar Fasciitis 29
Baxter's Nerve 29
Spring Ligament 29
Peroneus Longus 29
Peroneus Brevis 29
Anterior Talofibular Ligament (ATFL) Tears 30
Talus Blood Supply 30

- **Teres major:** Innervated by the lower subscapularis nerve.
- **Teres minor:** Innervated by the axillary nerve.
- **Pectoralis major:**
  - **Clavicular head** innervated by the lateral pectoral nerve
  - **Strenocostal head** innervated by the medial pectoral nerve
- **Humeral head** is 30 degrees retroverted vs. transepicondylar axis.
- **Glenoid** is 5 degrees retroverted.

Muscle Insertions

- **Humerus** from lateral to medial: **PLT**.
  - Pectoralis
  - Latissimus
  - Teres major
- **Coracoid** muscle attachments: Short head biceps, pectoralis minor, coracobrachialis.

Coracoacromial (CA) Ligament

- Acromial branch of the thoracoacromial artery runs within.
- Can be released during subacromial decompression.

Sternoclavicular (SC) Joint

- Posterior SC ligaments are the strongest.
- Posterior SC dislocation is associated with tracheal compression.

Be able to arthroscopically recognize the normal variants (Buford complex and sublabral foramen) and discern them from a pathologic labrum.

Buford Complex

- *Normal variant.*
- Thickened middle glenohumeral ligament (MGHL).
- Superior labral attachment of the MGHL just anterior to the biceps tendon with concomitant absence of anterosuperior labrum.
- If mistaken for labral detachment and the MGHL is repaired to the labrum, this inappropriate "repair" will cause loss of external rotation (ER).

Shoulder Stabilizers

- **Static stabilizers:** Articular anatomy, glenoid labrum, negative pressure, capsule, ligaments.
- **Dynamic stabilizers:** Rotator cuff, biceps tendon, scapulothoracic motion.
- **CA ligament:** Helps maintains superior joint stability.

Superior Glenohumeral Ligament (SGHL)

- Inferior restraint in adduction.

Middle Glenohumeral Ligament (MGHL)

- Anterior restraint in midrange (45 degrees) abduction.
- Secondary restraint to inferior translation in the adducted ER humerus.

Inferior Glenohumeral Ligament (IGHL)

- Prevents anterior inferior instability in abduction.
- **Anterior band:** Tight at 90 degrees abduction and ER.
- **Posterior band:** Tight at 90 degrees abduction and internal rotation (IR).
- SGHL and MGHL tighten with adduction and ER.
- **Rotator interval** prevents flexion and ER of the shoulder.
- Posterior shoulder arthroscopic portal enters below infraspinatus.
- If placed too **low,** *axillary nerve is at risk.*
- **Posterior approach** to the shoulder is between infraspinatus (suprascapular nerve) and teres minor (axillary nerve).

Arcuate Artery

- Terminal branch of the ascending branch of the *anterior humeral circumflex artery.*
- Supplies the humeral head and travels along the *lateral border of the bicipital groove.*
- It can be injured when plating a proximal humerus fracture.

Axillary Artery

Beware when plating proximal humerus fractures that the main blood supply to the humeral head lies in the lateral aspect of the bicipital groove.

- Begins at the lateral border of the first rib as a continuation of the subclavian artery.
- It changes its name to brachial artery at lower (inferior) border of the teres major.
- It is broken up into three parts by its relation to the pectoralis minor muscle (see Table 2-1).
- First part is between the lateral border of the first rib and the medial border of the pectoralis minor.
- Second part is behind the pectoralis minor.
- Third part is between the lateral border of the pectoralis minor and the inferior border of the teres major.
- *Thoracoacromial artery* runs within the CA ligament.
- Most tethered at origin of *anterior and posterior humeral circumflex* vessels.

Quadrangular Space

- *Axillary nerve* and *posterior humeral circumflex artery* pass through this space.
- **Borders:** Teres minor (superior), teres major (inferior), long head of triceps (medial), humeral shaft (lateral).

TABLE 2-1. Branches of the Axillary Artery Divisions

Axillary Artery			
First division	Supreme thoracic		
Second division	Thoracoacromial	Lateral thoracic	
Third division	Subscapular	Anterior humeral circumflex	Posterior humeral circumflex

Triangular Space

- *Circumflex scapular artery* passes through this space.
- **Borders:** Teres minor (superior), teres major (inferior), long head of triceps (lateral).

Triangular Interval

- *Radial nerve* and *profunda brachii* artery run through this interval.
- **Borders:** Teres major (superior), long head of triceps (medial), lateral head of triceps (lateral).

Distal Clavicle Osteolysis

- Repetitive trauma (weight lifting).
- Rheumatoid arthritis.
- Hyperparathyroidism.
- Tumor.
- Cleidocranial dysplasia.
- Pyknodysostosis.

▶ ARM/FOREARM

- **Musculocutaneous nerve** continues distally between biceps and brachioradialis (BR) as the *lateral antebrachial cutaneous nerve.*
- **Radial nerve** traverses the spiral groove ~13 cm up from elbow joint, pierces septum ~7 cm from epicondyle between brachialis and BR.
- **Posterior approach** to humeral shaft splits the *medial* head of the triceps.
- **Triceps** originates from humerus and scapula.
- **Median nerve** runs between basilic vein and brachial artery. In median nerve injury, the *last* muscle to recover is the *pronator quadratus.*
- **Pacinian corpuscles** sense *pressure.*
- **Ligament of Struthers:**
  - **Supracondylar process** points toward elbow joint.
  - Ligament attaches to medial epicondyle.
  - Can cause *median nerve entrapment.*

▶ ELBOW

- **Medial antebrachial cutaneous nerve** runs with basilic vein, can be injured in elbow scopes.
- **Joints with intra-articular metaphysis:** Hip, shoulder, elbow (radial head), and ankle (distal fibula).
- **Normal carrying angle** of elbow is 7 *degrees* valgus tilt.
- **Cephalic vein** runs with lateral antebrachial cutaneous nerve (laterally).
- **Kocher approach to elbow:** Between extensor carpi ulnaris (ECU) (posterior interosseous nerve [PIN]) and anconeus (radial); pronate and flex elbow to protect PIN during approach.
- **Henry approach (volar):** Between pronator teres and BR; supinate to protect PIN.
- **Thomspson approach (dorsal):** Between extensor carpi radialis brevis (ECRB, radial nerve) and extensor digitorum communis (EDC, PIN).

- C2–3: Level of mandible.
- C3: Level with hyoid.
- C4/5: Level with thyroid.
- C6: Cricoid and carotid tubercle.
- C5–6: Most common disk herniation in cervical spine, most commonly gets C6 root.
- **Neck flexion:** 50% at occiput–C1.
- **Neck rotation:** 50% at C1–2.
- **Denervation:** Electromyographic (EMG) findings; fibrillations and sharp waves.
- **Dermatomes:** T4, nipples; T7, xiphoid; T10, umbilicus.
- **Longus colli** is *anterior* to vertebral artery.
- **Cervical ganglion** is *anterior* to longus capitus.
- **Longus capitus** is *anterior* to longus colli.
- **Deepest to anterior:** Vertebral artery, longus colli, longus capitis, cervical ganglion.
- **Carotid sheath:** Internal carotid artery, common carotid artery, internal jugular vein, vagus nerve (CN X).
- **Neurapraxia:** Order of motor and sensory loss.
- Motor > proprioception > touch > temperature > pain.
- Regain first to last (**APP MMST**):
  - **A**nesthesia > **P**ressure (proprioception) > **P**ain (protective) > **M**oving touch > **M**oving two-point (Meissner's) > **S**tatic **T**wo-point (Merkel's).

With nerve injury, the most sensitive test is the threshold (monofilament and vibration) test, and it is the last to come back with nerve recovery.

Vertebral Artery

- Branch of subclavian.
- Runs through C6 to C1 (*not* C7).
- Posterior to longus colli.
- After exiting C1, travels *medially* on the superior posterior arch of C1 (cephalad) and up through the foramen magnum.
- **Greater occipital nerve:** Exits spine at C1–2 (from medial branch of dorsal ramus C2), pierces semispinalis and trapezius.
- **Cruciform ligament:** Main stability for occiput–C2.

When dissecting near C1, stay within 15 mm of midline to avoid injuring the vertebral artery.

Halo Pins

- Anterior pins need to be at least 4.5 cm lateral from midline.
- Below equator, above supraorbital ridge.
- Risks injury to supraorbital nerve, supratrochlear nerve, frontal sinus (from lateral to medial).

Recurrent Laryngeal Nerve

- Unpredictable course on the *right* side.
- On left side lies between trachea and esophagus.

When anteriorly exposing the lower lumbar spine, be cautious of the superior hypogastric plexus that overlies L5. Injury to this plexus can cause retrograde ejaculation.

Artery of Adamkiewicz

- T8–L1.
- 80% on left.
- Arteria radicularis magna.
- Arterial injury can cause anterior spinal syndrome.

TABLE 2-2. Common Lumbar Radiculopathies

Level	Motor Weakness	Sensory Involvement	Reflex Affected
L4	Tibialis anterior	Medial leg and foot	Patellar tendon
L5	EDL and medial hamstring (SM and ST)	Middle dorsum of foot	None
S1	Peroneals, FHL, gastrocs, lateral hamstring, and gluteus maximus	Lateral foot	Achilles tendon

EDL = extensor digitorum longus; FHL = flexor hallucis longus; SM = semimembranosus; ST = semitendinosis.

Common Lumbar Radiculopathies

The signs and symptoms of lumbar radiculopathies are outlined in Table 2-2.

- **Isthmic spondylolisthesis L5–S1** gets L5 radiculopathy.
- **Herniated nucleus pulposus (HNP) L5–S1** gets S1 radiculopathy (unless far lateral, then L5).
- **Degenerative spondylolisthesis** is most common at L4–5 (get L5 root symptoms).
- **L5 radiculopathy** is due to compression between hypertrophic and subluxed inferior facet of L4 and posterosuperior L5 body.

Incomplete Spinal Cord Injuries

Central Cord Syndrome

- Most common.
- Upper extremity (UE) weakness > lower extremity (LE).
- Flaccid UE and spastic LE.
- Intact bladder control.
- ~75% recovery.

Posterior Cord Syndrome

- Rare.
- Loss of deep pressure, deep pain, and proprioception.
- Ambulate with slapping gait (tabes dorsalis).

Anterior Cord Syndrome

- Worst prognosis.
- Complete motor and sensory loss except retain trunk and LE pressure/proprioception.
- ~10% functional recovery.

Brown-Séquard Syndrome

- Best recovery.
- Unilateral cord injury.
- Motor deficit on ipsilateral side.
- Contralateral pain and temperature loss two levels below injury.

- Most regain bowel/bladder function and can ambulate.
- > 90% functional recovery.

Complete Spinal Cord Injuries

- May have root return of one level in 80% and two levels in 20%.

▶ PELVIS

- **Peroneal division** of sciatic nerve is more **lateral**.
- Hip pathology can have pain referred to the knee due to continuation of a branch of the *obturator nerve* (to adductor magnus).
- Sacroiliac (SI) screws: If placed too anterior, potential for *L5* nerve root injury.
- **Femoral nerve**: First branch goes to sartorius; last branch goes to articularis genu (see Table 2-3).
- **Internal iliac artery** becomes the obturator artery.
- Vessels to the femoral head: Lateral femoral circumflex is on the anterior neck; medial femoral circumflex is on the posterior neck.
- **Ascending branch of lateral circumflex femoral artery:** Encountered in anterior approach to the hip (ligate).
- **Medial femoral circumflex artery** is between adductor magnus and brevis medially.
- **Deep external pudendal artery** is at risk when doing a percutaneous tenotomy of the adductor longus.
- **Peroneal branch of sciatic nerve** runs on the deep surface of long head biceps.

*For vessels to the femoral head: **LAMP** (**L**ateral femoral circumflex is **A**nterior; **M**edial femoral circumflex is **P**osterior)*

Hip Approaches

- **Anterior approach** (Smith-Peterson): Interval is between sartorius (femoral nerve) and tensor fascia lata (superior gluteal nerve). True internervous plane. Good for primary total hip arthroplasty (THA) (esp. "mini"), anterior column plating. Lateral femoral cutaneous nerve at risk. Poor visualization of posterior acetabulum.
- **Anterolateral approach** (Watson-Jones): Tensor fascia lata (superior gluteal nerve) and gluteus medius (superior gluteal nerve). Primary THA. Risk of damage to tensor fascia lata innervation.

TABLE 2-3. Nerve, Level, and Muscle of the Femoral, Obturator, and Sciatic Nerves

Nerve	Level	Muscle
Femoral	L2–4	Iliacus, psoas, sartorius, pectineus, quads, articularis genu
Obturator	L2–4	Obturator externus, hip adductors, gracilis
Sciatic	L4–S3	*Peroneal division:* Short head of biceps *Tibial division:* Semitendinosus, semimembranosus, part of adductor magnus, long head biceps

TABLE 2-4. Femoral Head Blood Supply

Birth to age 4	Primarily medial and lateral circumflex arteries, and ligamentum
Age 4 to adult	Primarily medial circumflex, minimal from lateral and ligamentum

- **Medial approach** (Ludloff): Adductor brevis (obturator nerve) and adductor magnus (obturator and sciatic).
- **Direct lateral approach** (Hardinge): Via tensor fascia lata and gluteus medius. Can damage femoral nerve (retractor placement) and superior gluteal nerve (4 cm proximal to greater trochanter). THA. Reduced dislocations in THA compared to posterior approach. Patients can limp. Posterior column plating not possible.
- **Posterior approach**: Via gluteus maximus, but innervation is medial to the split so denervation unlikely. THA. Can be extended for posterior column and wall. Higher dislocation risk with THA.

Zones with Acetabular Screw Placement

- **Posterior superior acetabular quadrant** (safest zone): Risk injury to sciatic nerve, superior gluteal vessels at risk.
- **Posterior inferior acetabular quadrant:** Risk injury to sciatic nerve, inferior gluteal vessels and nerve, internal pudendal vessels and nerve. **Anterior inferior acetabular quadrant:** Risk injury to obturator nerve, artery, and vein.
- **Anterior superior acetabular quadrant:** *External iliac vessels.*

When placing screws in an acetabular cup, the posterior superior quadrant is the safest zone.

Femoral Triangle

- **Floor (lateral to medial):** Iliacus, psoas, pectineus, adductor longus.
- **Femoral canal:** Iliacus, femoral nerve, femoral artery, femoral vein, pectineus.

Nontraumatic Avascular Necrosis (AVN)

- Typically affects the anterolateral portion of femoral head.
- The contribution of the lateral circumflex femoral artery and ligamentum decreases after ~ age 4 (see Table 2-4).

Superficial Circumflex Iliac (SCI) Artery

- Landmark for lateral femoral cutaneous nerve (in anterior approach to hip).
- Used for groin flap.

Order of Nerves that Pass Below the Piriformis–

POPS IQ

- **P**udendal nerve.
- Nerve to **O**bturator internus.
- **P**osterior femoral cutaneous nerve.
- **S**ciatic (2% through piriformis).
- **I**nferior gluteal nerve.
- Nerve to **Q**uadratus femoris.

► KNEE

- **Medial knee:** three layers (superficial to deep):
  - I: sartorius, sartorial fascia.
  - II: superficial MCL, posterior oblique ligament (POL), semimembranosus.
  - III: deep MCL, capsule.

- **Lateral knee:** three layers (less consistent):
  - I: lateral fascia, IT band, biceps tendon.
  - II: patellar retinacullum, patellofemoral ligament.
  - III: capsule, lateral collateral ligament (LCL), arcuate ligament, fabellofibular ligament.
- **Popliteal artery** is typically behind the posterior horn lateral meniscus.
- **Lateral inferior geniculate artery** runs between LCL and popliteus.
- **Fabella:** Located in *lateral* gastrocnemius (18% of patients).
- **Meniscal repair:**
  - Medially, saphenous nerve is at risk.
  - Laterally, peroneal nerve is at risk.
- **Chondrocalcinosis:** Calcium-containing crystals in cartilage/meniscus.
- **Menisci:** Majority of large collagen fibers are *circumferential*; hoop stress with compressive loading.

Anterior Cruciate Ligament (ACL)

- **Anteromedial bundle:** Tight in flexion.
- **Posterolateral bundle:** Tight in extension.
- **Classic bone bruise pattern:** Mid third of lateral femoral condyle and posterior third of lateral tibial plateau.
- **Lateral meniscus** is most common site of acute meniscal tear with ACL injury.
- Chronic bone scan in an ACL-deficient knee shows increased uptake in medial > lateral > patellofemoral compartment.
- **Segond fracture** is associated with an ACL tear; lateral capsular avulsion that can be seen on plain films.

The key structures in the posterior lateral corner are the popliteus, LCL, and popliteal fibular ligament.

Posterior Cruciate Ligament (PCL)

- **Middle geniculate artery:** Main blood supply to PCL and ACL.
- **Anterolateral bundle:** Tight in flexion.
- **Posteromedial bundle:** Tight in extension.
- **Ligament of Humphrey** (anterior to PCL), **Wrisberg** (posterior to PCL).
- On magnetic resonance imaging (MRI), "double PCL sign" indicates posterior horn medial meniscus tear displaced into notch.

Popliteus

- Intra-articular.
- Runs from the posterior tibia to lateral femoral condyle anterior to LCL.
- Can be visualized during arthroscopy.

Discoid Lateral Meniscus

- Patient may *lack full knee extension.*
- ~3% population.
- Diagnosed by ≥3 sagittal slices with complete bowtie appearance of meniscus.

▶ FOOT AND ANKLE

- **Anterior talofibular ligament (ATFL)** is an intra-articular thickening.
- **Heel spurs** originate in the flexor digitorum brevis (FDB).
- **Ankle scope:** Anterior lateral portal: Risk to superficial peroneal nerve.

High Ankle Sprain

- ER mechanism.
- Injury to the tibiofibular ligament, interosseous ligament.
- Chronic ankle sprain of anterior inferior tibiofibular ligament (Bassett's ligament):
- Get thickening and synovitis.
- If needed, treat with arthroscopic debridement.

Plantar Fasciitis

- First branch of lateral calcaneal nerve.
- Trapped between *abductor hallucis* and *quadratus plantae*.
- Innervates *abductor digiti minimi*.

Baxter's Nerve

- Lateral plantar nerve.
- Heel pain.

Spring Ligament

- Coronoid cavity of calcaneus to inferior (plantar) surface of navicular.
- Anterior to the sustentaculum tali.
- Also known as *calcaneal-navicular ligament*.

Peroneus Longus

- Paralysis or laceration; can cause a dorsal bunion.
- Plantar flexes the first ray.

Peroneus Brevis

- Common to get split longitudinal tears at the fibular groove (see Figure 2-1).

FIGURE 2-1. Peroneal tendons. Operative photo of the **(A)** peroneus brevis and **(B)** longus just proximal to the fibular groove.

Anterior Talofibular Ligament (ATFL) Tears

- Ankle instability.
- Treatment:
  - Modified Brostrom:
    - Repair ATFL using local tissue.
    - Reinforce with extensor retinaculum.
  - Chrisman-Snook: Uses half of the peroneus brevis to reconstruct ATFL
  - Watson-Jones and Evans: Uses all of the peroneus brevis to reconstruct ATFL

Talus Blood Supply

- Main supply is the artery of the tarsal canal (medial), a branch of the posterior tibial artery.
- Artery of sinus tarsi (lateral), a branch of the dorsalis pedis artery.
- Deltoid branch, a branch of the artery to the tarsal canal; runs in the deltoid substance.

CHAPTER 3

Orthopaedic Trauma

General Trauma 34

ABCs 34

Adequate Resuscitation 34

Fluid Resuscitation 34

Base Deficit 35

Trauma X-ray Series 35

Open Fractures 35

Fat Emboli Syndrome 35

Tension Pneumothorax 35

Compartment Syndrome 36

Mangled Extremity Severity Score (MESS) 36

Spinal Cord/Plexus Injuries 36

Nasotracheal Intubation 36

Cricothyrotomy 36

Neurologic Level 36

Steroid Protocol 36

Incomplete Cord Syndromes 36

Incomplete Spinal Cord Injury 37

Cervical Trauma 37

C1–2 Instability 37

C2 (Axis) Hangman's Fracture 37

Odontoid Fracture, Type II 37

Odontoid Fracture, Type III 38

Unilateral C-Spine Facet Fracture 38

Bilateral C-spine Facet Subluxation/Dislocation 39

Ipsilateral C-Spine Lamina and Pedicle Fracture (Floating Facet) 39

Ankylosing Spondylitis 39

Flexion–Distraction Injury 39

Burst Fracture 40

Brachial Plexus Injuries 40

Upper Extremity Trauma 40

Sternoclavicular (SC) Joint Dislocation 40

Clavicle Fractures 41

Acromioclavicular (AC) Injuries 41
Scapula Fracture 41
Floating Shoulder 41
Scapulothoracic Dissociation 41
Glenohumeral Dislocations 42
Little Leaguer's Shoulder 43
Proximal Humerus Fracture 43
Humeral Shaft Fracture 44
Distal Humerus Fracture 45
Pediatric Supracondylar Humerus Fracture 45
Pediatric Medial Epicondyle Fracture 45
Pediatric Lateral Condyle Fracture 45
Olecranon Fracture 46
Pediatric Olecranon Fracture, Flexion Type 46
Coronoid Fracture 46
Radial Head Fracture 46
Elbow Dislocation 46
Radius/Ulna Fracture 47
Radius Approaches 47
Pediatric Both-Bone Forearm Fracture 47
Galeazzi Fracture 47
Monteggia Fracture 48
Pin Injury 48
Distal Radius Fracture 48
Ulnar Styloid Fracture 49
Ulnar Impaction Syndrome 49

Pelvis and Lower Extremity Trauma 49
Pelvic Ring Injuries 49
Sacral Fracture 50
Acetabular Fracture 51
Hip Dislocation 52
Femoral Head Fracture 53
Femoral Neck Fracture 53
Femoral Neck Stress Fracture 54
Intertrochanteric Hip Fracture 54
Subtrochanteric Hip Fracture 55
Femoral Shaft Fracture 56
Pediatric Femur Fracture 58
Distal Femur Fractures 58
Knee Dislocation 59
Patella Fracture 60
Patella Dislocation 61
Patella Tendon (Ligament) Rupture 61
Quadricep Tenoon Rupture 61
Tibial Plateau Fracture 61
Tibial Shaft Fracture 62
Tibial Plafond (Pilon) 64

Ankle Fracture 65
Syndesmotic Disruption 66
Open Ankle Fracture 66
Achilles Tendon Rupture 66
Os Peroneum 67
Acute Peroneal Tendon Dislocation 67
Talar Neck Fractures 67
Talar Process Fracture 68
Subtalar Dislocation 68
Calcaneus Fracture 68
Navicular Fracture 69
Cuboid Fracture 69
Lisfranc Fracture–Dislocation 70
Metatarsal Fracture 70
MTP Joint Dislocation 71
"Turf Toe" 71
Phalangeal Fracture 71
Compartment Syndrome of the Foot 71

ABCs

- Airway
- Breathing
- Circulation
- Disability
- Evaluation (neurologic status), Exposure, and Environment control

Adequate Resuscitation

- Mean arterial pressure (MAP) > 60 mm Hg.
- Heart rate (HR) < 100 beats/min.
- Urine output (UOP) > 0.5–1.0 mg/kg/h.
- Best predictor of perioperative complications: Lactate levels > 2.5 mmol/L.
- Interleukin-6 (IL-6) is associated with systemic inflammatory response to trauma. Definitive surgery should be delayed when IL-6 is elevated to avoid multiple organ dysfunction syndrome (MDOS).

Fluid Resuscitation

- Crystalloid isotonic solutions can be used to correct most extracellular volume deficits.
- Administered rapidly at 3–4 times the volume of estimated blood loss (EBL).
- Give blood to those who fail initial fluid boluses.
- The most common cause of shock is acute blood loss (see Table 3-1).
- The most common cause of blood transfusion reaction: Clerical error.

TABLE 3-1. Hemorrhagic Shock

Class	Blood Loss	BP	HR	pH	Resp	UOP	CNS
I	< 15% (< 750 cm^3)	Nl	Nl	Nl	Nl	> 30 cm^3	Anxious
II	15%–25% (750–1500 cm^3)	Nl	↑	Nl	↑	20–30 cm^3	Irritable, confused, combative
III	25%–40% (1500–2000 cm^3)	↓	↑	↓	↑	5–15 cm^3	Irritable, lethargic
IV	> 40% (> 2000 cm^3)	↓	↑	↓	↑	< 5 cm^3	Lethargic, coma

BP, blood pressure; CNS, central nervous system; HR, heart rate; Nl, normal; UOP, urine output.

Base Deficit

- Best measure of adequate resuscitation in first 6 hours after injury.
- A direct measure of metabolic acidosis and an indirect measure of blood lactate levels.
- Correlates with organ dysfunction, mortality, and adequacy of resuscitation.

The best test to measure resuscitation in the first 6 hours after injury is base deficit.

Trauma X-ray Series

- Anteroposterior (AP) chest (mediastinal widening, pneumothorax).
- Lateral C-spine (must visualize C7–T1 junction).
- AP pelvis.

Open Fractures

- Need emergent irrigation and debridement (I&D).
- Appropriate antibiotics based on grade (see Table 3-2) and stabilization.

Fat Emboli Syndrome

- Anxiety, confusion, tachycardia, and hypoxemia; usually occurs within 48 hours of injury.
- Hypoxia ($PaO_2 < 60$ mm Hg), petechial rash.
- Treatment: Preventive and supportive.
- Surgical stabilization of fractures is beneficial.

Tension Pneumothorax

- Tachycardia, hypotension, chest with tympany to percussion, distended neck veins, and deviation of the trachea away from the affected side.
- Treatment: Urgent needle decompression, typically between second and fourth intercostal space (midclavicular line), followed by definitive chest tube placement.

TABLE 3-2. Gustillo Open Fracture Classification

Grade	Soft Tissue Wound	Antibiotics
I	< 1 cm	First-generation cephalosporin
II	1–10 cm	First-generation cephalosporin
III	> 10 cm	First-generation cephalosporin, gentamicin; add penicillin if gross contamination (e.g., farm, bowel)
A	Adequate tissue for closure	
B	Needs soft tissue coverage	
C	Vascular injury requiring repair	

The most critical clinical sign of compartment syndrome is pain out of proportion.

Compartment Syndrome

- Have a high index of suspicion.
- 5 Ps: Pain out of proportion (critical clinical sign), pain with Passive stretch (critical clinical test), Paresthesias, Pallor, and Pulselessness.
- MAP–compartment pressures < 30 mm Hg critical value to decompress.
- 4 Cs of viability: Color, Contractility, Capacity to bleed, Consistency.

Mangled Extremity Severity Score (MESS)

- Used to predict necessity of amputation after lower extremity trauma.
- Points are assigned for skeletal/soft tissue injury (1–4), ischemia time (1–6), age of the patient (0–2), and shock defined by hypotension (0–2).
- MESS score > 7 indicates need for amputation.

▶ SPINAL CORD/PLEXUS INJURIES

Nasotracheal Intubation

- Treatment of choice in the nonapneic patient with suspected cervical injury with no maxillofacial trauma.

Cricothyrotomy

- Preferred approach in adults with facial trauma and possible neck injury.

Neurologic Level

- Most caudal level with normal motor and sensory function; at least 4/5 motor.

Steroid Protocol

- Methylprednisolone protocol: Initiate within 8 hours.
- Load 30 mg/kg, then 5.4 mg/kg/h for 23 hours if < 3 hours, continue for 48 hours if 3–8 hours.
- Steroids are not indicated for nerve root deficits, brachial plexus deficits, or gunshot wounds (GSWs).

Incomplete Cord Syndromes

- **Central cord:** Most common, motor loss upper extremity (UE) > LE, sacral sparing, rare full recovery.
- **Brown-Séquard:** Cord hemitransection; good recovery.
  - Ipsilateral loss motor and proprioception.
  - Contralateral loss pain and temperature (two levels lower because these travel up two levels and then cross).
- **Anterior cord:** Mechanism flexion–compression; poor prognosis.
- **Posterior cord:** Lose proprioception; keep motor, pain, and light touch; rare.

Incomplete Spinal Cord Injury

- Best chance for recovery occurs when the canal is cleared and the neural structures are decompressed.
- Anterior decompression, vertebral body reconstruction, and anterior stabilization have been shown to be highly effective in the treatment of burst-type fractures.
- Laminectomy alone is contraindicated because of instability.

A key finding in central cord syndrome is motor weakness that is greater in the upper extremities than the lower.

Cervical Trauma

- Over two-thirds of significant pathology is detected on the lateral view.
- If the C7–T1 junction is not revealed on radiographs, then a computed tomography (CT) scan with lateral reconstructions should be used to visualize that portion of the spine (10%–15% C-spine injuries at this level).
- Obtain magnetic resonance imaging (MRI) scans in patients who have a neurologic finding that cannot be explained by bony or ligamentous instability on plain radiographs and dynamic views.
- While dynamic radiographs are contraindicated in the patient with acute neurologic deficits, they should be obtained in patients who have unexplained neck pain but are neurologically intact.
- To rule out subacute instabilities that may not have been seen initially, these studies need to be repeated 2–3 weeks after the injury and after cervical spasm has resolved.

C1–2 Instability

- Secondary to rupture of the transverse ligament.
- Unstable on flexion–extension views.
- Atlantodens interval (ADI) > 5 mm (normal: adult, ≤ 3 mm; child, ≤ 5 mm); posterior ADI < 13 mm.
- **Treatment**: Posterior spinal fusion.
- 50% rotation is from C1–2.
- 50% flexion–extension is occiput–C1.

C2 (Axis) Hangman's Fracture

- Traumatic spondylolisthesis.
- **Type I** (< 3 mm displacement): Cervical collar (4–6 weeks).
- **Type II** (> 3 mm displacement): Halo, rare neurologic injury (Figure 3-1).
- **Type IIA**: Angulated, extension, no traction, halo.
- **Type III** (bilateral facet dislocation, C2 on C3): Reduction and surgical fixation.

Odontoid Fracture, Type II

- If initial fracture displacement is > 5 mm, angulation > 10 degrees, or > 50 years old, problems with nonunion and malunion are more frequent when treated conservatively.
- Surgical treatment is with anterior screw or posterior C1–2 fusion.

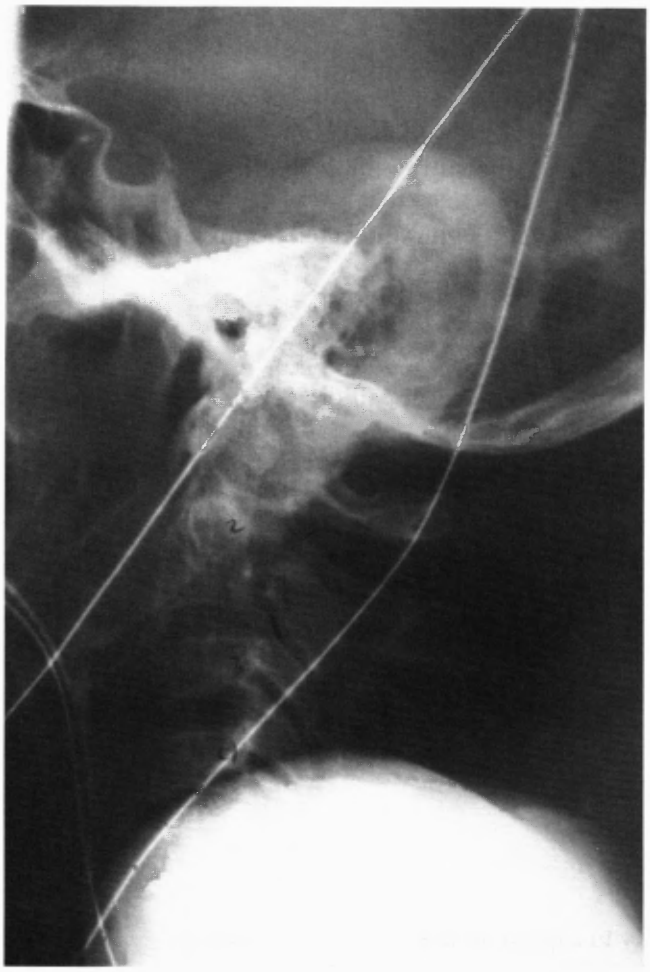

FIGURE 3-1. Type II Hangman's fracture. Treat with halo immobilization. Also, this film is inadequate, as the C7–T1 junction is not visualized and additional spine injuries could be missed.

Consider operative management of a type II odontoid fracture if initial displacement is > 5 mm, angulation > 10 degrees, or patient > 50 years old.

Odontoid Fracture, Type III

- This type of fracture has a high union rate following reduction and immobilization (see Figure 3-2).
- Anterior screw fixation is contraindicated in type III fractures.
- Treat with halo.
- **Odontoid nonunion:** If unstable on flexion–extension x-rays, stabilize and fuse.

Unilateral C-Spine Facet Fracture

- Stable bony fracture.
- Treat with rigid collar for 6 weeks.
- Flexion–extension x-rays may be obtained at 6 weeks to verify there is no instability.

FIGURE 3-2. **Type III odontoid fracture.** A high rate of fracture union occurs with halo immobilization.

Bilateral C-Spine Facet Subluxation/Dislocation

- Skeletal traction and attempt closed reduction if patient is alert and cooperative.
- This should not be attempted in a patient who is obtunded, comatose, or uncooperative.
- If any neurological changes are noted during reduction, attempt should be stopped, appropriate radiographic studies obtained (including MRI to evaluate disk), and open reduction and stabilization planned in the operating room.

Ipsilateral C-Spine Lamina and Pedicle Fracture (Floating Facet)

- Extremely unstable pattern (involves two motion segments).
- Treat with lateral mass plates (provides rotational control).
- Halo does not support the subaxial spine well.

Ankylosing Spondylitis

- Rigid spines are susceptible to fracture.
- A high index of suspicion should exist for occult fracture; consider CT scan.
- Late neurologic deficit likely secondary to hematoma (epidural).

Flexion–Distraction Injury

- Closely evaluate for **intra-abdominal** visceral injury (especially gastrointestinal); initial evaluation should include abdominal CT.
- Common with lap belt restraints in motor vehicle accidents.

With a flexion–distraction injury (Chance fracture) of the spine, you must rule out intra-abdominal injury.

- X-rays will most likely reveal an increased interspinous distance and a break in continuity of the pedicle's cortical margins—**empty facet sign**.
- A variety of structural defects may be produced, including pure bone defect (Chance fractures) or bone, ligament, and disk combinations extending over several vertebral segments.
- Pediatric bony chance fractures are treated with hyperextension casting and TLSO. Bedrest is not necessary. Surgery is required for significant ligamentous injury or progressive kyphosis (> 25 degrees).

Burst Fracture

Surgical indications:

- > 50% loss of height.
- > 30% kyphosis.
- > 50% canal compromise.
- Retained fragments will resorb and do not cause neurologic deterioration.
- If surgery is needed, anterior decompression with strut graft +/– posterior fusion is required. Laminectomy will further destabilize the spine.

▶ BRACHIAL PLEXUS INJURIES

- **Postganglionic:** Preservation of cervical paraspinals and no Horner syndrome, motor and sensory out on electromyography (EMG), nerve conduction velocity (NCV).
- **Preganglionic:** Horner syndrome present due to disruption of sympathetics; cell bodies intact, thus motor *out* and sensory still *in* on EMG/NCV; triple flare reaction remains intact.
- Most managed closed; exploration based on clinical and electrical recovery.
- Primary exploration for penetrating trauma (not GSW), open injuries, progressive neurologic deficit, expanding hematoma, vascular injury.
- Reconstruction priorities: Elbow flexion > shoulder abduction > hand sensibility > wrist extension > finger flexion > wrist flexion > finger extension > intrinsic function.
- **Reconstructive options:** Nerve repair, nerve graft, neurotization, free muscle transfer.

▶ UPPER EXTREMITY TRAUMA

Sternoclavicular (SC) Joint Dislocation

- **X-ray:**
  - Serendipity view (40-degree cephalic tilt).
  - CT (study of choice).
- **Anterior dislocation:**
  - Reduce under general anesthesia with abduction, extension, and direct pressure.
  - Unstable reduction: Accept deformity (preferable) vs. resect medial clavicle.
- **Posterior dislocation:**
  - May present with stridor, tachypnea, dysphagia.

- Reduce under general anesthesia with abduction, extension, towel clip on medial clavicle; have thoracic surgery available.
- Unstable reduction: Excision of medial clavicle (preferable) vs. surgical stabilization.

- **Medial clavicle resection:** Do not resect more than 1.5 cm, avoid costoclavicular ligaments.
- **Medial clavicle physeal fractures:** < 25 years old, Salter-Harris I or II, nonoperative unless symptomatic; will remodel.

Clavicle Fractures

- **Primary treatment:** Sling for 6 weeks.
- **Indications for surgical intervention** (indications expanding): Open fractures, significantly displaced fractures (tenting skin), vascular injury, lateral third with unstable medial fragment.
- For atrophic nonunion: Open reduction and internal fixation (ORIF).
- Options include: 3.5-mm AO plate, modified Hagie intramedullary (IM) fixation.

Acromioclavicular (AC) Injuries

- Primary treatment: Sling for ~3 weeks.
- Nonoperative treatment for types I, II, and III (some advocate operating on type III).
- **Indications for surgical intervention:**
  - Superior displacement of clavicle > 100% (**type V**).
  - Posterior displacement through trapezius (**type IV**).
  - Inferior lateral displacement under coracoid (**type VI**).

Scapula Fracture

- High-energy trauma with 80%–90% associated injury; thoracic rib fractures most common, pulmonary contusions.
- Treat most with sling for 3–6 weeks.
- **Indications for surgical intervention:**
  - Involvement of > 25% glenoid with humeral subluxation (Figure 3-3).
  - Intra-articular stepoff > 5 mm or major gap.
  - > 40 degrees angulation or 1-cm translation of neck fracture, excessive medialization of glenoid.

Floating Shoulder

- If unstable, will need ORIF (usually of just the clavicle).
- Nonsurgical management of the majority of combined injuries in patients with <10 mm of displacement and stable has resulted in excellent shoulder function.

Scapulothoracic Dissociation

- Closed traumatic forequarter amputation.
- Chest x-ray: Nonrotated shows scapula edge laterally displaced > 1 cm from contralateral side (measure from spinous processes).
- Vascular injury common: *Subclavian most common.*

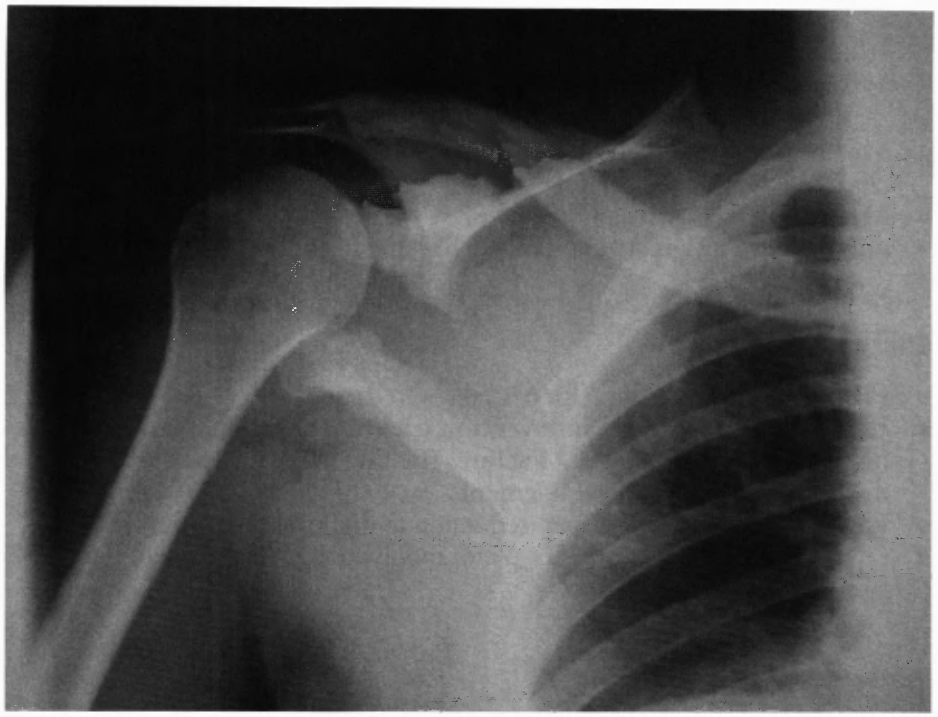

FIGURE 3-3. Fracture through the glenoid and into the scapula. The significant glenoid involvement and articular stepoff require ORIF.

- Arteriogram and, if needed, immediate repair.
- Brachial plexus injury common; complete deficit has poor outcome, partial has guarded outlook.
- Must stabilize the dissociation: ORIF clavicle and AC joint.

Glenohumeral Dislocations

- Radiographic evaluation: AP/scapular/*axillary*.
- Westpoint view: Help evaluate anterior glenoid margin (bony Bankart).
- Stryker notch view: Help evaluate Hill-Sachs defect of humeral head.
- **Anterior dislocation:**
  - If > 40 years old, high incidence of rotator cuff tears.
  - If < 20 years old, high recurrence rate (instability).
  - Surgical treatment: Labral repair, > 95% success.
  - **TUBS**: Traumatic Unilateral Bankart Surgery.
- **Inferior dislocation—"luxatio erecta":**
  - Greater incidence of neurovascular injury (axillary nerve and artery).
  - May resolve after reduction.
  - Be aware of late thrombosis.
  - Reduce and immobilize for a short period of time.
- **Posterior dislocation:**
  - Rare compromising < 5%.
  - Often associated with lesser tuberosity fracture.
  - Clinically unable to externally rotate the shoulder.
  - Must be ruled out by complete radiographic series (including axillary and scapular Y).

- Common following seizures and electrical shocks (stronger internal rotation [IR] vs. the weaker external rotation [ER]).
- 50% have associated impaction fracture between articular margin and lesser tuberosity.
- If impaction < 20%: Closed reduction in extension and ER.
- If 20%–40% defect: Transpose lesser tuberosity with subscapularis into defect (Neer modification).
- If > 40%–50% defect: Consider hemiarthroplasty.

Must obtain an axillary lateral to evaluate location of dislocation or rule out posterior dislocation.

Little Leaguer's Shoulder

- Rotational stress fracture of proximal humeral physis.
- Widening of physis (compare with opposite side).
- Treat with cessation of throwing activities with rehab of shoulder girdle muscles and evaluate pitching technique.

If proximal physeal stress injury (Little Leaguer's shoulder) is suspected, obtain x-rays of contralateral proximal humerus to compare width of growth plates.

Proximal Humerus Fracture (Figure 3-4)

- Anterolateral branch of the anterior humeral circumflex artery is the main blood supply to humeral head; runs in intertubercular groove.
- 45% incidence of nerve injury (axillary most common).
- Two-part:
  - **Surgical neck:** Sling unless > 45-degree angulation; anterior and varus poorly tolerated.
  - **Greater tuberosity:** Sling if < 5-mm displacement, ORIF if greater.
  - **Lesser tuberosity:** Usually with posterior dislocation, ORIF if large fragment, excision with cuff repair if small.
  - **Anatomic neck:** Rare; ORIF in young, ORIF in elderly vs. acute hemiarthroplasty.
- **Three-part:** ORIF for young patient, hemiarthroplasty for elderly.
- **Four-part:** ORIF for young patient, hemiarthroplasty for elderly.

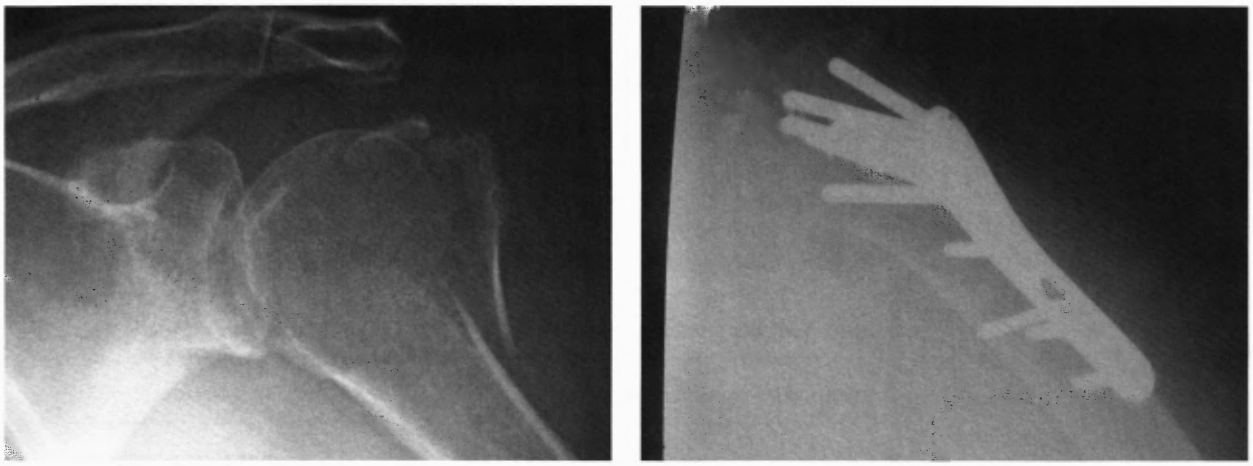

A B

FIGURE 3-4. A three-part proximal humerus fracture in a young patient. The treatment is ORIF.

- **Four-part (valgus impacted):**
  - Good results with ORIF.
  - Posteromedial component intact, preserving intraosseous blood supply.
  - Low rate of avascular necrosis (AVN).
  - Minimally displaced fractures have a better outcome when physical therapy is initiated within 2 weeks, regardless of the age of the patient or greater tuberosity involvement.
  - Prolonged immobilization results in stiffness.
- **Pediatric proximal humerus fracture:**
  - Sling and swathe for 3 weeks, followed by gradual motion and strengthening.
  - Bayonet apposition can produce good results.

Humeral Shaft Fracture

- **Nonsurgical** is the usual treatment of choice. See Table 3-3 for surgical indications.
- **Initial:** Coaptation splint for 7–10 days, then functional brace; low nonunion rate.
- **Functional brace contraindications:**
  - Severe soft tissue injury or bone loss.
  - Unreliable patient.
  - Inability to obtain or maintain reduction (segmental fractures).
- **Plating** is current standard.
- **IM nail:** Increased shoulder pain.
- Neurovascular examination critical for preoperative or prereduction assessment.
- Radial nerve highest risk is in middle or distal one-third fractures.
- Neurapraxia most common with > 70% recovery over 3 months.
- Transverse fractures are most commonly associated with neurapraxia.
- Spiral fractures of distal one-third most commonly associated with laceration or entrapment (Holstein-Lewis).
- Radial nerve palsy with closed fracture on presentation.
  - Observe initially.
  - EMG/NCV at 6 weeks: Fasciculations, continued observation, fibrillations (denervation), then exploration.

Shoulder pain is the most common complication after IM nailing of a humerus fracture.

TABLE 3-3. Humerus Fracture Surgical Indications[a]

Open fracture	Bilateral fractures
Floating elbow	Polytrauma
Vascular injury	Brachial plexopathy
Intra-articular fracture	Nerve injury post reduction
Failure of closed treatment	Pathologic fracture
Large body habitus	Neuromuscular conditions
Segmental fractures	

[a]Boldface indicates absolute indications.

- Closed fracture with *anatomic* reduction: Observe.
- Irreducible fracture or evidence of soft tissue interposition: Explore.
- If radial nerve is in on presentation and then out after reduction, observe (unless new *pain*; then explore acutely).
- **Humerus nonunion:** Plate and screw fixation (consider dual plating) with autogenous bone grafting.

Distal Humerus Fracture

- **Distal metaphyseal fractures:** Disrupt medial and lateral columns, ORIF (dual plating).
- **Dual plating:** 90-degree offset posterolateral and medial has the greatest rigidity.
- **Intra-articular:** ORIF; most common nerve injured is ulnar nerve.
- Must visualize joint; transolecranon osteotomy is best for visualization.
- Most common complication: Stiffness.

Medial displacement: Radial nerve injury.

Posterolateral displacement: Brachial artery and median nerve injuries.

AIN is the most common nerve injured with supracondylar humerus fractures (extension type).

Pediatric Supracondylar Humerus Fracture

- Extension type is the most common (~96%).
- **Treatment:** Closed reduction and percutaneous pinning.
- **Anterior interosseous nerve** (**AIN**) is the most common palsy with extension type.
- Medial and lateral pins are the most stable construct (be aware of ulnar nerve with medial pin).
- Peak incidence in children who are ~7 years old.
- Distal supracondylar fractures can disrupt the lateral ossification center of the trochlea, leading to local osteonecrosis and disruption of the articular surface.
- Fracture malalignment is the most common cause of cubitus varus.
- Physeal damage is rare after supracondylar fractures.
- Angular malalignment corrects slowly and incompletely in the distal humerus, especially in the coronal plane.
- If pulses are absent but the hand is warm and pink: Closed reduction and pinning followed by observation.
- If hand is dysvascular: Surgical exploration to free entrapped vessels is warranted.

Pediatric Medial Epicondyle Fracture

- Unless the fragment is entrapped or significant valgus loading is anticipated, *nonoperative treatment* is indicated.
- Range of motion (ROM) should be started within 1 week.

Pediatric Lateral Condyle Fracture

- Closed reduction and pin fixation should be attempted if they are displaced more than 2 mm.
- If this is not successful, open reduction should be performed.
- Nonunion may develop if there is displacement > 2 mm because the fracture is almost completely intra-articular.

Olecranon Fracture

- Nondisplaced: Rare, nonoperative; splint with elbow between 45 and 90 degrees; frequent radiographic follow-up.
- **Stable and not comminuted:** ORIF (tension band vs. screw).
- **Comminuted:** Contoured 3.5 dynamic compression plate (DCP).
- Olecranon fracture can excise up to 50% before instability.
- The most common complication is *painful hardware*.

Pediatric Olecranon Fracture, Flexion Type

- Extensor mechanism disrupted.
- **Treatment:** Oblique screw across the fracture, with a tension band. Can use heavy absorbable suture as the tension band.
- No significant growth disturbance noted across apophysis with fixation.
- AO technique with parallel pins and wire tension band can be used but requires more extensive dissection for removal.

Coronoid Fracture

- Usually with elbow dislocations.
- Associated with recurrent instability after dislocations.
- ORIF when associated with instability.
- Nothing inserts on tip of coronoid, so type I fractures are *shear* injuries, not avulsions.

Radial Head Fracture

If patient has a minimally displaced radial head fracture, check pronation/supination. If no block to motion, treat with sling and early ROM.

- Mechanism of injury is usually axial load on to pronated forearm. Evaluate the distal radioulnar joint (DRUJ) and wrist.
- Most common is anterolateral due to no articular cartilage or subchondral bone.
- If minimally displaced, treat with early ROM if no mechanical block (may need to aspirate and inject local anesthetic).
- If displaced or mechanical block, treat with ORIF.
- If comminuted, treat with ORIF when possible; resect only if no wrist or DRUJ injury, otherwise replace with titanium head.
- **Safe zone** for plate is lateral with forearm in neutral (110 degrees).
- **Essex-Lopresti:** Radial head fracture with intraosseous membrane disruption.

Elbow Dislocation

The elbow joint should never be immobilized for more than 2–3 weeks.

- Posterolateral elbow dislocation is most common (80%).
- "Terrible triad": Elbow dislocation, coronoid fracture, radial head fracture.
- Primary stabilizers: Ulnar-trochlear articulation, anterior band of medial collateral ligament (MCL), ulnar portion of lateral collateral ligament (LCL).
- Secondary stabilizers: Radial head, capsule, muscles (flexors—biceps, brachialis, brachioradialis (BR); extensors—triceps).
- Never immobilize adult elbow more than 2–3 weeks (will get stiff).
- Simple dislocation's most common complication is elbow stiffness, and the patient should be aware of this prior to reduction. Begin early active motion exercises.

Radius/Ulna Fracture

- **Nightstick fracture (ulna):** Nonoperative treatment if nondisplaced isolated ulna fracture.
- Distal two-thirds ulna fracture with < 50% displacement and < 10 degrees angulation: Functional fracture brace with good interosseous mold.
- Proximal one-third ulna fracture or more displaced distal ulna fracture: ORIF.
- Radial shaft or both bone fractures require plating both: Immediate motion can be initiated, with function rapidly restored.
- Separate approach to ulna and radius *decreases synostosis rate* (see Table 3-4).

Radius Approaches

- **Volar (Henry):** Interval is BR and pronator teres (PT)/flexor carpi radialis (FCR); extensile, fasciotomies if needed, when exposing the proximal radius, full supination of the forearm is necessary to prevent damage to the posterior interosseous nerve (PIN).
- **Dorsal (Thompson):** Interval is extensor digitorum communis (EDC) and extensor carpi radialis brevis (ECRB); PIN at risk (from retraction) in proximal third (pronate to protect PIN).
- **Ulna:** Surgical interval is extensor carpi ulnaris (ECU), PIN, and flexor carpi ulnaris (FCU) (ulnar nerve).
- DCP 3.5 mm—standard AO technique.
- Restoring *radial bow* is important to maintain supination and pronation.
- To evaluate reduction, radial styloid should be 180 degrees to the bicipital tuberosity.

Pediatric Both-Bone Forearm Fracture

- Bayonet apposition is acceptable, as long as the angulation is < 10 degrees.
- Rotation must be acceptable as well.

Galeazzi Fracture

- Distal one-third radius fracture with DRUJ injury.
- If DRUJ is irreducible, ECU is probably entrapped.
- Treat with ORIF of radius and pinning of DRUJ vs. splinting in supination.

TABLE 3-4. Synostosis Risk Factors with ORIF of Both-Bone Forearm Fractures

Operate after 2 weeks	One incision
Fractures at the same level	Long screws and on interosseous membrane
High energy	Bone graft on interosseous membrane
Closed head injury	
Infection	

Monteggia Fracture

- Radial head dislocation with ulna fracture.
- Most common nerve injury is PIN (~20%).
- Most common reason for recurrent subluxation of the radial head: Malreduction of the ulna.

Pin Injury

- Unable to extend fingers at metacarpophalangeal joint (MCP) and lag in extension of thumb.
- It emerges from the supinator ~8 cm distal to the elbow joint.
- The nerve supplies branches to the ECRB and supinator before turning dorsally.
- After passing through the supinator, branches are supplied to the extensor digitorum, extensor digiti minimi (EDM), ECU, and interossei.
- Radial nerve innervates mobile wad.
- With PIN injury, wrist will actively dorsiflex and radially deviate from the mobile wad (branches to ECRB, extensor carpi radialis longus [ECRL], BR).

Distal Radius Fracture

- Lateral x-ray: Normal palmar tilt ~11 degrees.
- Posteroanterior (PA) view: Normal radial height ~12 mm, inclination ~23 degrees.
- Ulnar styloid fracture denotes higher-energy fracture and greater radial displacement.
- Distal radius fractures (and spinal fractures) in the elderly are predictive of future hip fractures.
- **Acceptable reduction (adult):**
  - Change in palmar tilt < 10 degrees from normal.
  - Radial shortening < 2 mm.
  - Change in radial inclination < 5 degrees.
  - < 1–2 mm articular stepoff.
- **Treatment options:**
  - Cast: Follow closely for displacement and skin problems; repeat reductions with < 50% satisfactory results.
  - Percutaneous pinning: Good results when used in appropriate situations.
    - Maintain sagittal alignment in unstable extra-articular fractures when stable volarly.
    - Does not maintain length when volar or bicortical comminution is present.
  - External fixation has a high complication rate.
  - ORIF for articular marginal impaction fractures and complex comminuted intra-articular fractures.
- Neuropathy in 1%–12%, 30% in high-energy fractures; most common is median nerve.
- Decompress nerve if paresthesias are progressive or do not respond to reduction and last > 24–48 hours.
- Beware of compartment syndrome.
- Carpal tunnel pressure is lowest with wrist in neutral position.
- Reflex sympathetic dystrophy (RSD) (chronic regional pain syndrome [CRPS]) association is not understood and has wide array of symptoms.

- Tendon problems:
  - DRUJ injuries may entrap ECU or EDM.
  - Extensor pollicis longus (EPL) is the most common tendon to rupture due to attrition; EIP transfer for EPL ruptures.
  - Tenosynovitis (first and third dorsal compartments): EPL requires early release.
  - Other peritendinous adhesions rarely require release unless refractory.
- **Malunion and nonunion:**
  - Takedown for intra-articular malunion > 6 weeks.
  - Extra-articular malunion requires opening wedge osteotomy, ORIF, and bone grafting.
  - Ulnar shortening should be added if radial length is not restored.
  - The primary factor in preventing disability related to the DRUJ is anatomic reduction of the distal radius.

Distal radius fracture with a volar shear component (volar Barton's) will need to be treated with a volar plate.

Ulnar Styloid Fracture

- Reflects high degree of initial fracture displacement.
- Fractures through the base are often associated with rupture of the triangular fibrocartilage complex (TFCC) and instability.
- Can have painful hypertrophic nonunion in the absence of instability.
- ORIF if there is associated instability.

Ulnar Impaction Syndrome

- Causes:
  - Radial shortening: Shorten by 2 mm and increase forces across ulna by 42%.
  - Positive ulnar variance.
  - Altered mechanics.
  - Lunate chondromalacia.
  - TFCC degenerative tears.
- **Treatment:**
  - Radial osteotomy.
  - Ulnar shortening.
  - TFCC debridement.
  - Distal ulna resection.

▶ PELVIS AND LOWER EXTREMITY TRAUMA

Pelvic Ring Injuries

- **Hemorrhage** is the leading cause of death.
- Initial team must always examine the perineum, vagina, and rectum to rule out occult open injuries.
- If diagnostic peritoneal lavage (DPL) is being performed with a pelvic ring injury, it should be done through a supraumbilical incision.
- **Pelvic crush injury:**
  - If gross hematuria, a bladder rupture must be ruled out.
  - An appropriate workup would include a cystogram with scout and postevacuation radiographs.
- **X-rays**
  - AP view.
  - Inlet view shows AP translation.

- Outlet shows vertical translation.
- Iliac oblique: Posterior column, anterior wall.
- Obturator oblique: Anterior column, posterior wall.

Patients with anterior pelvic ring injuries need to have a complete exam of perineum, vagina, and rectum to rule out occult open fractures.

- **Urogenital injuries:**
  - **Retrograde urethrogram (RUG)** should be performed with severely displaced anterior ring injuries, high-riding prostate, or blood at meatus.
  - Negative RUG with persistent hematuria should be followed by cystogram.
- **Open pelvis fracture** may require a diverting colostomy, in addition to the usual orthopaedic treatment.
- **Anteroposterior compression (APC) injury:** Be aware of visceral (pubic symphisis) injury, retroperitoneal hemorrhage.
- **Lateral compression (LC):** High incidence in closed head injury and intra-abdominal injury.
- **Vertical shear** is associated with intrapelvic hemorrhage.
- **Arterial injury from fracture:**
  - Most common is superior gluteal > internal pudendal > obturator > lateral sacral.
  - *Internal pudendal artery* tends to give most symptomatic bleeds.
  - If hemodynamically unstable after adequate resuscitation, pelvic binder, and thoracic abdominal sources ruled out, then needs angiography and embolization.
  - Early aggressive pelvic clamp, pelvic binder, or external fixation (if displaced anterior ring with stable posterior ring) to help control retroperitoneal hemorrhage.
- **Sacroiliac (SI) joint dislocations** require anatomic reduction and stabilization.
- **SI fracture–dislocation:**
  - When placing percutaneous SI screws, potential exists for L5 nerve root injury.
  - Pain is the most common reason for poor outcome.
  - Poor outcome is associated with:
    - SI incongruity.
    - High degree of initial displacement.
    - Malunion or residual displacement > 1 cm.
    - Leg length discrepancy > 2 cm.
    - Nonunion.
    - Neurologic injury.
    - Urethral injury.

The L5 nerve root is at risk for injury when placing percutaneous SI screws.

- Deep venous thrombosis (DVT) 60% incidence with pelvic fracture patients.
- 2% pulmonary embolism (PE) rate vs. 0.2% in polytrauma without pelvis fracture.

Sacral Fracture

- This is a highly missed injury.
- **Lower sacral root function:**
  - Anal sphincter tone/voluntary contracture.
  - Bulbocavernosus reflex.
  - Perianal sensation.
- **CT scan** is the study of choice.
- **Denis classification, three zones:**

- **Zone I** (50%):
  - Location: Alar fracture.
  - Neurologic injury ~6%.
  - L5 nerve root most commonly injured.
  - Nondisplaced: Nonoperative with protected weight bearing.
  - Displaced: Consider anterior ring stabilization.
  - Vertically unstable: Consider anterior and posterior stabilization.
- **Zone II** (34%):
  - Location: Transforaminal.
  - ~28% neurologic deficits.
  - Nerve roots most commonly injured: L5, S1, S2.
  - If foramen is patent: Nonoperative with protected weight bearing, frequent follow-up films.
  - If unstable and/or foraminal compromise: Indirect or direct decompression with anterior and posterior stabilization.
- **Zone III** (16%):
  - Location: Spinal canal.
  - ~57% neurologic deficit.
  - Injury is usually caudal and associated with bowel, bladder, and sexual dysfunction.
  - If stable and neurologically intact: Nonoperative (dictated by pelvic ring).
  - If neurologic deficit: Decompression with anterior and posterior stabilization.
  - Unilateral sacral root preservation is adequate for bowel/bladder control.
- **Transverse fractures:**
  - Upper S1–3: Higher incidence of bladder dysfunction.
  - Lower S4–5.
  - **Treatment** if displaced: Lateral mass plates.

Acetabular Fracture

Table 3-5 outlines the Letournel classification of acetabular fractures.

- **AP pelvis x-ray:**
  - Iliopectineal line (anterior column)
  - Ilioischial line (posterior column)

TABLE 3-5. Letournel Classification

Elementary Fractures	Combination Fractures
Posterior wall	Posterior column + posterior wall
Posterior column	Transverse + posterior wall
Anterior wall	T-type
Anterior column	Anterior with posterior hemitransverse
Transverse	Both columns ("floating acetabulum")

- "Teardrop"
- Weight-bearing dome
- Anterior wall
- Posterior wall
- **Iliac oblique** (45 degrees):
  - Posterior column
  - Anterior wall
- **Obturator oblique** (45 degrees):
  - Anterior column
  - Posterior wall
- **CT scan** to evaluate:
  - Articular surface involvement
  - Posterior wall size
  - Marginal impaction
  - Loose bodies
  - Preoperative planning
- **Nonoperative treatment:**
  - Non- or minimally displaced fracture (< 2 mm).
  - Displaced fracture with roof arcs > 45 degrees on AP and both Judet views.
  - Posterior wall fracture < 20%.
  - Secondary congruence in both column fractures.
- **Surgical indications:**
  - Displacement of dome > 2 mm.
  - Posterior wall fracture > 40%.
  - Marginal impaction.
  - Loose bodies in joint.
  - Irreducible fracture–dislocation.
- **Posterior approach (Kocher-Langenbach):**
  - Posterior wall, posterior column, transverse, transverse + posterior wall, T-type.
  - **Risks:** Sciatic nerve iatrogenic injury (2%–10%), damage to femoral head blood supply.
- **Anterior approach (ilioinguinal):**
  - Anterior wall, anterior column, anterior column with posterior hemi-transverse, both columns, transverse.
  - **Risks:** Femoral nerve injury, lateral femoral cutaneous nerve (LFCN) injury, femoral vessel thrombosis, laceration of corona mortis.
  - Lowest incidence of heterotopic ossification (HO).
  - *Corona mortis* connects external iliac and obturator systems.
- **Extensile approaches (triradiate, extended iliofemoral):** HO (common), possible posterior gluteal muscle necrosis.
- **Posttraumatic degenerative joint disease (DJD):**
  - Anatomic reduction essential to prevent DJD.
  - **Treatment:** Hip fusion vs. total hip arthroplasty (THA).
  - Results of THA after acetabular fracture not as good as for osteoarthritis (OA).

The appropriate surgical approach is critical to achieve adequate reduction and fixation of acetabular fractures.

Outcome after acetabular fracture correlates with accuracy of reduction.

Hip Dislocation

- **Physical exam:**
  - **Posterior dislocation** (much more common): Slight flexion, adduction, and IR.
  - **Anterior dislocation:** Flexion, abduction, and ER.

- Postreduction CT scan is indicated for all traumatic hip dislocations.
- Rule out femoral head fracture, loose body, nonconcentric reduction, acetabular fracture.
- **Treatment:**
  - Emergent closed reduction.
  - Reduce within 6 hours.
  - Patient supine; traction in line with deformity.
  - Assess hip stability post reduction.
- **Treatment post reduction:**
  - Remove incarcerated fragments if needed.
  - ORIF of femoral head and/or acetabular fractures if needed.
  - Stable hip joint without associated injuries: Protected weight bearing for 2–4 weeks.
- **Complications:**
  - Osteonecrosis of the femoral head (15%).
  - Posttraumatic arthritis (most common).
  - Recurrent dislocation rare.

Femoral Head Fracture

- **Indications for ORIF:**
  - Inadequate fracture reduction (> 1 mm stepoff) if above fovea.
  - Loose bodies within joint.
  - Associated neck or acetabular fracture.
  - Polytrauma patient.
- Surgical approach.
- Anterior approach (Smith-Peterson).
- Internervous plane: Superior gluteal and femoral (tensor fascia lata [TFL] and sartorius).
- Better visualization of head fragment.
- No increased risk of AVN.

Femoral Neck Fracture

- **Main blood supply** to femoral head: Medial femoral circumflex.
- **MRI** (study of choice) for occult fractures.
- **Displaced:** ORIF if young (< 50), hemiarthroplasty vs. THA if old (consider activity level) (see Figure 3-5).
- **Nondisplaced or valgus impacted:** Percutaneous pinning.
- **Hemiarthroplasty:**
  - Cemented results > uncemented.
  - Posterior approach (increased risk dislocation) vs. anterolateral (abductor weakness).
- **Osteonecrosis:**
  - Incidence: 10%–45%.
  - Increased risk with increased initial displacement, increased time to reduction, and nonanatomic reduction.
- **Nonunion:**
  - No healing at 12 months.
  - Incidence 10%–30%.
  - MRI to evaluate for osteonecrosis.
  - Valgus intertrochanteric osteotomy if head is viable.
  - Older patient: Prosthetic replacement.

MRI is the study of choice to rule out an occult femoral neck fracture.

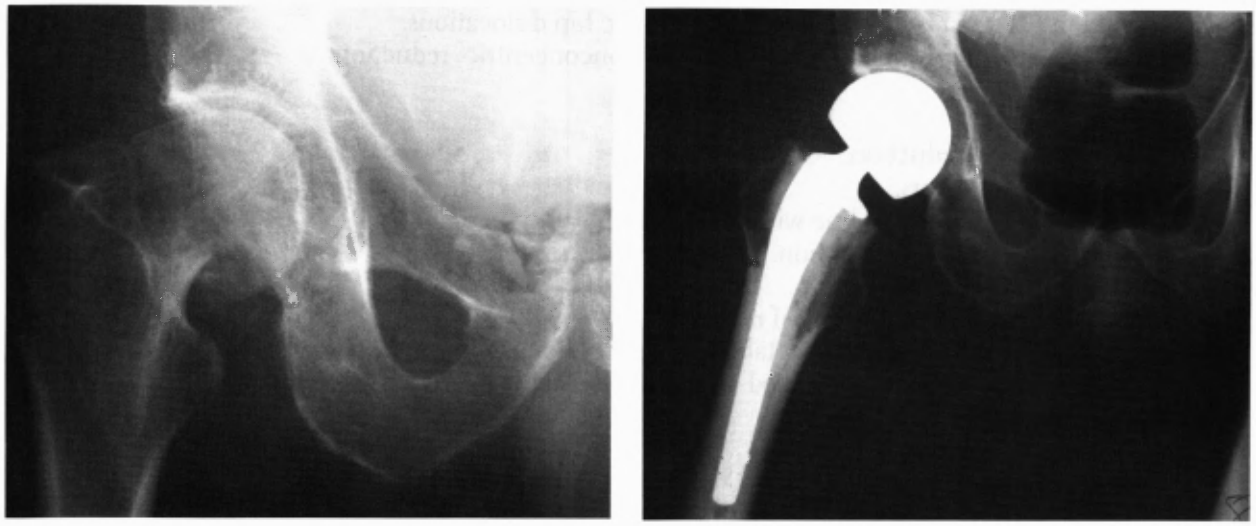

A B

FIGURE 3-5. Displaced femoral neck fracture (A). Treated with a cemented hemiarthroplasty (B).

Femoral Neck Stress Fracture

- **Compression type:**
  - Inferior femoral neck.
  - Usually stable.
  - Treat with protected weight bearing.
- **Tension type:**
  - Disruption of the superior neck.
  - Treat acutely with cannulated screws.

Intertrochanteric Hip Fracture

- **Classification:**
  - **Stable**: Will resist medial compressive loads once reduced.
  - **Unstable**: Will collapse into varus, or shaft will displace medially despite axial reduction of fragments.
- **Treatment:**
  - Surgical stabilization is indicated for previously ambulatory patients.
  - Early surgery within 48 hours if medically stable; associated with a decreased 1-year mortality.
  - Goal is to obtain neck–shaft axial alignment and correct translation.
  - Anatomic reduction of intermediate fragments is not necessary.
  - Medial displacement osteotomy is of no benefit.
  - **Sliding hip compression screw with side plate:**
    - Dynamic interfragmentary compression.
    - Can get medial displacement of shaft in unstable fracture patterns.
    - "Center/center" position of screw is best, with lowest rate of cutout.
    - Within 1 cm of subchondral bone, *tip-to-apex distance* < 25 mm.
    - Consider mild valgus overreduction in unstable fracture patterns.
  - **Cephalomedullary hip screw:** Possibly better for unstable fractures.
    - IM fixation (less torque).
    - Resists excessive fracture collapse and medialization.
    - "Percutaneous" insertion.

- Possible faster rehabilitation.
- Risk of shaft fracture at tip.
- **Reverse obliquity fracture:**
  - Do *not* use sliding hip screw.
  - 95-degree fixed-angle device indicated (blade plate, dynamic condylar screw [DCS]), or cephalomedullary nail.
- **Postoperative treatment:**
  - Weight bearing as tolerated.
  - Cognitively intact will "auto-protect" unstable fractures.
  - The most common complication is implant failure.

A center/center position with a tip-apex distance (TAD) of < 25 mm will help prevent compression screw cutout.

Subtrochanteric Hip Fracture

- Usually high-energy trauma, younger patients.
- Lesser trochanter to 5 cm distally.
- Strong muscular forces with long lever arms and increased bending moments.
- High compressive forces medially and tensile forces laterally.
- Proximal fragment goes into abduction, flexion, and ER.
- Transition from cancellous to cortical bone.
- High rate of implant failure.
- **Russell-Taylor classification:**
  - **Type I:** No extension into piriformis fossa.
  - **Type II:** Extension into greater trochanter with involvement of the piriformis fossa.
  - **Look on lateral x-ray for piriformis fossa extension.**
- **Treatment** (Table 3-6):
  - **IM fixation:**
    - Preserves vascularity.
    - Load-sharing implant.
    - Bone graft effect of reaming.
    - Significantly stronger construct in unstable fracture patterns.
    - Insertion of nail cannot reduce fracture.
    - May be contraindicated in type II fractures.
    - IM nail has lower reoperation at 1 year, compared to fixed-angle device and side plate.

TABLE 3-6. Subtrochanteric Fracture Treatment Options

Subtrochanteric Fracture	Treatment Options
Below lesser trochanter	First-generation IM nail
Extends above lesser trochanter, without piriformis extension	Second-generation IM nail or plate device
Below lesser trochanter, with piriformis extension	Cephalomedullary nail or plate device
Extends above lesser trochanter, with piriformis extension	Plate device

With subtrochanteric fractures, be aware there is a high rate of implant failure before union occurs.

- **Extramedullary fixation:**
  - Fixed-angle device with long side plate.
  - Compromises vascularity of fragments.
  - Less strong implant in unstable fractures.
  - Consider bone graft if medial comminution.
  - Indicated for type II fractures.
- **Complications:**
  - Implant failure/loss of fixation.
  - Nonunion (defined at ~6 months).
  - Malunion (length and rotational differences).

Femoral Shaft Fracture

- High-energy mechanism of injury.
- Associated injuries are common.
- Bilateral femur fractures are at increased risk of complications.
- Early stabilization of femoral shaft fractures (within 24 hours) associated with: IM.
  - Decreased pulmonary complications.
  - Decreased thromboembolic complications.
  - Increased rehabilitation of patients.
  - Decreased costs of hospitalization.
- If severe closed head injury, may benefit from longer delay before surgery (to prevent hypotension and a possible second hit to the brain).
- HO in abductors after antegrade femoral nail is related to reaming.
- **Treatment options:**
  - **External fixation:**
    - Indications: Unstable polytrauma patient, severe open fracture, associated vascular injury.
    - Complications: Pin tract infections, knee stiffness.
    - May be safely converted to IM fixation within 2–3 weeks.
  - **Plate fixation:**
    - Usually reserved for special cases (e.g., neck–shaft fracture).
    - Higher incidence of infection, nonunion, and implant failure.
  - **IM nailing:**
    - Treatment of choice for vast majority of femoral shaft fractures.
    - Union rate ~98%–99%.
    - Complications are infrequent.
    - Be aware of possible pudendal nerve injury from compression of perineal post on fracture table.
    - If significant head injury, consider treating with delayed IM nailing.
    - Unreamed nails: Decreased union rate and increased time to union.
    - Reamed insertion is the preferred technique.
    - Reamer design and technique are important: Sharp reamers, deep flutes, small reamer shafts; advance slowly.
    - Consider unreamed technique in a patient with bilateral chest injury.
  - **Retrograde IM nail** (Figure 3-6):
    - Current accepted indications:
      - Obesity.
      - Ipsilateral tibial shaft fractures (floating knee).
      - Ipsilateral neck–shaft fractures.

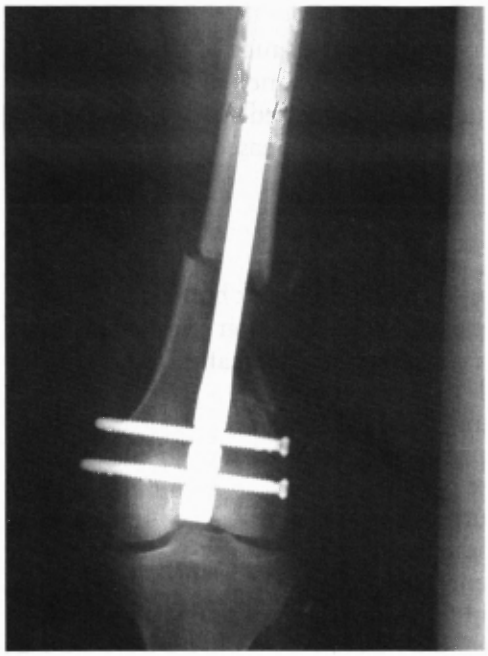

FIGURE 3-6. Distal third comminuted femur fracture. Treat with a locked reamed retrograde femoral nail.

    - Ipsilateral acetabular fractures.
    - Traumatic knee arthrotomy (clean).
    - Bilateral femur fractures.
- **Open femur fractures:**
    - Emergent surgical debridement.
    - Reamed IM nailing.
    - Delayed wound closure.
    - Results comparable to closed fractures.
- **Gunshot femur fractures:**
    - **Low velocity:** Immediate reamed nailing.
    - **High velocity:** Aggressive soft tissue management; external fixation vs. unreamed nail.
- **Ipsilateral femoral neck fracture:**
    - Overall incidence: ~2%–6%.
    - Missed ~30% of time.
    - Usually seen with comminuted midshaft fractures.
    - Neck fractures are given priority in treatment and should have separate fixation.
    - If missed, should be treated with percutaneous lag screws anterior to the nail.
- **Complications:**
    - Infection: Rare (< 1%); treat with nail removal after fracture healing, reaming of canal.
    - Delayed union: Treat with dynamization +/– bone grafting.
    - Nonunion: Treat with reamed exchange nailing.
    - Nerve injury: Pudendal (from perineal post pressure).
    - HO is the most frequent complication (25%); rarely clinically important.

The treatment of choice for almost all femoral shaft fractures is a reamed IM nail.

- Malunion:
  - Nail supine: Increased chance of IR.
  - Nail lateral: Increased chance of ER.
  - Nail with traction: Increased chance of being too long.
  - Nail without traction: Increased chance of being too short.

Pediatric Femur Fracture

Piriformis entry nails risk injuring the lateral ascending vessels of the femoral neck and can lead to osteonecrosis of the femoral head.

- 0–6 months of age: Treat with Pavlik harness.
- 6 months to 6 years: Closed reduction and spica cast.
- Surgical fixation (flexible nails) indications:
  - > 6 years old
  - Severe comminution
  - Polytrauma patient
  - Floating knee
  - Vascular injury
- Rigid IM nail indications:
  - Mature patient (closed physes)
  - Obese patient (aids in rotational stability)
- Closed reduction and flexible IM nailing for transverse fracture.
- Interlocking nails with piriformis entry runs the risk of greater trochanteric growth disturbance and/or osteonecrosis of the femoral head.
- Plate fixation, while effective, requires considerable tissue dissection for insertion and removal.
- Distal femoral physis has the highest rate of growth arrest following injury (50%), followed by the distal tibia (32%) and distal radius (4%); almost never occurs at distal and proximal humerus.

Distal Femur Fractures

- High-energy trauma in young patients, with typically significant displacement.
- Low-energy trauma in older patients, with typically less displacement and osteoporotic bone.
- Potential for injury to popliteal artery with significant displacement.
- Angiography indicated if no pulses after gross alignment is restored.
- **Treatment:**
  - **Nondisplaced fractures:**
    - Hinged knee brace.
    - Non–weight bearing for 6 weeks.
    - Start immediate motion of knee.
  - **Displaced fractures:**
    - Anatomic reduction of joint surfaces (lag screws).
    - Stable fixation of articular segment to diaphysis.
    - Preserve vascularity of fragments.
    - Start early motion of knee joint.
  - **Surgical options:**
    - **Fixed-angle plate devices:**
      - Most stable construct; union rates 92%–96%.
      - Need ~2 cm from joint for blade and ~4 cm for DCS.
      - May be contraindicated with coronal (Hoffa's) fracture.
      - Direct reduction via lateral approach.
      - Indirect reduction with percutaneous plating for complex fractures.

- **Non-fixed-angle plating:**
  - Condylar buttress plate.
  - Useful in severely comminuted fractures (coronal plane fractures).
  - Tendency for *varus* malalignment.
- **Retrograde IM nails:**
  - Useful for supracondylar fractures without significant comminution (see Figure 3-6).
  - Preferred implant in osteoporotic bone and periprosthetic fractures.
  - Consider retrograde in multitrauma (especially ipsilateral ankle or leg).
  - Less axial and rotational stability.
  - Increased knee pain postoperatively.

Knee Dislocation

- High incidence of associated injuries:
  - Vascular injury: ~30%.
    - **"Hard" signs:** Absent pulses, bleeding, expanding hematoma, bruit, thrill.
    - **"Soft" signs:** Diminished pulses, decreased capillary refill, hypesthesia, decreased leg temperature.
  - Neurologic injury (peroneal nerve): ~23%.
- **Treatment:**
  - Orthopaedic emergency.
  - Reduce knee and reexamine neurovascular status (see Figure 3-7).
  - Early vascular consultation; consider angiogram.

FIGURE 3-7. Posterior knee dislocation. Treat with emergent reduction and vascular exam.

If hard signs of a vascular injury exist after reduction of knee dislocation, patient should go straight to the OR with a vascular surgeon, not to the angiography suite first.

- Ligament repair.
  - Important to repair posterior cruciate ligament (PCL), posterolateral corner.
  - Augmentation/substitution is often necessary.
  - Treat MCL nonoperatively.
- **Complications:**
  - Rarely have "normal" knee.
  - Stiffness most common.
  - Neurologic/vascular injury.
- **Treatment of vascular injury:**
  - If hard signs: No preoperative arteriogram needed, straight to OR.
  - If soft signs post reduction: Arteriogram indicated.
  - Revascularize within 6 hours.
  - Reverse saphenous vein graft.
  - Fasciotomy is typically indicated after vascular repair.

Patella Fracture (Figure 3-8)

- Inability to actively extend the knee is indicative of a clinically significant extensor mechanism injury.
- **Classification:**
  - Transverse
  - Vertical
  - Comminuted (stellate)
- **Treatment:**
  - **Nonsurgical:**
    - If nondisplaced fracture or minimally displaced with intact extensor mechanism.
    - Hinged knee brace for 4–6 weeks, weight bearing as tolerated with brace locked in extension.
  - **Surgical:**
    - ORIF (tension band) vs. partial patellectomy for displacement of 3-mm or 2-mm articular surface displacement.

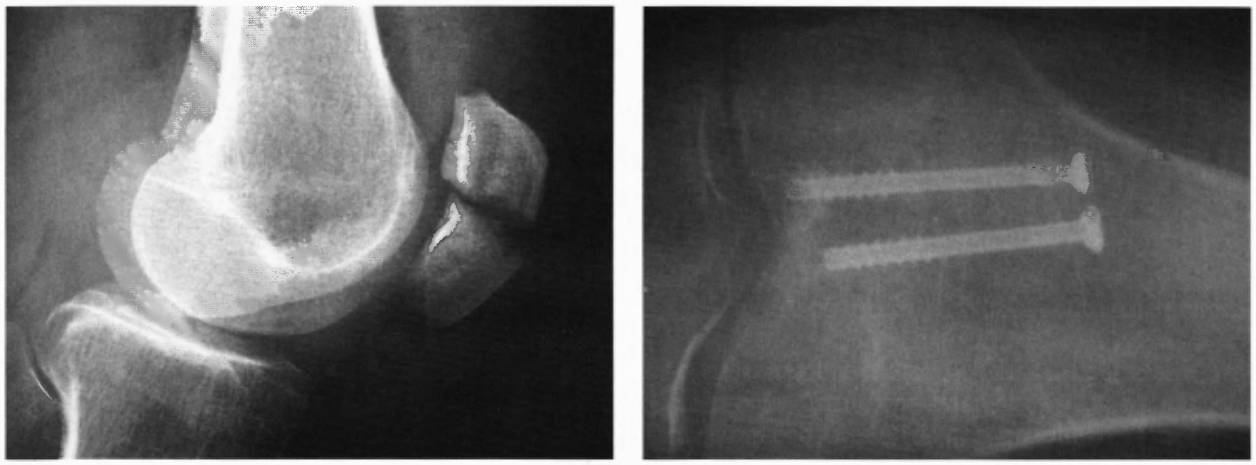

A B

FIGURE 3-8. Transverse patella fracture fixed with screws.

    - Preserve patella whenever possible.
    - No role for complete patellectomy.
  - **Partial patellectomy:**
    - Extra-articular distal pole fractures (distal 30%).
    - Severely comminuted fractures.
    - Preserve largest pieces and reattach patella tendon anteriorly.
  - **Open fractures:** Treat as closed fracture (ORIF) following debridement.
- **Complications:**
  - Symptomatic hardware (common).
  - Loss of reduction (up to 20%): Technical errors, patient noncompliance.
  - Nonunion: < 5%.
- **Patella sleeve fracture:**
  - Patella tendon avulsion from the inferior patella, along with the retinaculum and articular cartilage.
  - Common in children between ages 8 and 10 years.
  - **Treatment:** Anatomic reduction and repair of the extensor mechanism.

The key structure injured with a patella dislocation is the medial patellofemoral ligament.

Patella Dislocation

- Typically adolescents and young adults.
- Reduce with knee full extension.
- High redislocation rate.
- Injury to medial *patellofemoral ligament*.

Patella Tendon (Ligament) Rupture

- Typically active adult patients (< 40 years old).
- Patellar tendinitis is a risk factor.
- **X-ray:** Patella alta.
- Ligament typically avulses off distal pole of patella.
- **Treatment:**
  - Direct primary repair indicated with nonabsorbable suture.
  - Patellar drill holes or suture anchors (consider using ACL guide to direct your drill holes).
  - Consider supplementation with cerclage wire or tape.

A patient < 40 years old is more likely to have a patella tendon rupture; quadricep rupture is more typical in a patient > 40 years old.

Quadricep Tendon Rupture

- Older adults (> 40 years old) with predisposing medical risk factors.
- Diagnosis is more difficult (consider MRI).
- Most common location of rupture is ~2 cm above proximal pole.
- **Treatment:**
  - Surgical repair is indicated for loss of active knee extension.
  - End-to-end primary repair.
  - Worse results with late repair.

Tibial Plateau Fracture

- Mechanism of injury: Varus–valgus loading with axial compression.
- Lateral plateau > bicondylar > medial plateau.
- **Associated injuries:**
  - 50% incidence of soft tissue injuries.
  - Meniscal tears: 47%.

- MCL > ACL.
- Compartment syndrome.
- **Classification:** Schatzker
  - I: Split fracture lateral.
  - II: Split-depressed fracture lateral.
  - III: Pure depression fracture lateral.
  - IV: Medial plateau fracture.
  - V: Bicondylar fracture.
  - VI: Metaphyseal–diaphyseal disassociation.
- **CT scan** is useful to identify articular depression, fracture comminution, and in preoperative planning.
- **Treatment:**
  - **Nonoperative:**
    - Indications: < 3-mm stepoff, stable knee full extension (< 10-degree varus-valgus instability).
    - Hinged brace with early ROM and delayed weight bearing.
  - **Operative indications:**
    - Articular stepoff 3 mm.
    - Condylar widening > 5 mm.
    - All medial plateau fractures.
    - All bicondylar fractures.
  - The posteromedial approach is between the semimembranosus and medial gastrocnemius.
  - Avoid varus malalignment (poor outcome).
  - **Plate fixation:**
    - Direct anatomic reduction.
    - Achieve rigid fixation.
    - High incidence of complications.
    - Must respect soft tissues.
    - Avoid "dead bone sandwich."
  - **External fixation:**
    - Best for bicondylar fractures.
    - Minimal soft tissue insult.
    - Used with limited open or percutaneous fixation of articular segments.
    - Keep thin wires >14 mm from joint; avoid septic knee.
  - **Bridging external fixation:**
    - Temporary stabilization.
    - Can restore length, angular, and rotational alignment.
    - Can affect indirect joint reduction.
    - **Indications:** Significant soft tissue injury, polytrauma.
  - **Outcomes:**
    - Increased risk of posttraumatic arthritis (5–7 years).
    - Worse results with ligamentous instability.
    - Worse results with menisectomy.
    - There are fewer wound complications if surgery is delayed 10–20 days. Other outcome parameters are the same.

Correct overall alignment is most important for outcome after fixation of a tibial plateau.

Tibial Shaft Fracture

- Soft tissue injury is critically important.
- **Treatment of closed fractures:**
  - Cast immobilization:
    - Best for low-energy fractures, transverse fractures in children.
    - Closed reduction/long leg cast.

- Early transition to functional brace.
- High success rate if acceptable alignment:
  - Varus-valgus angulation ≤ 5 degrees.
  - Sagittal plane angulation ≤ 10 degrees.
  - Cortical apposition ≥ 50%.
- Shortening ≤ 1 cm.
- Rotational alignment within 10 degrees.
- In children, metaphyseal fractures can result in late *genu valgum*. Treatment is observation.
  - IM nailing:
    - Unacceptable alignment with reduction and casting.
    - Significant soft tissue injury.
    - Segmental fracture.
    - Ipsilateral limb injury.
    - Polytrauma.
    - Bilateral tibia fractures.
    - Morbid obesity.
    - Decreased time to union and increased union rate vs. closed treatment for displaced fractures.
    - Statically interlock for rotational stability.
    - Reaming causes damage to endosteal vascularity, but increases periosteal flow.
    - Reamed technique *superior* (decreased time to union, increased union rate, less hardware failure).
    - Reamed IM nails are contraindicated in children with open physes.
    - Compartment pressures are greatest when *constant traction* is applied.
    - **Complications:**
      - Anterior knee pain, incidence ~50%.
      - Higher with patellar tendon splitting.
      - Pain relief after nail removal is unpredictable.
  - External fixation:
    - May be useful in proximal and distal metaphyseal fractures.
    - Pin tract infections are common.
    - Higher incidence of malalignment compared to IM nailing.
- **Treatment of open fractures:**
  - Emergent surgical debridement.
  - Remove all devitalized tissue, including cortical bone if necessary.
- **External fixation vs. IM nailing:**
  - No difference in infection rates or time to union.
  - IM nailing is associated with decreased malalignment, decreased secondary surgeries, and decreased time to weight bearing.
- **Relative indications for amputation:**
  - Warm ischemia time > 6 hours, no plantar sensation, severe ipsilateral foot trauma.
  - Lower Extremity Amputation Prevention (LEAP) study: No significant difference in functional outcomes with salvage vs. amputation.
- **Complications:**
  - Most common complication is knee pain and ankle stiffness.
  - Nonunion or delayed union: ~6–9 months.
  - **Treatment options:**
    - Nail dynamization (axially stable).
    - Exchange nailing (not axially stable).
    - Posterolateral bone grafting (bone loss).
    - Noninvasive (electrical stimulation, ultrasound).

Cortical apposition < 50% is associated with higher reoperation rates in tibial shaft fractures.

IM nailing is the treatment of choice for high-energy and/or unstable tibial shaft fractures.

- **Compartment syndrome:**
  - High index of clinical suspicion with both open and closed fractures.
  - On exam, key finding is pain with passive stretch and pain out of proportion.
  - Most sensitive indicator: Compartment pressure within 30 mm Hg diastolic blood pressure (BP).
  - Treatment is an emergent fasciotomy.

Tibial Plafond (Pilon)

- High-energy trauma (axial loading).
- Characteristically have articular impaction and comminution.
- Significant associated soft tissue injury.
- Associated musculoskeletal injuries.
- Increasing incidence.
- Almost always displacement.
- **Treatment:**
  - Surgery is indicated for displaced fractures.
  - Temporary bridging external fixator followed by ORIF at 10–14 days (see Figure 3-9).

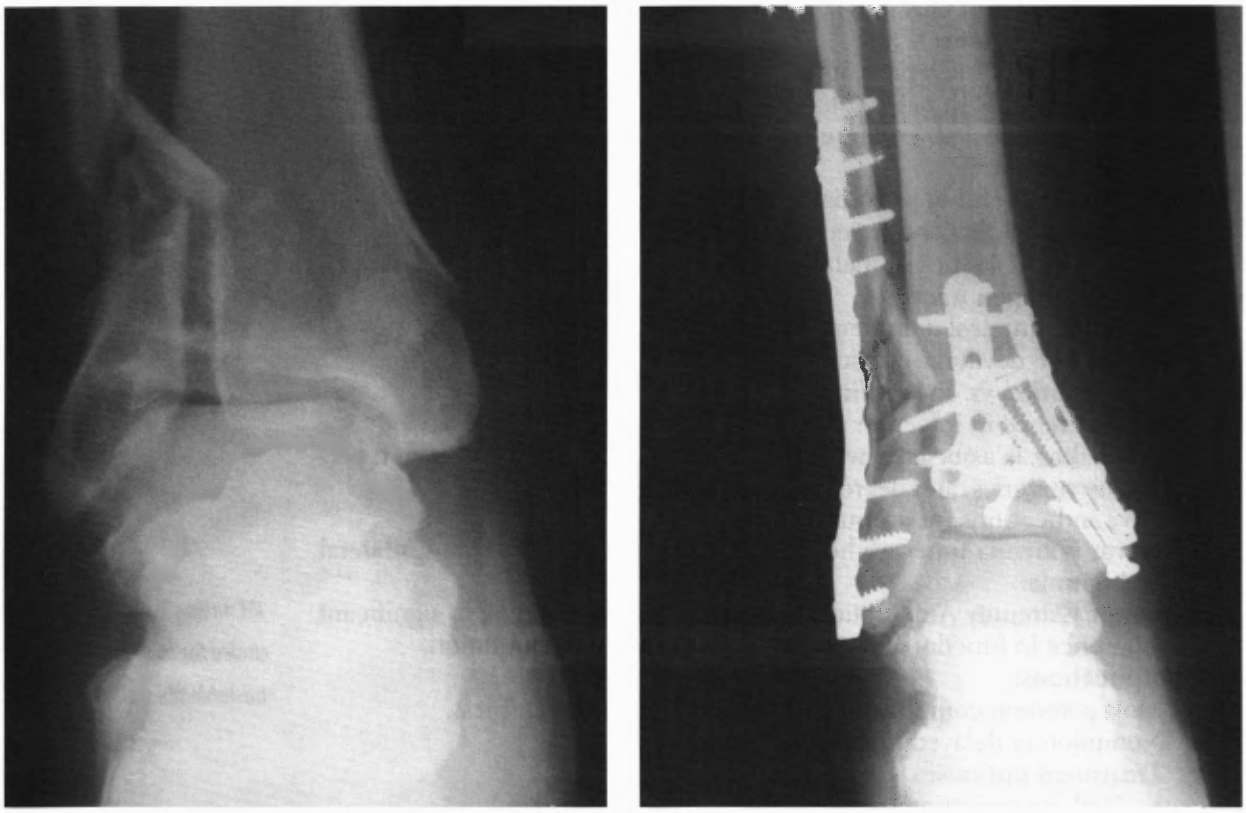

A B

FIGURE 3-9. **(A)** Pilon fracture treated with acute spanning external fixation and fibular plating. **(B)** Delayed definitive treatment with anatomic articular reduction and internal fixation.

- High incidence of soft tissue complications with ORIF.
- Full-thickness flaps are essential; must be gentle to soft tissue.
- Need at least a 7-cm skin bridge.
- No benefits to acute fixation.
- For postoperative wound breakdown, the treatment of choice is *free flap* because rotation flaps in poor tissue are not as good.
- **Complications:**
  - Wound slough (~10%).
  - Deep infection.
  - Malunion, most commonly varus.
  - Nonunion.
  - Posttraumatic arthrosis.
- **External fixation:**
  - Decreased incidence of wound complications and deep infection compared to ORIF.
  - No significantly increased ankle ROM demonstrated with nonspanning fixators.
- **Complications:**
  - Pin and/or wire tract infections.
  - Neurovascular injury.
  - Loss of ankle motion.

There is a high incidence of wound problems with immediate ORIF of pilon fractures; spanning external fixation with limited initial fixation is preferred.

Ankle Fracture

Figure 3-10 shows radiographic images of ankle fracture.

- **Classification:**
  - **Lauge-Hansen:**
    - Supination–adduction
    - Supination–ER
    - Pronation–abduction
    - Pronation–ER
  - **Danis-Weber** (based on level of fibular fracture):
    - A: Infrasyndesmotic
    - B: Transsyndesmotic
    - C: Suprasyndesmotic
- Most important when assessing for surgical treatment is the position of the talus in the mortise.
- Regarding swelling, the best determinant for surgical timing is the *wrinkle sign* at the site of incision.
- Any abrasion should be epithelialized before operating through this skin.
- **Treatment:**
  - Goal of treatment is anatomic reduction of talus in mortise.
  - 1-mm lateral talar shift: 42% increased tibiotalar contact stress.
  - Any talar displacement is indication for ORIF.
  - Fix posterior malleolus if > ~25% of articular surface or stepoff > 2 mm.
  - Keep diabetics non–weight bearing for 3–6 months.
- **Complications:**
  - Wound problems: ~5%.
  - Deep infection: ~2%.
  - Posttraumatic arthrosis, rare following surgical reduction and fixation.
  - Diabetes: High complication rate with deep infection rate up to 20%.
- **Posttraumatic ankle arthrosis:**
  - Treat with ankle arthrodesis.
  - Long-term sequelae of arthrodesis is ipsilateral hindfoot and midfoot arthrosis.

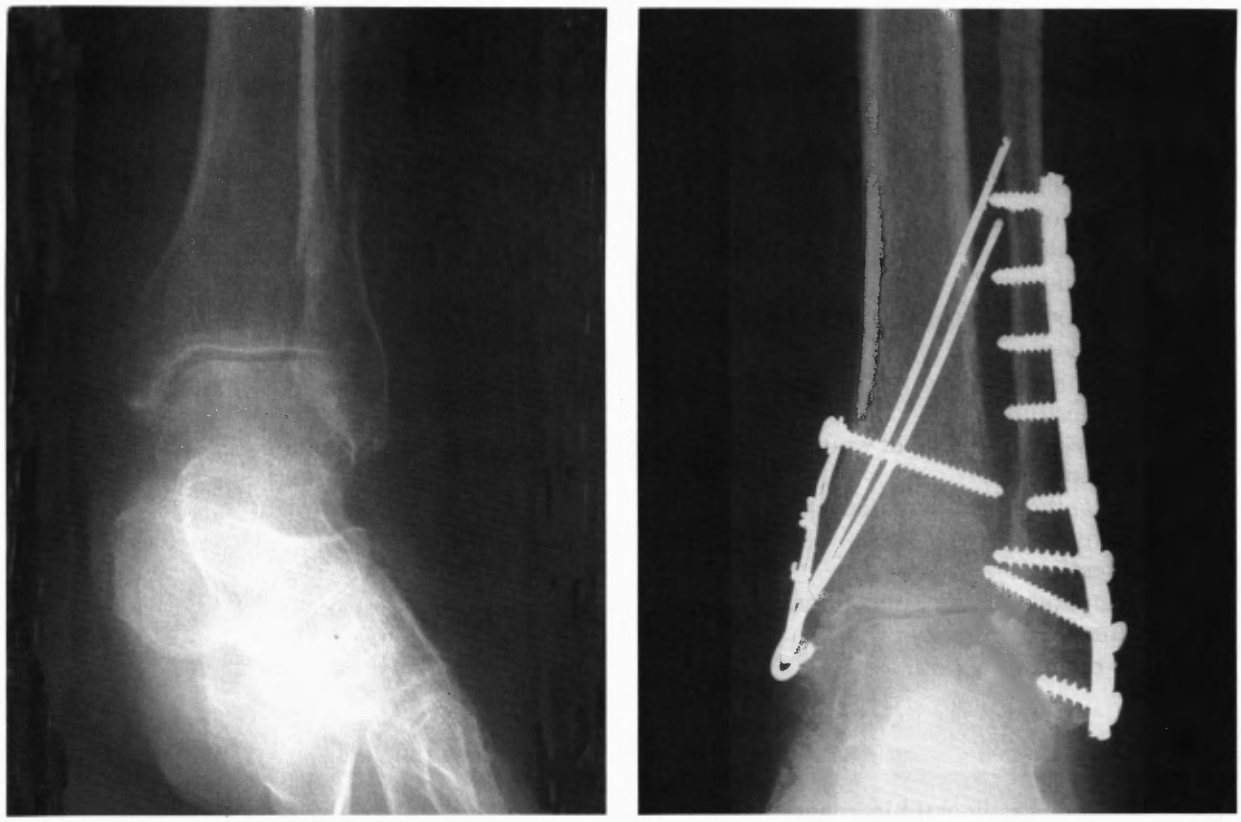

A B

FIGURE 3-10. **(A)** AP of ankle fracture. **(B)** Patient with significant osteoporosis treated with anatomic reduction of mortise and internal fixation.

Intraoperative stress testing is the most reliable means of assessing syndesmotic injury.

Syndesmotic Disruption

- Assess stability intraoperatively.
- Fixation typically not required when fibula fracture is within 4.5 cm of joint.
- Treatment:
  - One or two cortical screws (not lag) 2 cm above joint, 3 or 4 cortices.
  - Dorsiflexion of ankle not necessary.
  - 30% risk of screw breakage with weight bearing.
  - Do not remove screws before 3 months.

Open Ankle Fracture

- Emergent operative debridement.
- Immediate ORIF.
- Results for lower-grade open fractures similar to closed fractures.

Achilles Tendon Rupture

- 2–4 cm above calcaneal insertion (most common location).
- Diagnosis: Thompson test.

- Missed diagnosis up to 25%, often called an "ankle sprain"; must do Thompson test.
- **Treatment:**
  - Surgical repair vs. casting.
  - With surgery there is a *decreased rerupture rate* and increased plantar flexion strength.
  - Percutaneous repair is weaker, yet fewer wound complications.

For chronic Achilles tear (> 1 month), consider supplementing with flexor hallucis longus (FHL) transfer or a turn-down flap.

Os Peroneum

- Accessory ossicle located within the *peroneus longus*, typically located at the level of the *cuboid groove* in the lateral hindfoot and midfoot region.
- Proximal migration indicates disruption of the tendon.

Acute Peroneal Tendon Dislocation

- Consider acute repair of periosteal attachment of the peroneal sheath and the superior peroneal retinaculum.

Talar Neck Fractures

See Table 3-7 for talar neck fracture classification.

- Most common of talus fractures.
- Mechanism: Forced dorsiflexion with axial load.
- High incidence of osteonecrosis.
- **Treatment:**
  - Displaced fractures require urgent treatment (ORIF).
  - Anatomic reduction is necessary.
  - Dorsomedial comminution is common.
  - Two 4.0-mm screws is the common accepted construct.
  - Posterior-to-anterior screws provide better construct.
  - Non–weight bearing for 10–12 weeks.
- **Complications:**
  - Subtalar arthritis (most common).
  - Tibiotalar arthritis.
  - Varus malunion: Treatment is triple arthrodesis.
  - Osteonecrosis: Treatment is tibiocalcaneal fusion.

TABLE 3-7. Talar Neck Fracture Classification

Type	Fracture Pattern	% Chance AVN
Hawkins I	Nondisplaced	0%–13%
Hawkins II	Displaced with subtalar dislocation	20%–50%
Hawkins III	Displaced with talar body dislocation	20%–100%
Hawkins IV	Displaced with talar body and head dislocation	100%

AVN, avascular necrosis.

Hawkins sign is seen as a subchondral lucency of AP x-ray at 6–8 weeks after talus fracture; it is indicative of intact vascularity (no AVN).

Talar Process Fracture

- Lateral > medial.
- Often misdiagnosed as an ankle sprain.
- Nondisplaced: Short leg cast for 6 weeks; non–weight bearing.
- Displaced: ORIF of large fragments or excision of small fragments.
- **Snowboarder's fracture:** Lateral process of talus, due to dorsiflexion, axial load, inversion, and ER.

Subtalar Dislocation

- High energy; often open.
- Medial > lateral.
- **Treatment:** Closed reduction; short leg cast for 4–6 weeks.
- If irreducible *lateral* dislocation, the most common structure preventing reduction is the *posterior tibial tendon* (flexor digitorum longus also can block reduction). If irreducible *medial* dislocation, it is the *extensor digitorum brevis* or extensor retinaculum, or navicular fracture.
- Most subtalar dislocations result in *hindfoot stiffness*, usually asymptomatic.
- Painful *degenerative arthrosis* is the most common serious complication.

Calcaneus Fracture

See Table 3-8 for Sanders classification of calcaneus fractures.

- Primary fracture line in an axial loading fracture of the calcaneus occurs from superior lateral to inferior medial.
- Calcaneus separates into the sustentacular and tuberosity fragments and typically enters the subtalar joint through the posterior facet.
- CT scan performed in the axial and semicoronal planes.
- **Sustentaculum tali** remains in its anatomic position during calcaneus fractures.
- The FHL runs within the sustentaculum.
- Subchondral lag screws placed across the posterior facet exit the medial side of the calcaneus in the FHL groove, which can cause triggering of the FHL.
- When reducing, the primary fracture line is key, and the fracture is typically reduced to the sustentacular fragment, which is typically maintained in the appropriate location.

TABLE 3-8. Sanders Classification, Based on Coronal CT Images of Posterior Facet

Type	Fracture Pattern
I	Nondisplaced posterior facet
II	Single fracture line posterior facet
III	2 fracture lines with 3 posterior facet fragments
IV	3 fracture lines with 4+ posterior facet fragments

- **Posttraumatic subtalar arthrosis** following calcaneus fracture:
  - If no hindfoot deformity, in situ subtalar joint arthrodesis is the treatment of choice.
  - Calcaneal osteotomy or distraction bone block arthrodesis is beneficial in patients with severe dorsiflexion or malunion of the calcaneal body.
- **Treatment:**
  - **Nonoperative:**
    - Nondisplaced or extra-articular fractures.
    - Cast vs. cast-boot; early ROM.
    - Closed reduction cannot restore articular congruity.
  - **Operative:**
    - Better outcomes:
      - Age < 40
      - Female
      - Unilateral injury
      - Not job related
    - Worse outcomes:
      - Worker's compensation patients
      - Age > 40
      - Smoking
      - Vasculopathies
    - Increased trend toward surgical intervention.
    - Goal is anatomic reduction.
    - Low-profile implants.
    - Wound complications ~10%–20% (increased risk with tobacco and diabetes).
- **Complications:**
  - Compartment syndrome: 10%.
  - Heel deformities/malunion (varus hindfoot/shortening).
  - Subtalar arthrosis.
  - Factors associated with poor outcome: Age > 50, obesity, manual labor, worker's compensation.
- **Tongue-type fracture** (Essex-Lopresti) can be treated with closed reduction and pinning.
- **Anterior process fracture:**
  - If < 25% of the joint is involved with minimal displacement, treat with a walking cast or removable boot.
  - If > 25% joint involvement with joint incongruity, treat with ORIF.

The sustentaculum tali is the constant fragment; it remains in its anatomic position during calcaneus fractures.

Navicular Fracture

- **Dorsal lip avulsions** are most common; symptomatic treatment for most (short leg cast).
- **Tuberosity fractures:** Posterior tibial tendon insertion; ORIF if displaced or articular surface is involved.
- **Body fractures:** Intra-articular; ORIF indicated.
- **Stress fractures:** Central one-third; *short leg cast, non–weight bearing* for 6 weeks.

Cuboid Fracture

- **Avulsions:** Symptomatic treatment.
- "Nutcracker": Compression fracture between calcaneus and metatarsal; shortens lateral column; treat with ORIF vs. external fixation.

Lisfranc Fracture–Dislocation

- Injury to tarsometatarsal joint(s).
- Secondary high-energy trauma.
- Usually associated with fractures.
- Subtle injuries may be missed.
- Ligament runs from medial cuneiform to the base of the second metatarsal, plantar side.
- The ligament tightens with pronation and abduction of the forefoot.
- This maneuver causes pain in acute ruptures.
- Diagnosis with plain films:
  - AP: Alignment of second metatarsal with middle cuneiform.
  - Oblique: Alignment of fourth metatarsal with cuboid.
  - Lateral: Dorsal displacement of metatarsophalangeal (MTP) joints.
- **Classification:**
  - Homolateral
  - Isolated
  - Divergent
- **Treatment:**
  - ORIF is most commonly indicated.
  - Goal: Anatomic reduction and stable fixation.
- **Postoperative treatment:**
  - Early ROM midfoot.
  - Protected weight bearing.
  - Hardware removal:
    - K-wires: 6–8 weeks.
    - Screws: 3–6 months.
- Improved outcomes with anatomic reduction.
- Common to have altered gait, posttraumatic arthrosis.
- May be a source of significant long-term disability and pain.
- Midfoot arthrodesis for posttraumatic arthrosis that fails conservative therapy.

Metatarsal Fracture

- Common, must rule out Lisfranc injury.
- Commonly treated nonoperatively.
- **Nonoperative treatment:**
  - Cast/healing shoe.
  - Weight bearing to comfort.
- **Operative indications:**
  - Open fractures.
  - First, fifth metatarsal fractures (get internal splint with central metatarsal fractures).
  - Multiple metatarsal fractures.
- **Jones fracture**
  - Proximal metadiaphyseal junction fifth metatarsal (fracture into the proximal fourth and fifth metatarsal joint).
  - High incidence of nonunion.
  - **Treatment:**
    - Conservative: Short leg cast, non–weight bearing for 6–8 weeks; 12% require late surgery.
    - Athlete: Percutaneous screw fixations; faster healing and return of function.

MTP Joint Dislocation

- Relatively uncommon injury pattern.
- Dorsal is most common.
- First MTP > lesser toes.
- **Treatment:** Closed reduction and short leg walking cast or hard sole postop shoe.

"Turf Toe"

- Hyperextension injury of first MTP.
- Plantar plate injury.
- May result in loss of motion.
- **Treatment:** Conservative, taping.

Phalangeal Fracture

- Almost all phalangeal fractures are best treated nonoperatively.
- **Treatment:** Buddy taping, weight bearing as tolerated, ROM exercises.
- Surgery is occasionally indicated for intra-articular fractures of the hallux.
- Conservative treatment for intra-articular fractures of lesser toes.

Compartment Syndrome of the Foot

- Crushing, high-energy trauma.
- Associated with:
  - Multiple metatarsal fractures.
  - Lisfranc injuries.
  - Calcaneal fractures.
- Diagnosis
  - High clinical suspicion.
  - Compartment pressure measurements.
- Compartments of foot (9).
- Medial, superficial central, deep central, lateral, interossei (4), adductor.
- Treatment:
  - Surgical fasciotomy.
  - Two dorsal incisions +/– medial incision.
  - Late sequela of missed compartment syndrome: *Claw toes.*

NOTES

CHAPTER 4

Joint Arthroplasty

Total Hip Replacement 75
- Biologic Fixation 75
- Cement Fixation 75
- Techniques 75
- Stress Shielding 76
- Developmental Dysplasia of the Hip (DDH) 76
- Revision THA 76
- Hip/Pelvis Osteotomy 77
- Arthrodesis 79
- Dislocation in THA 79
- Femoral Periprosthetic Fracture 81
- Acetabular Periprosthetic Fracture 82
- Osteolysis 82
- THA Wear 82
- Search for Ideal Bearing Surface 83
- Hip Loosening 84
- Avascular Necrosis (AVN) 85
- Hip Arthroscopy 85
- Miscellaneous 86

Total Knee Arthroplasty (TKA) 86
- Surgical Technique 88
- Prosthetic Design and Positioning 88
- Component Positioning 88
- Wear 89
- PF Articulation 90
- Valgus Knee 91
- Varus Knee 91
- Bilateral TKA 91
- Unicompartmental Knee Arthroplasty (UKA) 91
- Revision TKA 91
- Periprosthetic Fracture 91
- Knee Osteotomy 92
- Arthrodesis 93

Miscellaneous TKA 95
Ligament Balancing 95
Shoulder Arthroplasty 96
Technique 96
Prosthetic Design 97
Hemiarthroplasty 97
TSA 99
Arthrodesis 99
Miscellaneous Reconstruction Topics 99
Infection 99
Heterotopic Ossification (HO) 100
Wear 101
Component Fixation 101
Biomechanics 101
Hematology 102
Cartilage 102
Definitions 102
Associations 102
Anatomy 102
Fat Emboli Syndrome 103
Miscellaneous 103

Biologic Fixation

- In-growth:
  - Must have rigid fixation and cortical contact.
  - Pore size and pore depth: 50–300 microns.
  - Surface area (porosity): If too porous will shear off, optimum is 40%–50%.
  - Gaps < 50 microns between prosthesis and bone.
  - Rigid fixation is required.
  - Motion > 150 microns gets fibrous in-growth.
  - Prefer micromotion < 50 microns.
- **On-growth:** Grit blast: Bone on-growth gets divets in metal, and bone grows on to the divets.
- Press-fit total hip arthroplasty (THA) femur: Circumferential proximal porous coating and rigid initial fixation are key elements.

In-growth and on-growth technology depends heavily on exact manufacturing specifications (thickness) as well as surgical technique.

Cement Fixation

- The cementing technique is outlined in Table 4-1.
- Cement is a grout with limited remodeling potential.
- Cement resists compression much better than tension.
  - Monomer strength variable: Can vary due to temperature, heat, humidity, pressure, etc.
- THA cement mantle: Keep > 2 mm (more cement mantle fractures if < **2-mm mantle**).
- Cemented cups fail at a higher rate than cemented stems because of higher shear and tension forces.
- Prior *pelvic irradiation:* Use a cemented cup or risk early loosening (Figure 4-1).
- Cemented femoral stems: Poor results if varus stem position, poor cement mantle, nonrounded stems (sharp corners), stovepipe bone (Dorr C).
- **Mantle defects** are associated with increased loosening (stem touching cortical bone is bad).
- **Stem breakage:** Cantilever bending; more with cemented varieties because smaller stems (r^4).
- Fatigue failure of prosthetic femoral stem is associated with stable stem fixation distally.

Cement fixation is a grout with limited remodeling potential. Irradiated areas of the body will have limited ability for in-growth, and cement is preferred (e.g., irradiated pelvis and need for cemented acetabular components).

TABLE 4-1. Cementing Technique

First generation	Finger packing, no plugs, no canal preparation.
Second generation	Medullary plug, cement gun, retrograde filling, canal lavage.
Third generation	Porosity reduction, centrifugation (vacuum mixing), centralizer, pressurize cement, surface modifications of femoral components (no titanium stems).

FIGURE 4-1. Bilateral THA with cemented cups and stems. Use was due to the patient's prior pelvic irradiation.

Techniques

- Press-fit:
  - Can cause fracture due to underreaming.
  - Compression hoop stresses are responsible for initial stability.
  - Long-term stability is biologic fixation.
  - Surface coating of hydroxyapatite: Osteoconductive only; optimum thickness is *50 microns.*

DDH (or congenital dysplasia of the hip [CDH]) hips have lengthening concerns for nerve injury as well as component placement concerns. Cup position should return to anatomic location, and stem version will be significantly different than the disease state.

Stress Shielding

- Proximal location with large diameter, extensively porous, coated, uncemented stems:
  - Amount is due to implant rigidity (stiffness).
  - Greater stiffness will have greater stress shielding.
- Collared stems can decrease proximal stress shielding by ~10%.
- More preoperative osteopenia will worsen stress shielding.
- Usually progresses for 1–2 years and then stabilizes without treatment.

Developmental Dysplasia of the Hip (DDH)

- DDH THA planning: Goal is anatomic cup location (medialize, can leave 20% uncovered); desire maximum host bone coverage but place cup anatomically.
- Lengthen no more than 5 cm (usually no more than 3.5 cm).
- If lengthening is necessary, then no block and keep knee flexed with hip extended to relax sciatic nerve and slowly straighten leg while patient is alert and cooperative (over days).

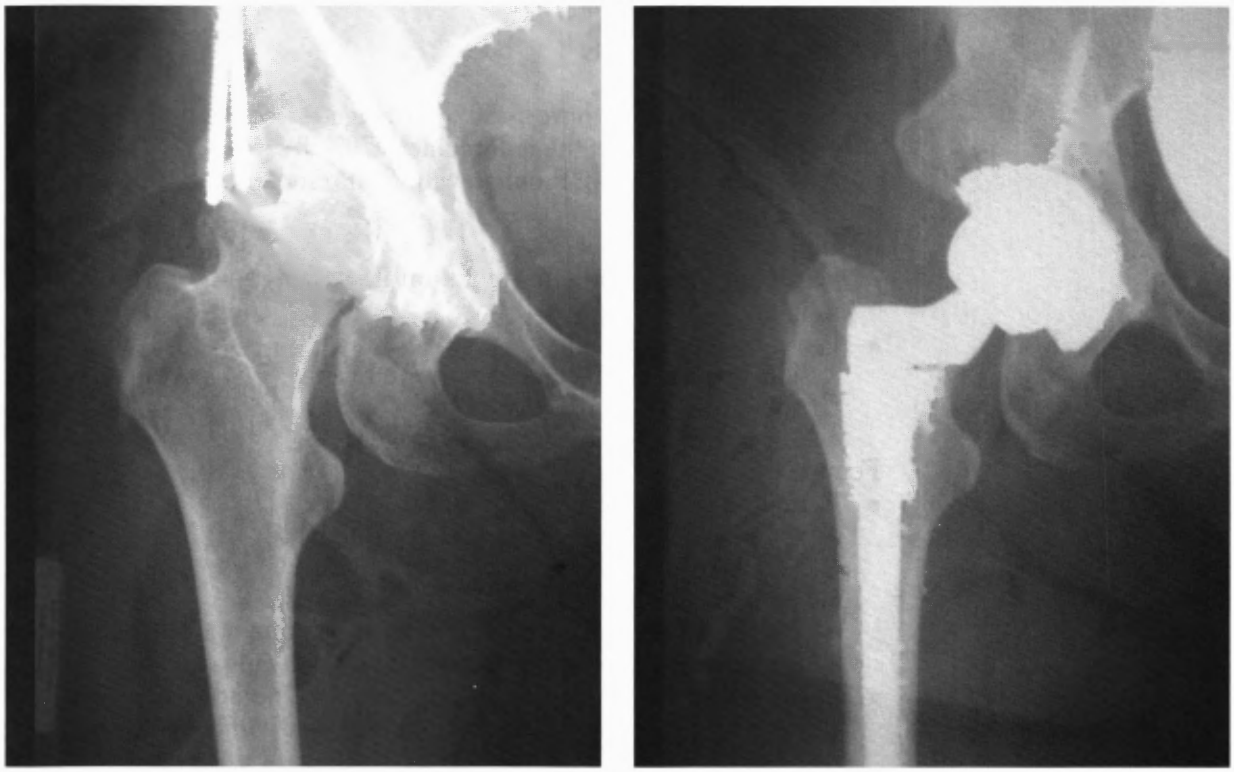

A B

FIGURE 4-2. **(A)** DDH hip with previous osteotomy followed by **(B)** THA with the modular system. Treatment of choice was due to the patient's altered socket and femoral anatomy.

- Alternative is femoral shortening osteotomy.
- 13% nerve injury (none in those lengthened < 4 cm).
- Femurs can have excessive anteversion (a modular stem may be necessary).
- **Dislocated vs. subluxed DDH:** More revision chance and nerve palsy with dislocation (Figure 4-2).

Revision THA

- Risk factors:
  - Obesity.
  - Steroids, systemic or local pulmonary.
  - Smokers >> nonsmokers.
  - EtOH elevates dislocation risk.
- Bone graft (allograft):
  - In osteoarticular allograft failure, the most common complication is *graft collapse* during revascularization.
  - Femoral head allograft is not preferred for the proximal femur due to inability to match femoral head to cup size, yet better abduction is possible.
- Bone defects:
  - Segmental
  - Cavitary
  - Combined deficiency
  - Malalignment

- Stenosis
- Femoral discontinuity
- **Acetabulum:**
  - Host bone needs to have > 50% coverage for cementless cup in revision THA; otherwise, the failure rate is 70% at 5 years.
  - Acetabular bone graft: Problem with graft resorption and/or collapse.
  - Use a ring or cage.
  - Can cement in cup.
  - Can even use jumbo cup (tantalum if needed) and cage and cement in liner.
  - Pelvic discontinuity:
    - Use a cage with cemented polyethylene (PE) cup or cemented shell, then place PE.
    - Large cup +/– cemented liner (Figure 4-3).
- **Femur:**
  - **Extended trochanteric osteotomy:**
    - Efficient for removing well-fixed femoral implants and distal cement plugs.
    - Keeps vastus lateralis blood supply attached.
    - Reduces the torque that the femur can tolerate compared to an intact cortex (need partial weight-bearing during early rehab).
  - **Loose cemented stem:** Revise long stem and include cables and struts if needed. Bypass cortical defects in femur by *2 cortical diameters.*

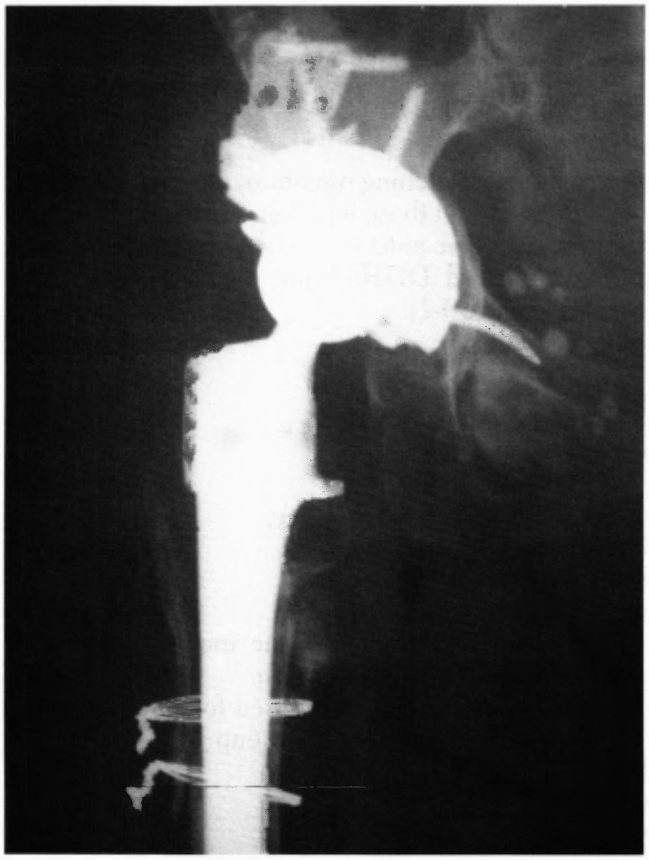

FIGURE 4-3. Revision THA. Note utilization of acetabular augments and calcar replacing fully porous-coated stem.

- **Impaction grafting:**
  - Impaction grafting with cement; the most common complication is subsidence (50%), yet loose only 5%.
  - Banks on early subsidence; the most common short-term complication is fracture (proximal > distal).
  - No difference in results vs. extensively coated stems, yet it is a difficult technique to master.
  - Postoperatively, get viable trabecular bone from incorporation and remodeling of allograft.
  - Greater fracture risk and subsidence.
  - Major benefit is the possibility of reconstituting bone stock.
  - **Negatives:** Fracture, perforation, cost (possibly).

Impaction grafting is a technical skill relying on early subsidence, yet risks early fracture.

Hip/Pelvis Osteotomy

- **Periacetabular osteotomy:**
  - Problem of anterior displacement of the joint (therefore limited flexion).
  - Treatment option for symptomatic acetabular dysplasia in young adults.
  - **Indications:**
    - Closed triradiate.
    - Minimal subluxation.
    - Joint congruity is essential.
  - **Contraindications:**
    - Open triradiate cartilage.
    - Advanced osteoarthritis (OA).
    - High subluxation or complete dislocation.
    - Different acetabular cup and femoral head sizes.
- **Dial or spherical osteotomy:** Leaves teardrop in original position and redirects acetabulum.
- **Chiari:** Salvage for noncongruent subluxed joint.
- **Pemberton:** Open triradiate cartilage required.
- Femoral osteotomy for hip dysplasia will help pain [not range of motion (ROM) or abductor strength].
- Varus intertrochanteric osteotomy: Increased abductor arm, decreased hip joint reactive forces; same center-edge angle.
- Developmental dysplasia: Periacetabular osteotomy if hip reduced, congruent, and no degenerative joint disease (DJD).

Arthrodesis

- **Hip fusion:** 25–30 degrees flexion, neutral abduction/adduction (or slight, 5–10 degrees, adduction, *no abduction*), slight (5–10 degrees) external rotation (ER).
- Low back pain associated risk of hip fusion (also, ipsilateral knee laxity, degeneration of contralateral hip).
- Hip fusion takedown *can alleviate low back pain.*
- Hip fusion converted to THA: Walking ability depends on abductor function.
- Hip fusion and contralateral THA: Total hip side has 40% more mechanical failure and loosening. Consider anterior approach to THA if contralateral arthrodesis, as this can help minimize dislocation risk when sitting.
- Use caution in patient with osteonecrosis since this is usually a bilateral problem.

Hip fusion takedown can alleviate preoperative low back pain, but overall improvement will depend on abductor function.

Complications

- **Deep venous thrombosis** (DVT) is most common.
  - Occurs in 58% of unprotected patients and 20% of protected patients (with some sort of prophylaxis).
  - Fatal pulmonary embolus ~0.6% no matter what preventative measures are taken.
  - More bleeding risks with enoxaparin (Lovenox) and warfarin (Coumadin) than with aspirin, yet less DVT chance.
- **Infection** ~1%:
  - Suspect infection with THA if loose in short amount of time.
  - Infection risk elevated in diabetes mellitus (DM), systemic lupus erythematosus (SLE), sickle cell disease (SCD), and psoriatic arthritis.
  - THA aspirate > 25,000 equals infection (some now say > 2500, not thousand).
- **Nerve injury:**
  - THA postoperative peroneal nerve palsy is highest with hip dysplasia in women.
  - Femoral nerve palsy after THA—errant retractor placement or prolonged hip extension.
  - Sciatic nerve injury: Do not lengthen more than 6%; average length is 75 cm, thus keep lengthening < 4.0 cm.
- Nickel hypersensitivity exists; beware of this with implant selection. Use titanium or ceramic implants.
- THA cemented femoral component failure: Most common is *varus stem position*; less proximal medial and distal lateral.
- **Anterior approach** negatives include abductor lurch for 6 months and leg shortening.
- **Hardinge approach** (direct lateral): Postoperative limp is the most common complication.
- Cement pressurization of femoral component increases emboli.
- Ceramic femoral heads and skirted femoral necks have high catastrophic failure rates.
- Cementing of the femoral component has more often acute hypotension, hypoxemia, cardiac arrest, and sudden death.
- Acetabular fracture in THA is associated with an *underreamed cup*; refrain from underreaming > 2 mm.
- If posterior column is fractured and displaced, a recon plate or acetabular cage is required to reestablish pelvic continuity.
- THA cementless after radiotherapy (XRT)—loosening is a major problem.
- Calcar fracture during stem implant: Treat with calcar cable; patient bears full weight if stem is stable.

Acetublar screw anterior superior quadrant is the "Zone of Death," and one should avoid screw placement here. The posterior superior quadrant is the ideal location if screws are necessary.

Zone/Quadrant Risks

- **Posterior superior:** Superior gluteal nerve, artery, and vein; sciatic nerve. This is the *safest zone* for cup screws.
- **Posterior inferior:** Inferior gluteal nerve, artery, and vein; internal pudendal nerve, artery, and vein; sciatic nerve.
- **Anterior inferior:** Obturator nerve, artery, and vein.
- **Anterior superior:** External iliac artery and vein; femoral nerve. External iliac vessels are in anterior superior quadrant ("Zone of Death").

Dislocation in THA

- Dislocation < 5% accepted rate, female > male 2:1 (Figure 4-4).
- A revision THA in which only the poly liner was exchanged puts patients at higher risk for dislocation.
- An elderly patient undergoing THA for failed dynamic hip screw (DHS) has a very high dislocation rate. Most occur within the first month; recurrent dislocation is more likely if it occurs after 3 months.
- **Component design:** Head size, neck thickness, cup/neck modifications. Larger head in THA means greater excursion distance (ED = head diameter) and thus lower dislocation.
- Increasing **primary arc range** (thus improving stability):
  - Greater head size
  - Narrow neck
- **Head–neck ratio:** Large ball, narrow neck gives best ROM, less levering out.
- Abductor complex: Key to stability (gluteus medius and minimus).
- Low neck cut can lead to *trochanteric impingement.*
- THA posterior approach: Repair external rotators and capsule to improve dislocation rate. Though some say this repair fails by the time the patient reaches the recovery room, it remains the standard of care.
- Anterior hip dislocations have *more* femoral head impaction than posterior hip dislocations. Anterior approaches have lower dislocation rates and greater postoperative limp.

FIGURE 4-4. Dislocated THA.

Larger femoral heads will improve the functional range of motion and hopefully dislocation rates (i.e., the metal-on-metal 38-mm heads).

- THA: **Parkinson vs. OA**, equivalent aseptic loosening rates; higher dislocation and mortality with Parkinson.
- EtOH is associated with higher dislocation rates in THA patients.
- **Management:**
  - Trochanteric advancement for recurrent dislocations with well-positioned components.
  - Recurrent dislocations in THA via anterolateral approach could be due to too much cup anteversion.
  - Constrained liner option only if soft tissue cannot be tightened.
  - Spinal stenosis: Use larger head.
  - Last resorts: Constrained liners, convert to hemiarthroplasty, or girdlestone.
  - Risk of recurrent dislocation:
    - 40% if first dislocation < 5 weeks post op.
    - 60% if first dislocation > 5 weeks post op.
    - 75%–80% if more than one dislocation.
  - Revision for dislocation has highest failure rate of all revisions.

Femoral Periprosthetic Fracture

Vancouver Classification

- **Type A:** Trochanteric region; osteolysis is the most frequent reason.
- **Type B1:** Located around the stem or at the tip of a well-fixed stem.
  - **Type B2:** Located around or at the tip of a loose stem.
  - **Type B3:** Fracture with loose stem and proximal femur is comminuted or of poor quality.
- **Type C:** Fracture distal to the stem.
- **Treatment:**
  - Revise stem if loose or unstable due to fracture.
  - Use a cementless stem to achieve bone ingrowth (cement cannot be contained).
  - Otherwise, keep stem and use plates and/or struts as needed (Figure 4-5).
  - Bypass defect by at least 2 cortical diameters.
  - Strut grafts.
  - Cable plates.

Acetabular Periprosthetic Fracture

- Mainly due to underreaming.
- Ream to within 2 mm of cup size (0–1 mm if good bone).
- Allows for more impaction (press-fit).
- Consider screws if ream line-to-line.

Osteolysis

- **Loose THA** = start-up pain (groin = cup, thigh = stem), especially internal rotation (IR) is painful.
- Loose femoral component has macrophages around it.
- THA **effective joint space** and osteolysis (the border of everything metal).
- Check the psoas sheath for osteolytic debris carefully.
- Well-fixed acetabular cup with osteolysis around a screw: Treat with liner exchange and bone graft lesion (leave cup) through holes in cup and/or around the cup.

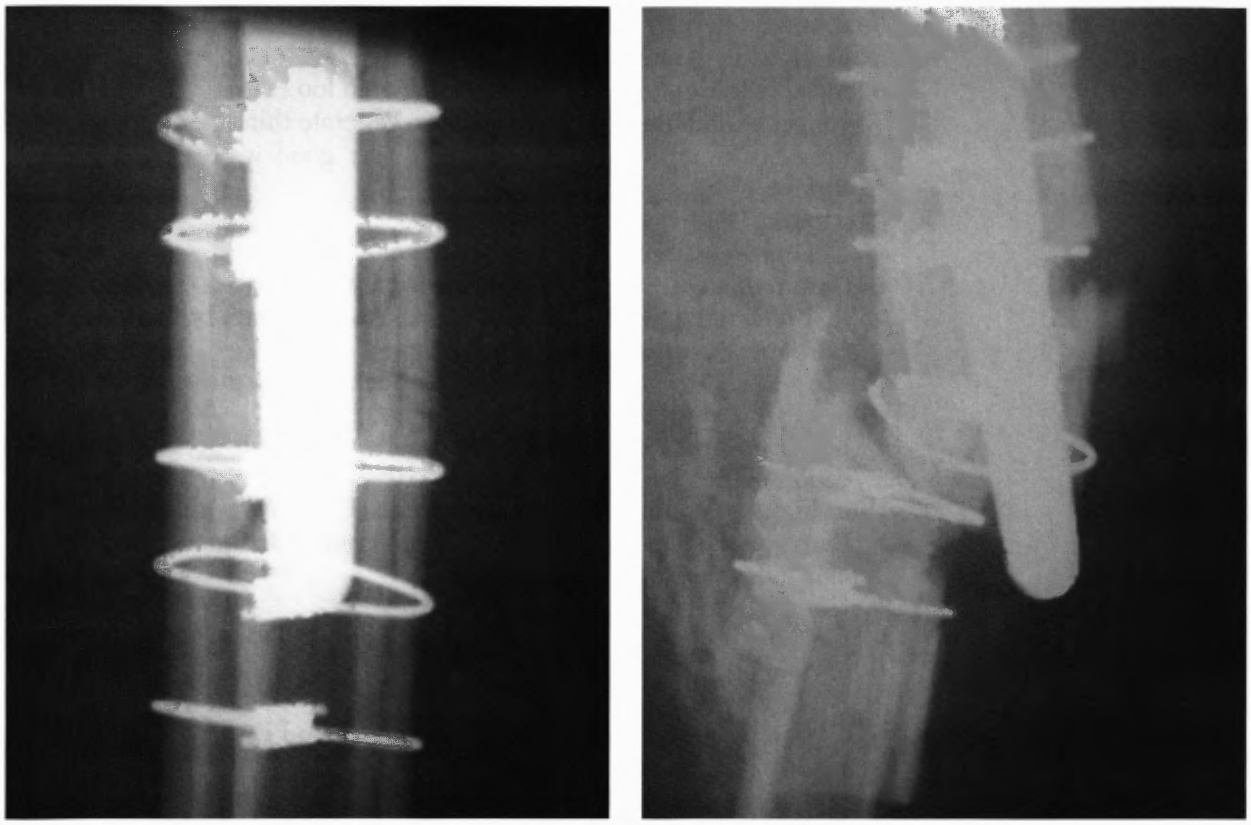

A B

FIGURE 4-5. **(A)** Revision femoral stem utilizing allografts and long-stem prosthesis. **(B)** Fracture through the allograft and cortical bone due to weight bearing too early.

- Consider preoperative computed tomography (CT) to evaluate extent of the bone loss.
- Order custom cages or have available revision devices if significant bone loss is possible.
- Threaded uncemented cups = higher loosening rates—*no longer recommended.*
- Noncircumferential porous coating increases distal femoral osteolysis via greater effective joint space.
- Diaphyseal osteolysis is common with noncircumferentially coated femoral components.
- THA extensive coating, cementless: Osteolytic fracture occurs most commonly at the greater trochanter.

Revision for osteolysis with a well-fixed cup requires screw removal and bone grafting the osteolytic areas after removing the entire osteolytic substance (check the psoas sheath carefully).

THA Wear

- Osteolysis depends on volume of particles; number of wear cycles more important than implant time (more active = more wear).
- Abrasive and adhesive wear:
  - Volumetric wear after open reduction (OR) that lowers with time.
  - Volumetric wear: Radius squared.
  - Screws with cups increase backside wear.
- THA 0.1 mm/yr wear rate is the current industry standard.
- High risk when wear > 0.2 mm/yr.

- Titanium on poly in THA (vs. cobalt chrome): Surface hardness is less.
  - More easily scratched and thus more wear debris and loosening.
  - Avoid titanium heads—too soft and scratch too easily.
  - No cemented titanium stems either—generate third body particles.
  - Press-fit titanium stems are actually very good with a porous-coated surface.
- **Ceramics:**
  - Ceramic–ceramic THA offers fewer neck length options.
  - Ceramics are the best coefficient of friction in hip data.
  - Risk of ceramic component fracture due to material's brittleness.
  - Case reports of "squeaky" ceramic hips.
  - Most likely due to impingement of neck on cup during swing phase of gait.
  - Seen on fluoroscopic studies, and the "squeak" may occur during relocation of the head into the cup.
- **Ultra-high-molecular-weight polyethylene (UHMWPE):**
  - Ram bar extrusion with machining. Machining has potential to worsen wear rates via surface delamination.
  - Hot isostatic pressing.
  - *Compression molding*:
    - Direct compression molding, no machining (best wear rates; see Table 4-2 and Figure 4-6).
    - See Biomet's AGC TKA system and Arcom PE.
  - Highly cross-linked: Better wear rates yet lower mechanical properties—reduced Young's modulus, yield strength, fracture toughness, fatigue crack resistance.
  - Acetabular cups: Every 1-mm decrease in thickness of metal-backed PE cups, gets 25% increase in wear.
  - Zone 1, Gruen: At greater trochanter is place of first site of osteolysis.
  - Zone 3 in the DeLee acetabulum is most common.

Search for Ideal Bearing Surface

There is a continuous give-and-take in the biomaterials forum as the perfect bearing surface is yet to be employed.

- Continuous give-and-take in search for perfect bearing surface.
- Metal on metal has less osteolysis, larger heads for better ROM and less dislocation, yet risk of metal ions is unknown.
- Metal ions are smaller, more numerous, and excreted by the kidneys.
- Metal ion concentration highest at 12–24 months.
- Cancer has not been linked to metal ions from arthroplasty.
- Ceramics have the better wear rates yet limited modularity and catastrophic fracture risk and squeaking.
- Cobalt-chrome on PE has excellent modularity but risk of osteolysis and dislocation.
- Titanium on PE has worse wear.

TABLE 4-2. THA: Wear Rates

Ceramic on ceramic	0.5–2.5 μm/yr (made of alumina)
Metal on metal	2.5–5.0 μm/yr
Poly on metal	75–250 μm/yr

FIGURE 4-6. THA PE wear of the socket as visualized on the radiograph by the superior migration of the femoral head. Also note the vertical orientation of the acetabular prosthesis, which will heighten the stress on the PE and increase wear potential.

Hip Loosening

- THA cemented with midstem fracture: Due to loosening (infection 16% simultaneous).
- **Hip loosening:** Can diagnose via serial x-ray; subsidence, pedestal.
- **Calcar hypertrophy** below an extensively porous-coated femoral stem means loosening.

Avascular Necrosis (AVN)

- **MRI** has the highest sensitivity and specificity for AVN of the femoral head.
- Anterolateral region of head (in nontraumatic cases) is the most common site of disease.
- Once collapsed, THA, not core decompression, should be done (some may attempt a free-fibula transfer).
- AVN and degenerative changes to acetabulum: Do THA.
- AVN rate is low (< 2%) after an elective hip dislocation for relief of femoral–acetabular impingement.
- Free vascularized fibula: The most common complication is donor site morbidity—*sensory deficit* (12%), motor weakness (2.7%), flexor hallucis longus (FHL) contracture (2%), DVT (1%).
- AVN is associated with human immunodeficiency virus (HIV) and protease inhibitors.

Free fibula transfer is an excellent alternative technique for treating AVN in the young patient, but has mixed results outside of the developing center's realm.

Hip Arthroscopy

- Hip scope, anterior portal: Risk injury to *lateral femoral cutaneous nerve* medial branch.
- Torn labrum: Pain and click with hip flexion, adduction, and IR.

Miscellaneous

- Templating (Figure 4-7):
  - Preoperative templating enables the surgeon to have necessary components available.
  - Also enables surgeon to have intraoperative steps thought out before the surgery.
- Trauma:
  - THA after OR and internal fixation (ORIF) of acetabular fracture: Failure most often due to acetabular loosening.
  - Previous acetabular fracture treated with ORIF = less need for bone graft with THA, yet more bleeding, instability, longer procedure.
  - Elderly with preexisting DJD hip and intertrochanteric fracture: Do a THA.
  - Femoral neck fracture in a young patient: ORIF, can accept 10 degrees of posterior angulation and 15 degrees of valgus.
  - Hip fracture: Increased risk if increased trunk muscle activity (relaxed fall is safer); fall to side.
  - Spontaneous hip fracture occurs in 25% due to increased hip muscle activity.
  - If a femoral neck fracture heals in 90 degrees of varus, do Pauwel's intertrochanteric valgus osteotomy.
  - Traumatic hip dislocations: 5%–10% cannot be reduced closed.
- **Rheumatoid arthritis** (**RA**) acetabular protrusion: Place cup in normal position (move center to anterior and inferior) as disease moves center posteromedial.
  - RA patients with THA have lower functional results than those with OA, yet better patient satisfaction.

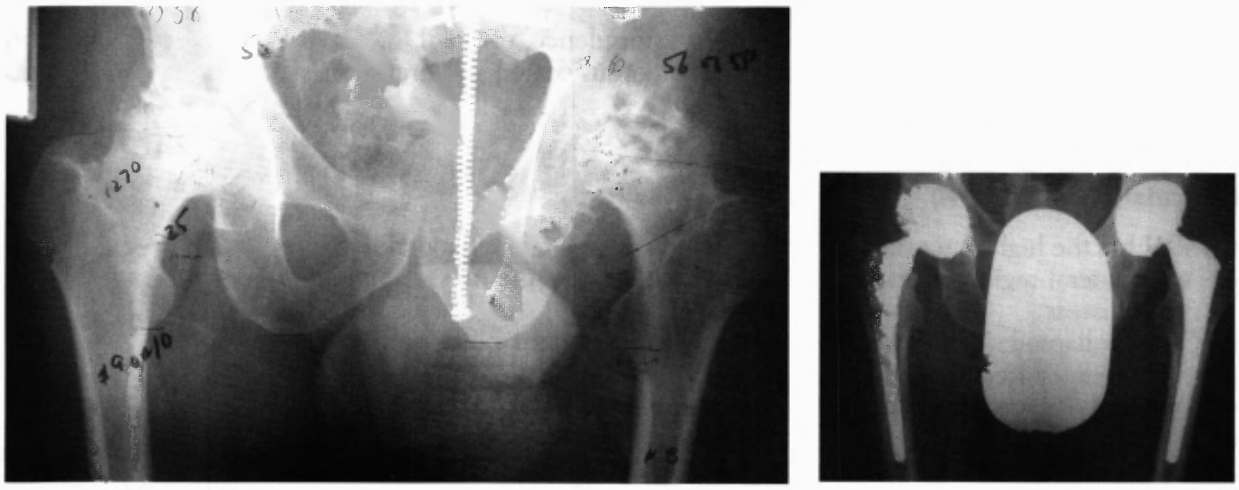

A B

FIGURE 4-7. **(A)** Preoperative templating for THA. Stem and cup orientation and size are marked in addition to neck cut. Ideal cup position is 45 degrees abduction, and stems need to have equal leg lengths postoperatively. **(B)** Metal-on-metal postoperative radiographs revealing acceptable component position and leg lengths.

- RA with acetabular protrusion: Use cancellous autograft with cementless acetabular component.
- **Idiopathic transient osteoporosis of the hip (ITOH):**
  - Transient osteoporosis: *Women, third trimester; men fifth decade.*
  - MRI: *Diffuse* signal changes throughout the femoral head and neck (osteonecrosis has *segmental* changes in the head).
  - Treat with activity modification, weight-bearing restrictions, and time (some say calcitonin helps with pain).
- **Sickle cell** patients have more loosening (and infection) after THA. Recommend porous-coated components with SCD in THA.
- Thrombosis (as indicated by elevated markers of thrombotic generation and fibrin formation) initiated at time of femoral canal preparation.
- Hip OA loses IR first (groin pain with hip IR is pathopneumonic).
- **Faux profile view:** Assesses anterior coverage.
- Periacetabular bone mineral density loss in first 2 years after noncemented cup is from altered stress patterns.
- **Abductor lurch** (limp) after THA: Treat with abductor strengthening.
- Highest risk of HO: Anterolateral and direct lateral approaches. Treat with Indocin or 700 Gy radiation (single dose).
- THA and normal baseline hemoglobin: No need for blood donation.
- E-poetin only for patients with preop hemoglobin (Hgb) below 10–12.
- More offset: Fewer joint reactive forces, yet more torsion on the stem.
- If < 60 years old, use a cementless, porous-coated cup (current recommendation).
- Hip resurfacing: Major complication is notching of the femoral neck leading to femoral neck fracture (Figure 4-8).
- Paget: Wait until disease is quiescent, then do THA. Do not cement components.

Hip approaches show anterolateral with less dislocation yet more limp, and posterior with less limp but greater dislocation risk.

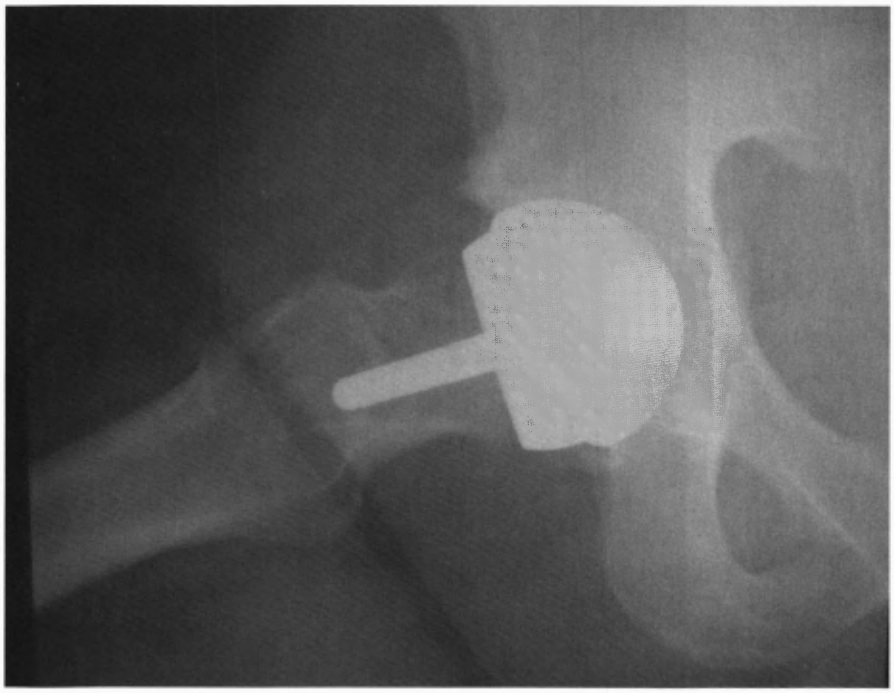

FIGURE 4-8. It is critical to avoid notching the femoral neck during hip resurfacing. Notching is associated with femoral neck fracture.

Surgical Technique

- Goal is to restore *mechanical alignment.*
- **Femoral cut:** Valgus cut angle: Anatomic axis of the femur (AAF)–mechanical axis of the femur (MAF) (distal femoral cut is perpendicular to MAF). Normal 6-degree valgus cut (short patient needs more, tall patient needs less).
- **Tibial cut:** Bisect tibial canal. Cut perpendicular to mechanical axis of the tibia (MAT) (MAT and anatomic axis of the tibia [AAT] are usually coincident in tibia).
- Anterior tibial slope diminishes knee flexion:
  - Knee flexion requirements: 67 degrees to walk, 83 degrees to ascend stairs, 90 degrees to descend stairs.
  - 5 degrees of anterior tilt to tibial component in TKA that has 0–60 degrees ROM. There is often a need to revise the tibia.
- Maximum joint line should be raised or lowered is 8 mm.
- Lateral release puts patellar blood supply at risk, gets the *superior lateral geniculate* artery.
- Varus positioning increases rate of failure (Figure 4-9).

Prosthetic Design and Positioning

- Avoid a hinged prosthesis if at all possible (for test response).
- Constrained component: Use when medial collateral ligament (MCL) is stretched out, lateral collateral ligament (LCL) attenuation, and/or flexion gap laxity (i.e., use when knee is unstable).

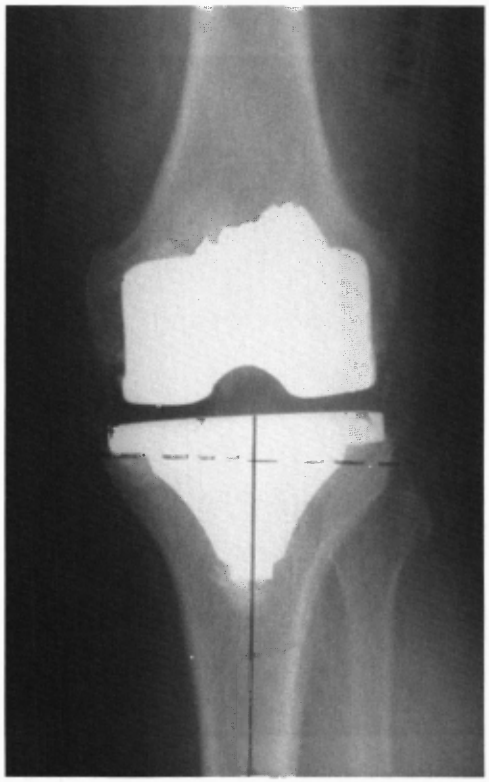

FIGURE 4-9. TKA with varus positioning setting up for early failure.

- The difference in radius of curvature of the native knee (LFC > MFC) causes the distal femur to pivot around the MFC as the knee goes from extension to flexion.
- Cruciate-retaining (CR) systems:
  - Paradoxical anterior femoral translation and lateral liftoff (less rollback than with posterior stabilized [PS] TKA).
  - Does not improve proprioception.
  - Posterior cruciate ligament (PCL) sparing is often preferred if hyperflexion is needed.
- Cruciate-sacrificing (PS) systems:
  - PS TKA for patellectomy patient. Prior patellectomy necessitates a PS TKA.
  - Better formal rollback with PS TKA.
  - For true rollback, anterior cruciate ligament (ACL) and PCL must be linked.
- CR knees actually have *sliding* instead of rolling.
  - PS more closely reproduces normal joint kinematics (some say).
  - Better overall ROM.
  - Equivalent stair testing with PS and CR TKA.
- Press-fit TKA vs. cemented TKA:
  - Cemented designs have less osteolysis overall.
  - Cementless tibial fixation has been more difficult than on the femoral side.
  - Future seems to be press-fit, but data is still early.
- Poly design:
  - Increased conformity TKA: Lower peak contact stresses and lower wear rates.
  - Conformed mediolateral articular surface in TKA has a favorable impact on wear.
  - More constraint, limits motion, and more stress at knee–cement interface.
  - Metal-backed tibial component in TKA decreases compressive stress on underlying cancellous bone.
  - Monolithic metal-backed tibial components lessen backside wear, thus less osteolysis. Compression-molded systems seem to have best wear characteristics.
  - Minimal poly thickness in TKA 6–8 mm (UHMWPE). Some advocate 4-mm poly if compression-molded, anatomic-graduated, nonmodular components are used.
  - A mobile-bearing TKA has no improved survivorship over static-bearing TKA.

Component Positioning

- Avoid IR of tibia or femoral components—this causes lateral subluxation of the patella.
- IR tibial component leads to relative ER of the tibial tubercle and greater Q-angle and thus poor patellar-femoral tracking.
- Do not place femoral component medially.
- Consider lateralizing femoral component in PS knee (slight decrease in Q-angle with this position).
- Elevation of joint line may limit knee flexion in TKA.
- A PS knee should not be loose in flexion; this can allow the cam to jump the post, dislocating the knee.

IR of the femoral and tibial components in TKA must be avoided to prevent patellar maltracking.

- Consider medializing the patella component (keeps Q-angle low).
- Smaller button has less lateral release need.
- Too thick (patella height) tightens lateral patellofemoral (PF) ligament and thus pulls patella laterally. Small patella dome placed superiorly can be helpful (effectively elevates joint line).
- Patellar clunk in PS knees only: At 30 degrees of flexion, as standing, patient feels a snap. Treat with debridement.
- Lateral release increases the occurrence of patella osteonecrosis and patella component failure.

Wear

- Large-particle wear in TKA is a macroscopic problem.
- THA has smaller particles and increased macrophage response.
- Direct-compression molding gives best wear in TKA.
- Wear in TKA: Subsurface delamination and fatigue cracking with pitting.
- Minimal wear with monoblock compression-molded systems.
- PE sterilized with gamma irradiation in air causes oxidation and decreases wear performance.
- Higher conforming polyethylent inserts reduce contact stress on the poly.
- PS TKA systems can have rotational impingement wear to the PE *post*.
- Press-fit TKA *osteolysis*: 30% chance of osteolysis if press-fit both components, 10% if cement tibia and press-fit femur, 0% if both are cement.
- Always think of infection if there are radiolucent areas on TKA radiographs (see Figure 4-10).

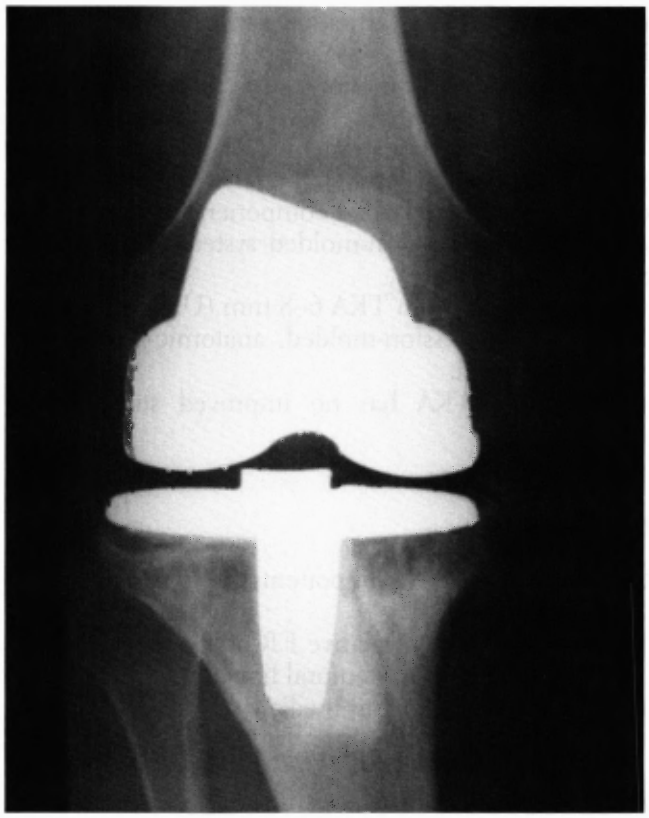

FIGURE 4-10. TKA osteolysis as seen on radiograph by the radiolucent areas below the tibial tray.

PF Articulation

- Deep, curved anatomic femoral trochlear groove has lowest contact stresses.
- PF problems are the most common cause for reoperation. Patella thickness < 12 mm increases risk of stress fracture.
- Patellar instability: Valgus malalignment, IR of femur or tibia, medial femoral component, no lateral release.

PF complications are the number one reason for poor TKA outcomes.

Valgus Knee

- Peroneal nerve palsy occurs in ~3%.
- Valgus TKA with postoperative neurologic changes necessitates dressing removal and knee flexion.
- Epidural is a risk factor for postoperative peroneal nerve palsy in valgus TKA patients.
- MCL advancement is a surgical option.
- Cause often to lateral femoral condyle hypoplasia.

Varus Knee

- Tight medial structures: Be prepared for incompetent MCL by having a CCK device around.
- *Avoid varus*—failure rate of the TKA is 168 times higher if placed in as little as 3 degrees of varus.

Varus in TKA has 168 times failure rate (as little as 3 degrees).

Bilateral TKA

- Bilateral TKA patients have a higher 30-day mortality rate.
- Congestive heart failure (CHF) is more common in 80-year-olds who have bilateral TKA vs. single TKA.
- Acute delirium is more common in the bilateral group.

Unicompartmental Knee Arthroplasty (UKA)

- **Indications** (these indications are constantly being pushed and altered):
  - > 60 years old
  - Sedentary
  - Unicompartmental OA
  - > 90-degree preoperative flexion
  - < 15-degree flexion contracture
  - < 5-degree fixed varus deformity
  - Competent ACL
- The main concern of revision of a UKA to a TKA is bone loss.
- Oxford mobile-bearing medial compartment UKAs have 98% success at 10 years with proper positioning.
- Complications can include medial tibial plateau failure and other compartment decompensation (Figure 4-11).

Revision TKA

- The most common reason to reoperate is patella problems (8%–35%).
- Infection, 1%–2%; joint instability, 6%.

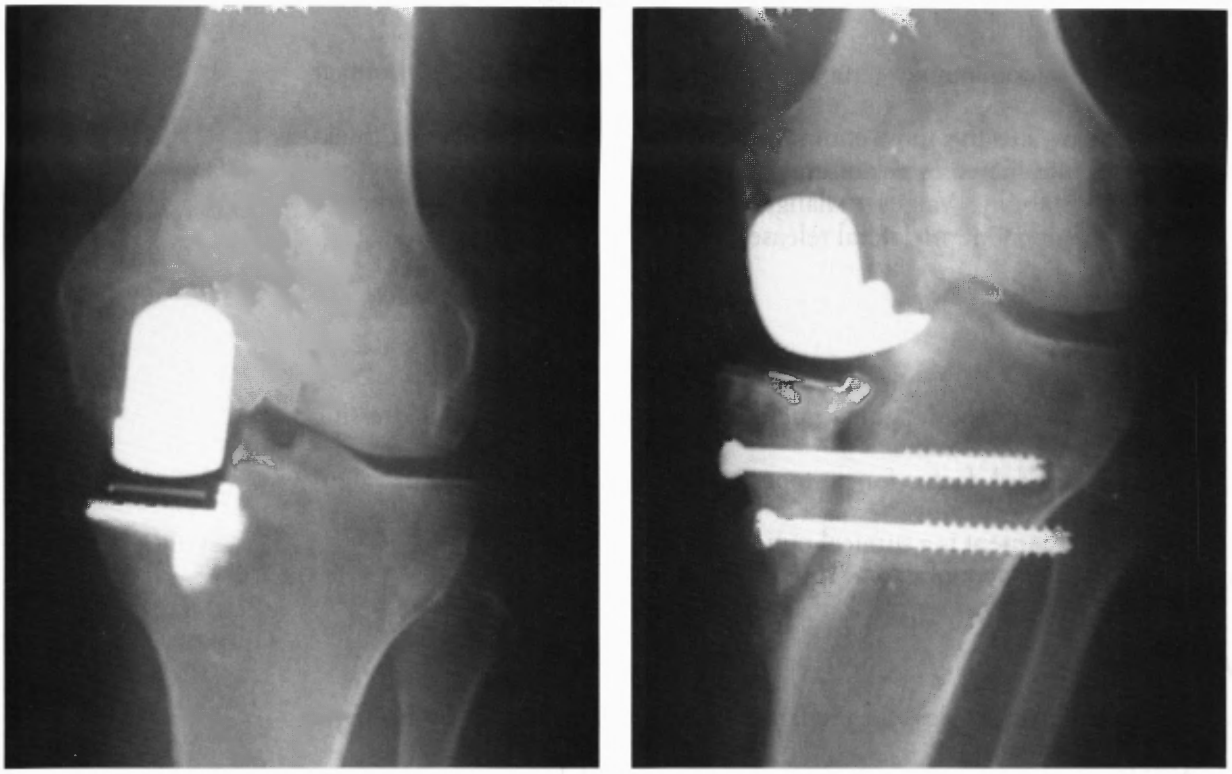

A B

FIGURE 4-11. Medial compartment unicompartmental knee arthroplasty. **(A)** Good implant position of Oxford mobile-bearing system. **(B)** Another film showing failed ORIF of medial tibial plateau fracture below UKA. The subsequent TKA was a much more difficult procedure requiring augments and stems.

- Includes patellar instability, fracture, loosening, surface erosion, and pain.
- Factors with lower failure rates: Primary TKA, RA, > 60 years old, and metal-backed tibia with condylar prosthesis.
- **Cementless TKA** (see Figure 4-12): The most frequent late complication is osteolysis (~30%).
- If patella ≤ 10-mm bone thickness, then do *not* place a component.
- **Abnormal joint line problems:**
  - Elevated joint line: Patella baja, PF tracking problems, decreased knee scores.
  - Lowered joint line: Lack of full extension, flexion instability.

Periprosthetic Fracture

- Nondisplaced periprosthetic fracture of the patella: Treat with knee extension and immobilization.
- Femur fracture: Consider cast vs. flexible rods vs. ORIF (Less Invasive Stabilization System [LISS] plate vs. dynamic condylar screw [DCS], etc.) vs. intramedullary nails vs. revision prosthesis (tumor prosthesis if needed, hinged if needed) (Figure 4-13).
- Complex issue, but component stability and bone stock must be assessed.
- If prosthesis is loose, then revision system.

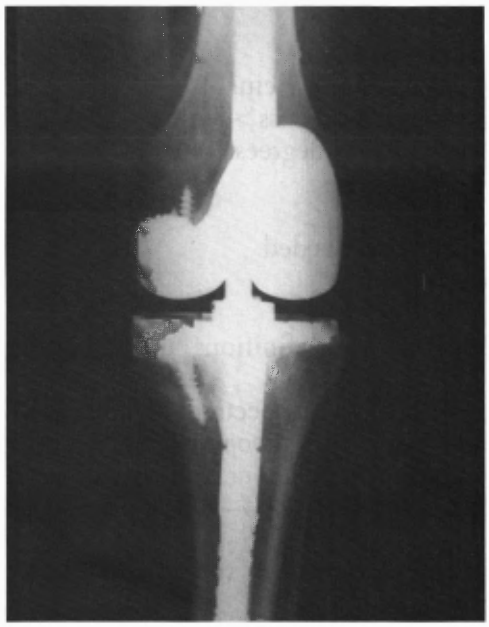

FIGURE 4-12. Revision TKA system necessitating stems and screw augmentation.

Knee Osteotomy

- Indications for high tibial osteotomy (HTO):
  - Young age.
  - Pain and disability in medial compartment only.
  - ≤ 15-degree varus.
  - ROM at least 90 degrees.
  - Flexion contracture < 15 degrees.
  - Motivated and compliant patient with good vascular status.

FIGURE 4-13. Supracondylar femur fracture above a TKA. This fracture was successfully treated with percutaneous screws and retrograde nail.

- Contraindications for HTO:
  - Narrow lateral compartment.
  - Lateral tibial subluxation > 1 cm.
  - Medial compartment bone loss > 3 mm.
  - Flexion contracture > 15 degrees.
  - Knee flexion < 90 degrees.
  - Inflammatory arthritis.
  - > 20-degree correction needed.
  - Ligament instability.
  - Advanced PF disease.
  - Obese patient (variable definitions, usually body mass index [BMI] > 35).
  - Varus thrust on visual gait inspection. HTO failure is common if there is varus (lateral tibial) thrust preoperatively.

HTO often does very well for 5–7 years and then the result declines precipitously.

- HTO is associated with patella infera.
- HTOs do well for 5 years (80%–90%), then good results taper off dramatically.
- Best results with overcorrection to valgus of 8–10 degrees and nonoverweight patients.
- If overweight and undercorrected, then 60% failure after 3 years.
- **TKA after HTO:** Patella baja, difficult exposure, and poor ROM.
- If tibial deficiency is large, then correct just below the tubercle (minimizes baja).
- Distal femoral varus osteotomy (lateral opening wedge) for young, large person with wicked valgus.
- HTO for valgus not good if valgus > 12 degrees.

Arthrodesis

- Ideal position 0–7 degrees valgus and 10–15 degrees of flexion.
- Convert fusion to TKA: < 50% good results (infection, 14%; total complication rate, 57%). Only 29% satisfactory outcome, must have extensor mechanism.
- Knee fusion is warranted if there is loss of extensor mechanism and instability or gram-negative infection.
- Knee external fixation pins need to be at least 14 mm from joint to minimize joint contamination and infection.

Complications

- Infection:
  - If intraoperative cultures show coagulase-negative *Staphylococcus* 2 days after surgery of TKA revision, keep components in and treat with antibiotics alone.
  - If C-reactive protein (CRP) and erythrocyte sedimentation rate (ESR) are negative, infection is unlikely.
  - An aspirate with an absolute leukocyte count of < 1700 with < 50% neutrophils in an uncompromised patient who has not taken antibiotics rules out infection.
  - Two-stage exchange is the gold standard but a single-stage exchange or liner exchange can be done depending on circumstances.
- Acute atherosclerotic plaque dislodgment: Consider this diagnosis in a pulseless limb after TKA.
- Well-fixed and aligned TKA with pain:
  - If no infection, then leave alone because pain relief success rate is only 40% with revision surgery for this reason.

- Tibial base plates with honeycomb back seem to have poor cement–plate interface and do well with revision.
- Medial overhang of the tibial plate has been associated with postoperative pain.
- Patellar tendon rupture in TKA is most devastating in that it is extremely difficult to regain knee extension.
- Patella fracture after TKA: If transverse, then cylindrical cast; if vertical, early motion.
- Reflex sympathetic dystrophy (RSD) following TKA:
  - Nonanatomic distribution of pain.
  - Trophic changes.
  - Treat with sympathetic block, oral medications, physical therapy (active-assist ROM).
- Obese patients have more wound complications (definition is variable but BMI > 35 is often seen).
- Stiffness after TKA:
  - Rule out infection.
  - Rehab early.
  - Manipulate by 6 weeks if needed.
  - Arthroscopic arthrolysis, open arthrolysis with poly exchange, and revision TKA gain little arc of motion and have poor outcomes.
  - Patient satisfaction is higher if knee extension is improved.

Painful TKA with no discernible cause has a 40% success rate at revision.

Rehabilitation

- Extensor lag (more passive than active knee extension) after TKA: Treat with physical therapy and quadriceps strengthening.
- Postoperative ROM = preoperative ROM +/– 10 degrees.
- Use of a CPM postoperatively may increase early ROM but it does not affect final ROM after TKA.
- Manipulation should be done around 6 weeks if needed.
- Manipulation under anesthesia for stiff TKA: Still get good results at 4 months postoperatively; can gain 30 degrees.

Preoperative ROM is the best indicator for postoperative ROM.

Miscellaneous TKA

- **AVN:** Elderly female with knee pain and relatively benign-appearing radiograph: MRI will show the true extent of the osteonecrotic lesion.
- Beware of **medial tibial stress syndrome**, which mimics AVN versus meniscal tear in clinical appearance, except for pain below the joint line on the proximal medial tibia. Treat with conservative measures first.
- High failure rates with heat-pressured UHMWPE used with porous-coated anatomic tibial inserts.
- UHMWPE TKA: This type of PE has decreased ductility and fatigue strength, yet better wear.
- Contraindication to TKA: No extensor mechanism.
- Paget disease and TKA: Obtain a 50% reduction in alkaline phosphatase before considering surgery.
- TKA and tourniquet use does not increase risk of pulmonary embolism.
- Screw augmentation with cement for bone defects has proven just as effective as more expensive prosthetic augments (Figure 4-14).

POLO: Pull Out (loose), Lift Off (tight).

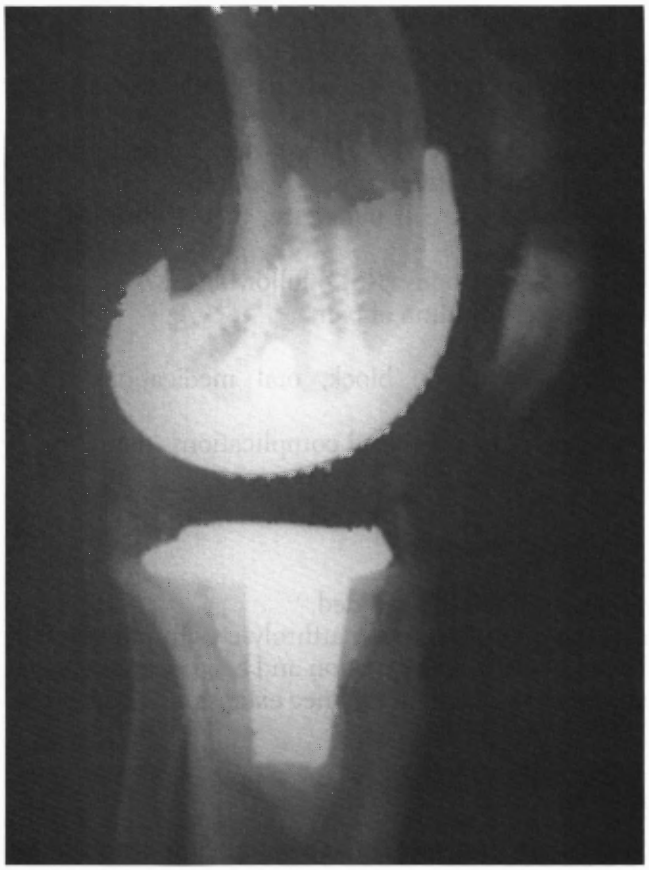

FIGURE 4-14. Standard 30–40 mm screws can be used as Rebar in cement to help fill bone defects both on the femoral and tibial side in primary and revision cases.

Ligament Balancing

Symmetric issue, work on tibia; otherwise, work on femur.

- *Main Principle 1*: Symmetric flexion and extension gaps, then work on tibia.
- *Main Principle 2*: Asymmetric flexion and extension gaps, then work on femur.
- Tight laterally in extension—iliotibial band (ITB) alter +/– posterior lateral capsule and adjust thickness of PE as needed.
- Tight laterally in flexion—popliteus alter +/– LCL and adjust thickness of poly as needed.
- Ligament balancing is the number one key for a long-term good result. A gap guide is shown in Table 4-3.

SHOULDER ARTHROPLASTY

Technique

Subscapularis avulsion is a major complication of shoulder arthroplasty.

- Humeral head cut should approximate the native cartilaginous surface.
- Place stem in retroversion, ideally 30 degrees.
- If placing glenoid component, assess preoperative version (CT if needed) (Figure 4-15).
- Repair subscapularis tendon: Bone to bone, tendon to tendon, or tendon to bone.

TABLE 4-3. Ligament Balancing Gap Guide

Flexion good Extension good	Keep it a go!
Flexion tight Extension tight	Cut more tibia
Flexion loose Extension loose	Thicker poly
Flexion good Extension tight	Cut more distal femur Release posterior capsule
Flexion good Extension loose	Add distal femoral augments Smaller component (AP less), now symmetric problem and tibia thicker Thicker PE, now deal with tight flexion
Flexion loose Extension good	Larger femoral component (larger AP diameter) Posterior femoral augments or cement Thicker PE and now flexion good but extension tight, then cut more distal femur
Flexion tight Extension good	Recess and/or release PCL. Add more posterior slope to tibia Cut more posterior femur (go to smaller component)
Flexion tight Extension loose	Multistep
Flexion loose Extension tight	Multistep

AP, anteroposterior; PCL, posterior cruciate ligament; PE, polyethylene.

Prosthetic Design

- Cement vs. press-fit: Cemented total shoulder arthroplasty (TSA) has promising results.
  - Difficult revision as humeral bone stock is often attenuated.
  - Some prefer press-fit and claim excellent results.
- Hemi vs. total: The debate rages on, yet there are testable topics.

Hemiarthroplasty

Indications (vs. TSA)

- Concentric glenoid to contain humeral head:
  - Insufficient bone stock to support a glenoid component.
  - Obtain preoperative axillary lateral radiograph to assess glenoid stock (or CT scan).
- High-riding humerus due to cuff tear arthropathy (CTA):
  - Cuff integrity is most important predictor of outcome for shoulder hemi.

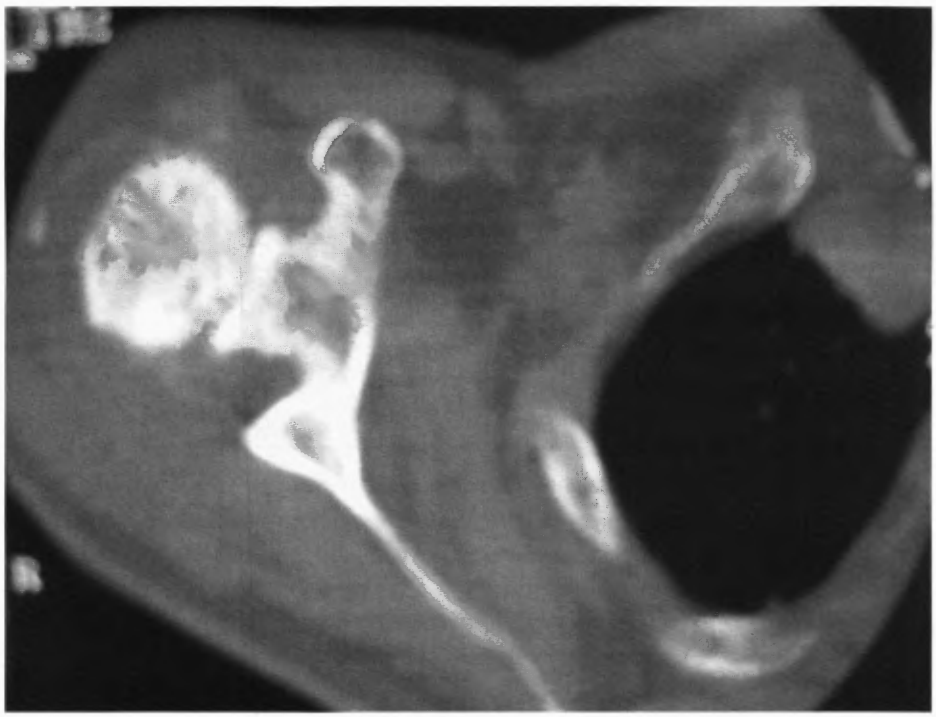

FIGURE 4-15. Preoperative CT scan assessing glenoid version.

- Possible CTA implant or reverse prosthesis (see Figure 4-16).
- Preserve the coracoacromial arch (CA ligament) or else the CTA hemi has no support.
- Rotator cuff tear can lead to glenoid failure if a TSA is done—"rocking horse" phenomenon.

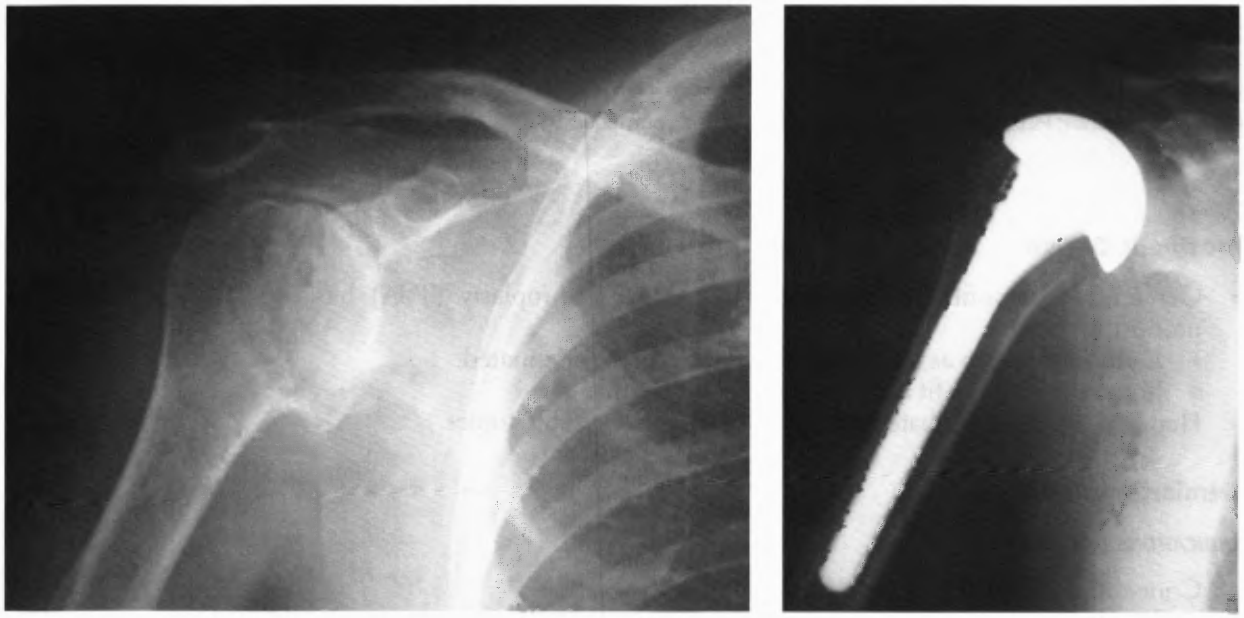

A B

FIGURE 4-16. **(A)** Preoperative radiograph revealing rotator cuff deficiency due to high-riding humeral head. **(B)** Postoperative radiograph of a CTA prosthesis showing the humeral CTA head articulating with the acromion. Save the CA ligament if at all possible.

- History of joint infection.
- Heavy demands.
- Three-, four-part proximal humerus fracture: Hemiarthroplasy in the elderly and ORIF in the young if possible.
- The most common complication is glenoid arthritis.

Rotator cuff–deficient shoulder with arthritis merits a hemiarthroplasty; consider CTA.

TSA

- Rheumatoid patients do better with TSA (in some series); must still assess bone stock and glenoid anatomy.
- The most common complication is glenoid loosening.

The most common complication in hemiarthroplasty is glenoid arthritis.

Rehabilitation

- Passive ROM initially and make sure elbow and hand do not get stiff.
- Delay active IR or extreme passive ER (protect subscapularis repair).

Revision TSA

- Options depend on bone stock and soft tissue envelope.
- Press-fit the humeral stem if possible.
- A glenoid component often cannot be used.
- Options: CTA, reverse prosthesis (constrained).

Shoulder fusion at 30-30-30 (30 degrees flexion, IR, and abduction).

Periprosthetic Fracture

- Similar protocol as with femoral stems.
- Plates, cables, struts, casting.

Complications

- Subscapularis rupture
- Recurrent dislocations

Arthrodesis

- Ideal position is 30 degrees abduction, 20 degrees forward flexion, 40 degrees IR.
- Some advocate the 30-30-30 rule (30 degrees for all positions).

► MISCELLANEOUS RECONSTRUCTION TOPICS

Infection

- Risk factors for infection in total joints:
  - Previous surgery (but not arthroscopy).
  - Immunocompromised patients (RA, DM, psoriasis, HIV).
  - Posttraumatic.
  - Use of highly constrained components.
- Early pain after total joint replacement: Infection must be ruled out.
  - Check white blood cell (WBC) count, ESR, CRP, then aspirate.
  - If CRP and ESR are negative, infection is unlikely.

CRP returns to normal value much quicker than ESR in the postoperative period.

Previous surgery at the site of arthroplasty is a significant risk factor for infection at the time of joint replacement.

- CRP is the best indicator of infection.
- Aspiration is most reliable to diagnose infection. Hip aspiration *false-positive* rate is 15%.
- Biofilm or *glycocalyx:* All bacteria make a biofilm.
- "C" wound: Do two-stage exchange.
- Periosteal new bone raises concern for infection.
- > 10 polymorphonuclear neutrophils (PMNs) is level for infection via intraoperative section.
- Transplant patients undergoing a joint replacement have an infection rate ~20% (due to immunosuppression).
- **Phemister triad** (tuberculosis arthritis): Juxta-articular osteoporosis, peripheral erosions, joint space narrowing.
- PROSTALAC for TKA and THA infections is a local antibiotic delivery system that maintains soft tissue tension while providing some functional ROM (see Figure 4-17).

Heterotopic Ossification (HO)

- Risk factors: Male, bilateral hypertrophic OA, ankylosing spondylitis, traumatic OA, prior hip fusion, diffuse idiopathic skeletal hyperostosis (DISH), Paget disease.
- HO prophylaxis:
  - Radiation: 700 rads, one dose, either pre- or postop (must be within 72 hours of surgery); shield noncemented components.

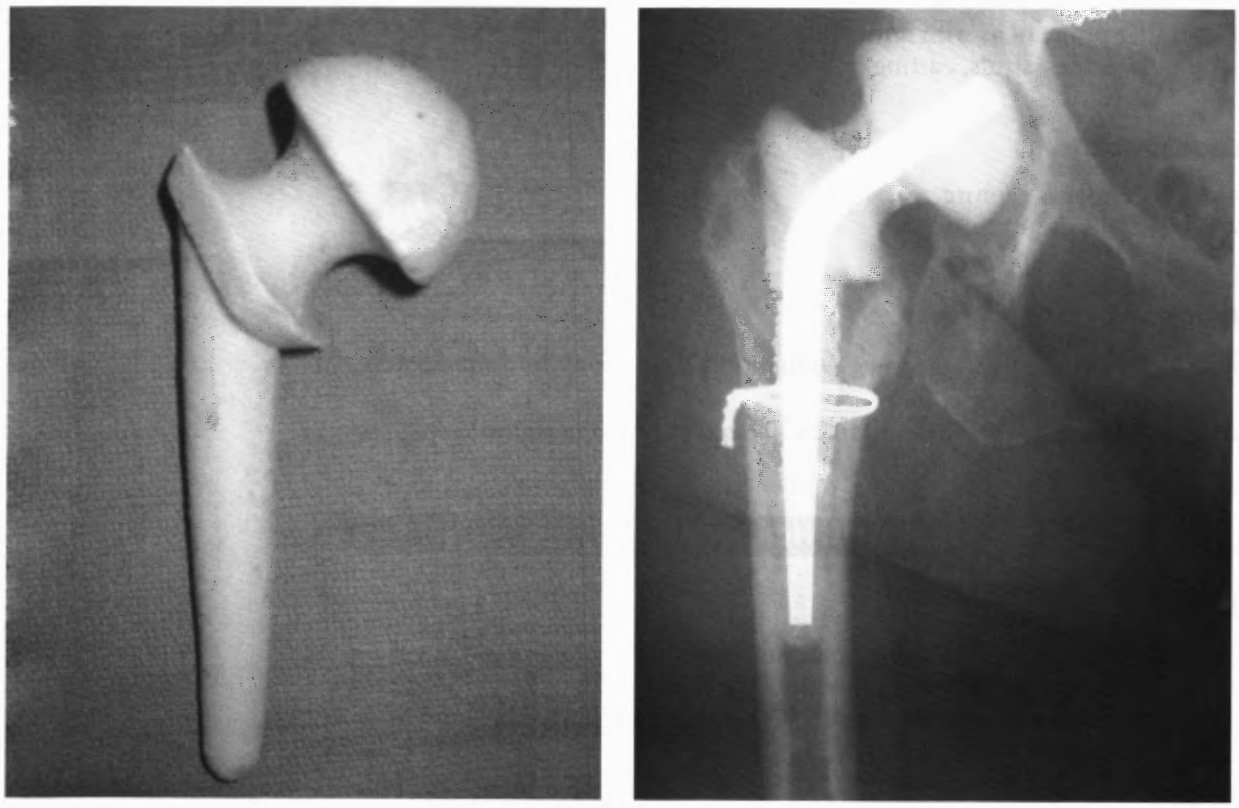

A B

FIGURE 4-17. **(A)** Prefabricated antibiotic and soft tissue temporary spacer clinical image at 6-week removal and **(B)** in situ radiograph.

- Indocin: 50 mg bid for 2 weeks or 75 mg qd for 2–6 weeks.
  - Variable duration recommendations—at least a week.
  - Take with gastrointestinal prophylaxis.
- Excise when mature (trend is to earlier excision).
- Ankylosing spondylitis:
  - HO is most common complication after THA.
  - 20%–60% without and 10% with treatment.
- Higher infection and HO rate than found for OA; also fewer good results long-term.

Wear

- **Mode 1:** Two intended surfaces (head and liner).
- **Mode 2:** Second surface, nonintended wear (head on shell).
- **Mode 3:** Primary surface and third body (bone chip, cement, metal fragment) → abrasion.
- **Mode 4:** Two secondary surfaces (cup–liner, shell–screw, stem–cement). Backside wear requires local osteolysis.
- Average wear rate for non–cross-linked UHMWPE is 0.1–0.2 mm/yr. Particle size for UHMWPE is < 1 μm; easily phagocytized by macrophages.
- PE wear is the same for constrained and unconstrained PEs.
- Sterilizing UHMWPE with radiation in an inert environment prevents immediate and shelf-life oxidative degradation. Gamma irradiation in air worsens PE oxidation degradation and produces fusion defects and a subsurface white band in UHMWPE.
- Metal on metal: Nonlinear wear rate, smaller particle size, < 0.6 mm^3 metallic debris per year; needs polar contact more than equatorial contact (or risk seizing).
- Alumina (ceramic) is hardest, most resistant to scratching.
- Highly cross-linked UHMWPE has *decreased* tensile strength and fatigue strength vs. UHMWPE.
- Osteolysis is affected by head size, implant design, third-body wear.
- Knee poly wear: Fatigue cracking and delamination stress are maximum just below the poly surface.
- Hip poly wear: Volumetric wear due to adhesion and abrasion; wear is at the surface of the poly.
- Volumetric wear increases with femoral head size.
- "Bedding-in" phenomenon: Wear rates decrease the longer they are in.

Gamma irradiation in air is a poor PE sterilization method manifested in subsurface delamination and early failure.

Component Fixation

- Precoated stems with polymethylmethacrylate (PMMA): Better bonding between stem and cement mantle; no difference in survival; more revisions possible.
- Bone in-growth: Pore size 100–400 μm, micromotion < 50 μm, need intimate bone-implant contact, circumferential porous coating (noncircumferential has less stability).

Biomechanics

- Elastic modulus: "**Cir** **Cob**y **S**tands **T**rial while **C**ourting **P**ending **P**unishment for **Cance**ling **T**eam **L**uncheons **C**ontinuously" (**C**eramic, **COB**alt, **S**tainless steel, **T**itanium, **C**orticalbone, **PMMA**, **PE**, **CANCEL**lous bone, **T**endon, **L**igament, **C**artilage) (greatest to least).
- Radius to the fourth power—bending rigidity.

Bending rigidity is calculated by radius to the fourth power.

Hematology

Preoperative Hgb is the most important factor in determining transfusion risk postoperatively; some advocate allowing Hgb levels of 7 in asymptomatic patients.

- Preoperative Hgb level is the most important factor regarding postoperative transfusion.
- Lower blood transfusion if preoperative erythropoietin is used.
- If transfusion risk is < 10%, then no preoperative autologous donation is required.
- Transfusions may increase infection risks due to currently undefined reasons.
- Anemia can cause elevated heart rate and cardiac output, as well as coronary blood flow requirement; lowered peripheral vascular resistance and blood viscosity.
- Low-molecular-weight heparin (LMWH): Same risk for DVT as warfarin (3.6% vs. 3.7%).
  - Principal action inhibits factor Xa (bind AT-III to factor Xa).
  - Thrombocytopenia is less common with LMWH than with unfractionated heparin.
  - Better bioavailability than heparin (thus improved efficacy).
- Heparin: Anticoagulation effect via interaction with AT-III. Conformation change accelerates ability to inactivate thrombin factor (II), factor IXa, and factor Xa.
- Warfarin inhibits posttranslation carboxylation of vitamin K–dependent factors (II, VII, IX, and X).

Cartilage

Tidemark resists shear stress, and the superficial cartilaginous zone resists tensile forces.

- Articular cartilage, 65%–80% water; type II collagen, 95% water.
- Hyaluronate natural compound is the backbone of the central core of the proteoglycan aggregate.
- Tidemark resists shear stress.
- Superficial zone (parallel collagen fibers) resists tensile forces.

Definitions

- **Fatigue:** Repetitive loading.
- **Crevice corrosion:** Occurs at a taper interface.
- **Galvanic corrosion:** Junction of two different metals.
- Torsional moments longitudinal axis THA—100% more with stairs than walking; similar to jogging.

Associations

- **HO:** Paget disease, ankylosing spondylitis.
- **Infection:** Psoriatic arthritis, SLE, organ transplant, renal failure, diabetes, SCD.
- **Bleeding:** SCD, Paget disease.
- **Joint contractures:** Parkinson disease (TKA).
- **Dislocations:** Parkinson disease (THA and hemiarthroplasty).
- **Loosening:** SCD, hemophilic arthropathy, renal failure, organ transplant.
- **Osteonecrosis:** Antiphospholipid syndrome, alcohol use, steroid use, pregnancy, sickle cell (hemaglobinopathy).

Anatomy

- The saphenous nerve is on the posterior aspect of the sartorius at the level of the knee.

- The gracilis is above the semitendinosus ("Grace before Tea").
- Superior gluteal nerve: Gluteus medius, gluteus minimus, tensor fascia lata (L4–S1).
- Transverse acetabular ligament: Obturator nerve, artery, and vein.
- Popliteal tendon inserts on to lateral epicondyle just in front of LCL (distal and anterior).

Fat Emboli Syndrome

- Greatest risk at time of cemented femoral component position. Also occurs during acetabular reaming and hip dislocation.
- Major criteria:
  - Axillary conjunctival petechia.
  - Transient 4–6 hours hypoxia.
  - Central nervous system (CNS) depression.
  - Pulmonary edema.

Miscellaneous

- Osteoporosis is best diagnosed by T score, bone mineral density scores.
- Postoperative ileus (3%): Hypokalemia, prolonged bed rest; Ogilvie syndrome: Acute pseudo-obstruction of colon.
- Use cane on *opposite* side. If carrying a weight, use on *same* side (actually fewer hip forces this way).
- Onlay strut grafts more easily incorporate into host bone than bulk segments femur allografts; never completely, but do provide structural support.
- Pediatric patient with open physis with osteochondral defect of the medial femoral condyle and attached: Cast in flexion.
- RA: Symmetric joint space narrowing, periacetabular and femoral erosions, diffuse periarticular osteopenia; superior femoral head migration (4.5 mm/yr) and medial migration (2.5 mm/yr).
- OA has asymmetric joint space narrowing.
- Psoriatic arthritis: Infection risk is higher.
- For hemophilia patients, recommend porous-coated THA components, but cement all TKA parts regardless.
- Monomer from PMMA: A vasodilator and a myocardial depressant.
- Spot welds are a sign of stable (in-growth) extensively porous-coated femoral components.
- Preoperative cardiac risk factors: Myocardial infarction or pulmonary edema within 6 months, unstable angina, aortic stenosis, angina with minimal exertion.

Beware of pseudo-obstruction of the colon in postoperative joint patients; daily abdominal palpation is warranted to detect pseudo-obstruction earlier.

NOTES

CHAPTER 5

Sports Medicine

Upper Extremity 107

SHOULDER 107

Anatomy 107

Rotator Cuff Tears 107

Superior Labral Anterior–Posterior (SLAP) Lesions 108

Adhesive Capsulitis (Frozen Shoulder) 108

Calcific Tendonitis 109

Anterior Instability 109

Chronic Posterior Glenohumeral Dislocation 110

Scapular Winging 110

Overhead Athlete 111

Acromioclavicular Injuries 111

Sternoclavicular Dislocation 111

Shoulder Arthroplasty 112

Additional Key Shoulder Facts 112

ELBOW 113

Anatomy 113

Posterolateral Rotatory Instability 113

Distal Biceps Rupture 113

Elbow Dislocation 113

Lateral Epicondylitis (Tennis Elbow) 113

Additional Key Elbow Facts 113

HAND 114

Mallet Finger 114

Kienböck Disease (AVN of the Lunate) 115

Gamekeeper's Thumb 115

Additional Key Hand Facts 115

Lower Extremity 115

HIP 115

Femoral Neck Stress Fracture 116

KNEE 116

Anterior Cruciate Ligament (ACL) 116

Posterior Cruciate Ligament (PCL) 118

Posterolateral Corner 119
Lateral Collateral Ligament (LCL) 119
Ligament Healing 119
Meniscus 119
Patella 121
Iliotibial (IT) Band Friction Syndrome 121
Additional Key Knee Facts 121
Cartilage Lesions 121
FOOT AND ANKLE 121
Windlass Mechanism 121
Syndesmosis Injury 122
Turf Toe 122
Acute Peroneal Tendon Dislocation 122
Talar Osteochondral Lesion 122
Navicular Stress Fracture 122
Lateral Process of the Talus Fracture 122
Additional Key Ankle Facts 122
SPINE AND HEAD INJURIES 123
Concussion 123
Miscellaneous sports topics 123
Collagen Types 124

SHOULDER

Anatomy

- Inferior glenohumeral ligament (IGHL).
- Superior glenohumeral ligament (SGHL).
- Middle glenohumeral ligament (MGHL).
- **Posterior band IGHL:** Most important at preventing posterior subluxation with the shoulder at 90 degrees abduction and internal rotation (IR).
- **Anterior band IGHL:** Resists anterior/inferior subluxation with 90 degrees abduction and maximum external rotation (ER).
- **SGHL:** Resists inferior translation with arm adducted at side.
- **MGHL:** Resists anterior translation at midabduction with ER.
- **Subscapularis** prevents posterior subluxation in ER.
- **Coracohumeral (CH) ligament** at neutral prevents posterior subluxation.
- **Supraspinatus** contributes little to anterior–posterior shoulder stability.
- **SGHL and CH ligament** are primary restraints to inferior glenohumeral translation with 0 degrees abduction.
- **Internal rotators of the shoulder:**
  - Subscapularis
  - Pectoralis major
  - Teres major
  - Latissimus dorsi
- **Upper subscap:** *Belly press*; innervation from C5 (upper subscap nerve).
- **Lower subscap:** *Lift off test*; innervation from C5–6 (lower subscap nerve).
- **Quadrilateral space syndrome:** Axillary nerve, posterior humeral circumflex artery.
- **Sublabral foramen** or **Buford complex** with cordlike MGHL.
  - Anatomic variants
  - No treatment needed
- **Rotator interval:**
  - Superior glenohumoral and coracohumeral ligaments between supraspinatus and subscapularis.
  - Injury leads to posterior-inferior shoulder instability.
  - Overtightening can limit ER.

Rotator Cuff Tears

- During throwing, the rotator cuff helps prevent superior migration and controls anterior–posterior shoulder translation by depressing the humeral head.
- Cuff tear is associated with long head of biceps avulsion in those > 45 years old.
- Preserve coracoacromial arch (CA ligament) if irreparable cuff; to prevent anterior superior escape.
- Revision cuff surgery is good for *pain relief* but *not* for improving strength. Chronic massive cuff tears can lead to superior migration of the humeral head and degenerative changes (Figure 5-1).
- **Margin convergence** repair decreases strain at the free margin of the rotator cuff.
- **Internal impingement:** The most consistent scope finding is *articular side* rotator cuff tears; supraspinatus abrades posterior superior glenoid in cocking positions.

FIGURE 5-1. Rotator cuff arthropathy. Massive chronic rotator cuff tear can lead to superior migration of the humeral head and degenerative changes.

Do not resect CA ligament in patients with irreparable cuffs; this ligament will help prevent anterior superior escape.

- **External impingement:** Scope findings are biceps fraying, CA ligament fraying, and acromial spurs.
- **Cuff repair rehab:**
  - Postop: Pendulum and passive forward flexion and ER.
  - Intermediate: Closed kinetic chain.
  - 12 weeks: Open kinetic chain resistance.
  - For return to play: Plyometrics.

Superior Labral Anterior–Posterior (SLAP) Lesions

- Debride types I and III.
- Repair types II and IV.
- SIAD lesion increases strain in *anterior band IGHL* by 100% (to ER forces).
- SLAP associated with spinoglenoid cysts (Figure 5-2).

Adhesive Capsulitis (Frozen Shoulder)

- More common and more severe in diabetics.
- Three phases: Freezing, frozen, thawing.
- Initial treatment: Physical therapy.
- Surgical intervention (manipulation under anesthesia [MUA], possible arthroscopic lysis of adhesions).
  - Considered when there is no improvement in pain or shoulder motion after an appropriate course of physical therapy and anti-inflammatory medication.
  - Caution manipulation of frozen shoulder if bone is osteoporotic due to fracture risk.

FIGURE 5-2. Spinoglenoid cyst. These cysts occur in conjunction with a SLAP tear and can cause suprascapular nerve compression and isolated infraspinatus atrophy.

Calcific Tendonitis (Figure 5-3)

- Calcified deposits within rotator cuff—H[2]O, CO[3], and PO[4].
- Typically seen in fourth decade.
- More common in diabetics.
- Acute and chronic phases.
- Acute symptoms normally resolve spontaneously in 7–14 days.
- Treatment: For prolonged symptoms, cortisone injection, percutaneous needling, or arthroscopic removal of bursa and debulking.

Anterior Instability

- Age is the most significant factor for recurrence after shoulder dislocation. The younger the patient, the higher the chance of recurrence.
- If > 45 years old, rotator cuff tear is often associated with shoulder dislocation.
- TUBS: Traumatic, Unilateral, Bankart = Surgery (Bankart repair, possible capsular plication).
- AMBRI: Atraumatic, Multidirectional, Bilateral = Rehab; if extensive rehab fails, consider Inferior capsular shift.
- Relocation test: Accurate when there is apprehension with abduction 90 degrees and ER; this is relieved with posterior pressure on the humeral head.

FIGURE 5-3. Plain x-ray of calcific tendonitis of the rotator cuff. Acute symptoms typically resolve within 2 weeks.

Anterior shoulder dislocations in young patients (especially < 20 years old) have an extremely high rate of redislocation.

- **Bankart lesion:** Anterior capsulolabral avulsion from anterior glenoid. Relative contraindication to arthroscopic Bankart repair: > 25% anterior inferior glenoid rim defect or engaging Hill-Sachs lesion (Figure 5-4).
- Humeral avulsion glenohumeral ligament (HAGL): Failure to recognize may lead to recurrent anterior instability.
- Bristow procedure (mostly historical): Concern for musculocutaneous nerve injury.
- Thermal capsular shrinkage: Complications → *capsule ablation.*
- Anterior shoulder stabilization: Overtightening can cause long-term IR contracture and subsequent posterior glenoid wear.

Chronic Posterior Glenohumeral Dislocation

Posterior dislocation is more common following a seizure or an electrocution.

- < 20% humeral head defect: Reduce.
- 20%–40% defect: Transfer subscapularis and lesser tuberosity to articular defect.
- > 40%–50% defect: Humeral arthroplasty.

Scapular Winging

- Serratus anterior winging:
  - Injury to long thoracic nerve.
  - Causes elevation and inferior medial rotation of inferior scapular pole.
- **Tendon transfer: Pectoralis to inferior boarder of scapula.**
- Trapezius winging:
  - Injury to spinal accessory nerve.
  - Causes depression and inferior lateral scapular rotation.
- Tendon transfer: Levator scapulae and rhomboid major and minor.

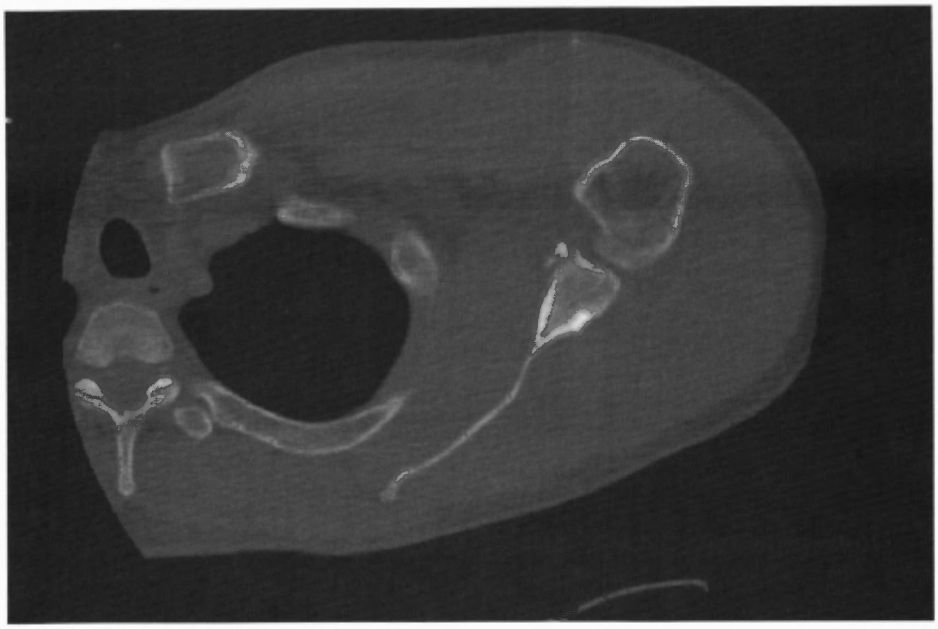

FIGURE 5-4. CT shows a Bankart lesion that involves part of the anterior glenoid ("bony Bankart"). The bony fragment is < 25% of the anterior glenoid rim and can be repaired arthroscopically.

Overhead Athlete

- Commonly posterior-superior pain and labral pathology.
- Limited ER.
- IR contracture treated with posterior capsule stretching.
- Pain over coracoid: Pec minor contracture secondary to scapular dyskinesis. Treat with pec minor stretching.
- Pitching's highest shoulder torque occurs during *deceleration*.
  - Eccentric muscle contractions.
  - May require retraining of pitching motion.

Acromioclavicular Injuries

- Primary treatment (types I, II,+/– III): Sling –3 weeks.
- **Indications for surgical intervention:**
  - Superior displacement of clavicle > 100% **(type V)** (Figure 5-5).
  - Posterior displacement through trapezius **(type IV).**
  - Inferior lateral displacement under coracoid **(type VI).**

Sternoclavicular Dislocation

- X-ray: 40-degree cephalic tilt.
- Best evaluated with computed tomography (CT).
- Posterior dislocation: Closed reduction with thoracic surgeon available.
- Anterior dislocation: Symptomatic treatment.

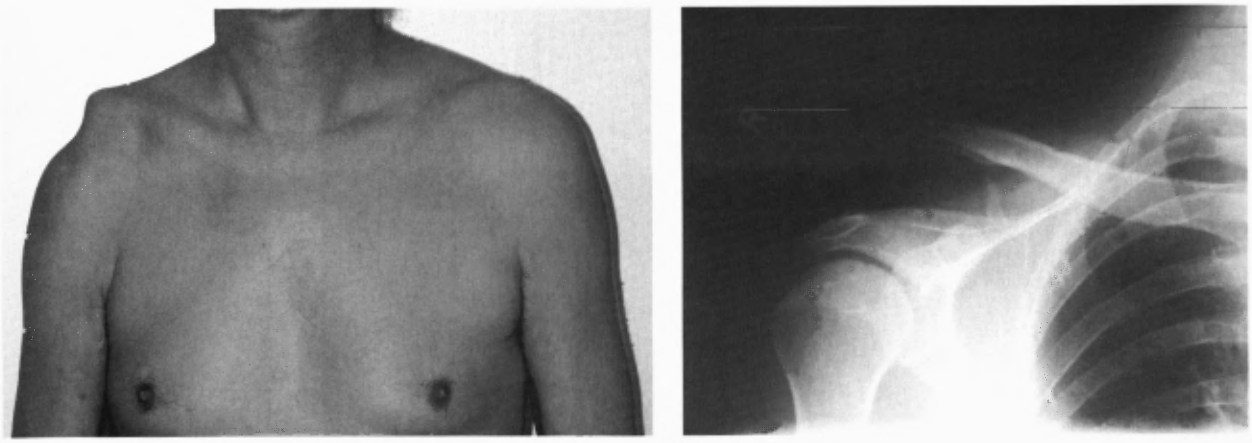

A B

FIGURE 5-5. Type V acromioclavicular joint separation. (A) Clinical photo showing the significant depression of the right shoulder. **(B)** X-ray shows > 100% displacement of the acromioclavicular joint.

When plating the proximal humerus, do not disrupt the ascending branch of the anterior humeral circumflex artery running in the lateral aspect of the bicipital groove, as it could lead to AVN.

Shoulder Arthroplasty

- Total shoulder arthroplasty (TSA) has improved pain relief vs. hemiarthroplasty.
- Do not resurface glenoid if there is an irreparable cuff tear; concern for early glenoid loosening (rocking horse effect).
- Hemiarthroplasty for avascular necrosis (AVN) unless there is stage V (i.e., glenoid involved), then TSA.
- Proximal humerus fracture:
  - Three- and four-part proximal humerus fracture: Hemiarthroplasty in elderly.
- Avoid early active range of motion (ROM) after three- and four-part proximal humerus fractures treated with arthroplasty.
- Rheumatoid shoulder:
  - Hemiarthroplasty when end stage and cuff deficiency and/or glenoid deficiency.
  - TSA with intact cuff and sufficient glenoid bone stock.

Additional Key Shoulder Facts

- Humeral head main blood supply: Ascending branch of anterior humeral circumflex artery (arcuate artery, or artery of Liang).
- Milwaukee shoulder: Inflammatory cause, hydroxyapatite (phosphate).
- Tumoral calcinosis: Associated with hyperphosphatemia; chronic renal failure (CRF). Excise if interfering with function or causing discomfort.
- Mumford failure (distal clavicle) with scope: Due to leaving anterior–lateral bone.
- Shoulder AVN: Stage of disease (nontraumatic variety) is the most significant prognostic factor.
- Pectoralis major rupture: Inferior fibers of sternal head maximum stretch final 30 degrees of humeral extension; likely to rupture with forced humeral flexion (e.g., at initiation of bench press).

ELBOW

Anatomy

- Axis of rotation: Center of trochlea and capitellum.
- Primary elbow restraints: Ulnar lateral collateral ligament (LCL), *anterior band of medial collateral ligament* (MCL), and the coronoid.
- Secondary stabilizer to elbow valgus is the *radial head.*
- Functional ROM:
  - Flexion/extension: 30–130 degrees.
  - 50 degrees of supination and 50 degrees of pronation.
  - Pronation tightens medial elbow structures; supination tightens lateral elbow structures.

The primary restraint to valgus load on the elbow is the anterior band of the MCL.

Posterolateral Rotatory Instability

- Apprehension test is performed by flexing elbow with valgus load from an extended supinated position.
- Ulnar LCL is the main stabilizer to varus stress.

Distal Biceps Rupture (Figure 5-6)

- The posterior interosseous nerve (PIN) travels within the supinator and can be injured when repairing biceps (greater risk with one-incision technique).
- Anterior approach to biceps repair at elbow: The most common nerve injury is *lateral antebrachial cutaneous.*

Elbow Dislocation

- Reduce in supination, then splint in pronation.
- The most common postreduction complication is flexion contracture.
- Severity of contracture is associated with length of immobilization.

Lateral Epicondylitis (Tennis Elbow)

- Involved muscle: Extensor carpi radialis brevis (ECRB).
- Pathology: *Angiofibroblastic* hyperplasia or hyaline degeneration, not inflammation.
- Due to eccentric overload (commonly with tennis backhand).

Additional Key Elbow Facts

- Cubital tunnel syndrome: Night splint with upper extremity in 45 degrees elbow flexion and neutral forearm rotation helps protect the ulnar nerve.
- Supracondylar process: Associated with median nerve compression, ligament of Struthers.
- Heterotopic ossification (HO) after open reduction and internal fixation (ORIF): Some now advocate earlier release with heterotopic bone resection (–8 weeks).
- Floating elbow: ORIF of both fractures to promote earlier ROM and prevent elbow stiffness.
- Bicolumn distal humerus fracture: Medial and posterolateral plates; either dynamic compression plate (DCP) or 3.5-mm reconstruction plates placed at 90 degrees to each other.

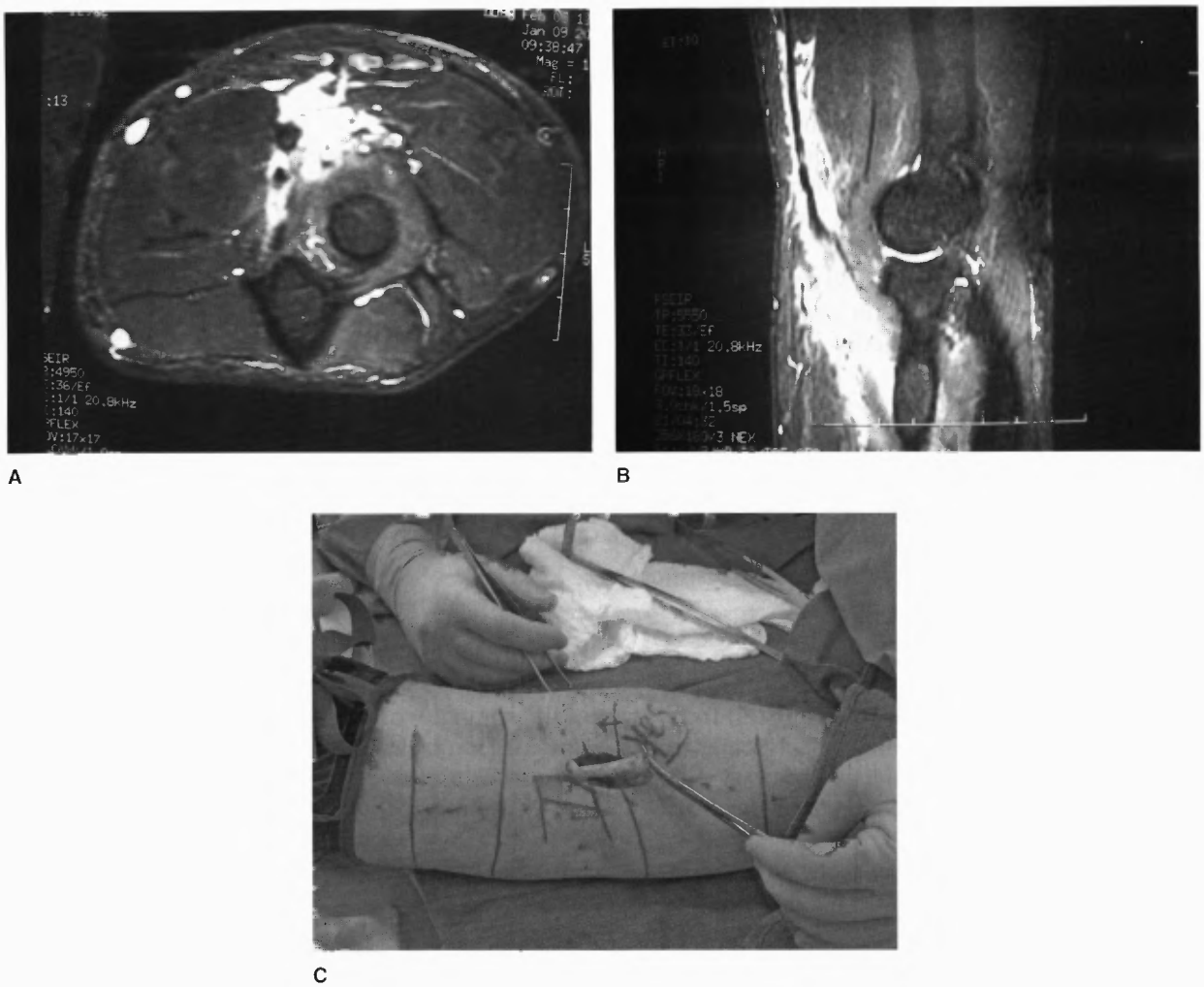

FIGURE 5-6. Distal biceps rupture. (A and B) MRI demonstrating distal biceps rupture. Note retraction of the tendon and significant edema. **(C)** Single-incision repair of a distal biceps rupture demonstrating the end of the tendon.

- Congenital radial head dislocation:
  - Dome-shaped radial head on radiographs.
  - Flexion loss, while extension is typically maintained.
  - Posterior subluxation on lateral film.
  - No treatment needed unless symptomatic.
- Pitcher's elbow: Posteromedial osteophytes; due to ulnar collateral ligament insufficiency and valgus extension overload.
- MCL avulsion in throwing athlete: Surgery.
- Adolescent throwers: OCD of capitellum is treated with rest until symptoms resolve.
- Elbow arthroscopy: Anterolateral portal places the radial nerve at risk.
- Monteggia fracture: The most common nerve injured is the PIN.

HAND

Mallet Finger

- Disruption of extensor tendon insertion into distal phalanx.
- Typically from forced flexion on fingertip or laceration on extensor surface near distal interphalangeal joint (DIP).

- **Treatment:**
  - Splint in hyperextension for 6 weeks.
  - If DIP is volarly subluxated, may need early operative fixation.

Kienböck Disease (AVN of the Lunate)

- Often causes little disability.
- Boggy synovitis around lunate.
- Decreased wrist ROM.
- The radiologic findings and symptoms do not correlate well. Ulnar negative wrist is a frequent finding.
- **Treatment:**
  - Conservative first; no surgical procedure has been conclusively shown to prevent progression.
  - Surgery is indicated only when pain and disability cannot be managed with conservative measures.

Gamekeeper's Thumb

- Ulnar collateral ligament tear at the thumb metacarpophalangeal (MCP). *Stenner lesion* is typical if > 30 degrees opening with stress or > 15 degrees difference from the other side.
- Adductor aponeurosis is entrapped.

Additional Key Hand Facts

- Hook of hamate fracture: Usually occurs in a golfer or baseball player.
- Diagnose with carpal tunnel view.
- Cast if diagnosed early.
- Excise if late finding (symptomatic nonunion).
- Pisiform fracture: Attempt nonoperative treatment first.

Hook of hamate fractures can be evaluated on the carpal tunnel view.

▶ LOWER EXTREMITY

HIP

- Traumatic hip dislocation (90% posterior).
- AVN rate following traumatic dislocation is 10%–20%.
- Piriformis syndrome: Localized posterior hip pain and radicular symptoms in sciatic distribution.
- Athletic pubalgia: Lower abdominal and adductor pain.
- Osteitis pubis: Symphysis pubis inflammation and pain.
- Iliac apophysis: Three to five times weaker than tendon and therefore risk of tendon avulsion.
- Beware of pelvis radiograph with bone fragment near the anterior-superior iliac spine (ASIS).
- Hamstring proximal avulsion in athlete: Early operative treatment, prolonged rehab, and then return to sports.
- **Femoral-acetabular impingement:**
  - Femoral neck impinges on anterior-superior acetabulum.
  - Associated with minor trauma in young active adults.
  - Associated with dysplasia of femoral neck and acetabulum.

- Associated with early osteoarthritis (OA).
- Provocative maneuver: Hip flexion, IR, adduction.
- Treatment: Hip arthroscopy or surgical dislocation
- *Surgical dislocation* of the hip does not increase risk of AVN.

- **Snapping hip (coax saltans):**
  - Internal: Psoas snapping over iliopectineal line or femoral head.
  - Produced by hip flexion/extension with ER and abduction.
  - Treatment: Conservative then psoas tendon lengthening if necessary.
  - External: Snapping of IT band or gluteus maximus over trochanter.
  - Most common.
  - Produced by hip flexion/extension with IR and adduction.
  - Treatment: Conservative then iliotibial (IT) band lengthening if necessary.

Femoral Neck Stress Fracture (Figure 5-7)

- Compression side: Treatment is protected weight bearing.
- Tension side: Percutaneous pinning.

KNEE

Anterior Cruciate Ligament (ACL)

- Anteromedial bundle tight in flexion; posterolateral bundle tight in extension.
- Highest tension in full extension.
- Injury with extension, deceleration, cutting/pivoting (Figure 5-8).
- Main cruciate blood supply is from the middle geniculate artery.
- Segond sign: Lateral capsule avulsion with fleck of bone—consistent with ACL tear.
- Decreased tears in females with implementation of plyometric and neuromuscular training.
- Rehab after ACL reconstruction: No active isometric quadriceps exercises for 6 weeks.
- Strongest graft is quadruple looped semitendinosus and gracilis.
- If more anterior drawer with ER: Worrisome for posterior-medial capsule injury.
- Valgus load primary stabilizer is MCL (secondary is ACL and posterior cruciate ligament [PCL]).
- ACL tibial graft placement: Most reliable landmark is PCL (footprint is 10–11 mm anterior to PCL).
  - Another landmark is the posterior margin of the anterior-horn lateral meniscus, but this has twice the variability.
  - ACL reconstruction:
  - For exam, two-bundle ACL reconstruction will not be the answer.
  - If too anterior on femoral side, ACL will be tight in flexion and lax in extension.
  - Cyclops lesion: Due to a remnant of ACL and/or drilling remnants.
- Treatment/prevention: Remove ACL remnant and debris, +/– more notch-plasty.
- Pull-out strength of interference screws decreases as they diverge from the bone plug.
- ACL-deficient knee:
  - The most significant factor for developing OA is meniscal integrity.
  - "Quad avoidance" from 45 degrees to full extension during stance phase; an adaptation to prevent anterior tibial translation (an ACL function).

With an acute ACL tear the posterior horn of the lateral meniscus is most commonly torn. In an ACL-deficient knee, the medial meniscus is most likely to be torn.

FIGURE 5-7. Femoral neck stress fracture. (A) X-ray showing compression side stress fracture. **(B)** Noncompliant patient continued to run and completed the femoral neck fracture. **(C)** X-ray illustrates a failed pinning and nonunion, which was treated with a Pauwel's valgus intertrochanteric osteotomy **(D).**

- ACL reconstruction with allograft: Possible development of pretibial cysts and/or tunnel enlargement.
- Rehab following ACL reconstruction: Avoid early open-chain knee extension (extension from 60 degrees to 0 degree increases anterior tibial translation).
- Acute ACL injury alters the strain patterns in the lateral meniscus; chronic ACL insufficiency increases the strain in the medial meniscus and often results in tears of the posterior horn.

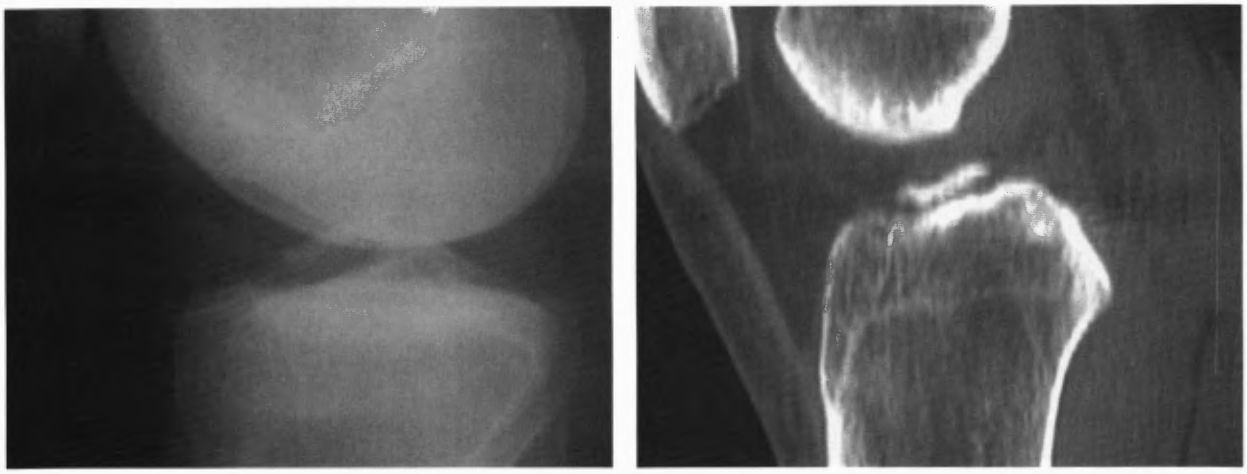

A B

FIGURE 5-8. Anterior cruciate ligament (ACL) injury. (A and B) CT scans showing ACL avulsion from tibial spine.

Posterior Cruciate Ligament (PCL) (Figure 5-9)

- Anterolateral bundle tight in flexion, posteromedial bundle tight in extension.
- Ligament of Humphry is anterior to PCL.
- Ligament of Wrisberg is posterior to PCL.

FIGURE 5-9. PCL tear. Sagittal MRI showing a disruption near the femoral insertion.

SPORTS MEDICINE

- Main cruciate blood supply is from the middle geniculate artery, same as ACL.
- On examination, a patient with posterior lateral corner injury will have more tibial ER at 30 degrees than 90 degrees (Dial test).
  - More rotation at 90 degrees indicates isolated PCL injury.
  - If increased during both maneuvers, then both are injured.
  - More valgus in knee extension is concerning for possible PCL injury.
- **Treatment:**
  - Grade I/II PCL tear: Protected weight bearing and quad rehab; return to play in 2–4 weeks.
  - Grade III PCL tear: Extension immobilization for 2–4 weeks, then quad rehab.
  - Approach for PCL reconstruction inlay technique is a posteromedial incision between the semimembranosus and the medial head of the gastrocnemius.
  - Popliteal artery is 2 cm from bone block on the tibia.
  - PCL double-bundle technique: Anterolateral bundle tension at 90 degrees flexion and the posteromedial bundle tension in extension.

Posterolateral Corner

- Popliteofibular ligament: Resists posterolateral rotation of tibia on femur.
- Early repair preferred; if > 3 weeks since injury, consider reconstruction.
- ER test is best performed with a prone patient.

Lateral Collateral Ligament (LCL)

- Primarily resists varus at 30 degrees knee flexion.
- Secondarily resists posterolateral rotation with flexion <50 degrees.
- PCL, ACL, and LCL resist varus in full knee extension.
- Pediatric patient with valgus knee laxity: Obtain **stress radiographs**.
  - Must rule out *distal femoral physeal injury*.

Ligament Healing

- Four stages:
  - Inflammation—scar, type III collagen
  - Proliferation—fibrin clot, type I collagen
  - Remodeling
  - Maturation
- Intraarticular ligaments (i.e., the ACL) do not complete all stages. They lack tissue bridging
- Negative effects on ligament healing: Immobilization and increased age.

Meniscus (Figure 5-10)

- Meniscal tears heal only in peripheral vascular (red-red) zone, outer third.
- Inflammatory cells infiltrate peripheral meniscus tears to assist healing.
- Circumferential meniscal fibers resist tensile **hoop stresses** associated with axial compression.
- Transmits 50% weight-bearing load in extension, 85% in flexion.

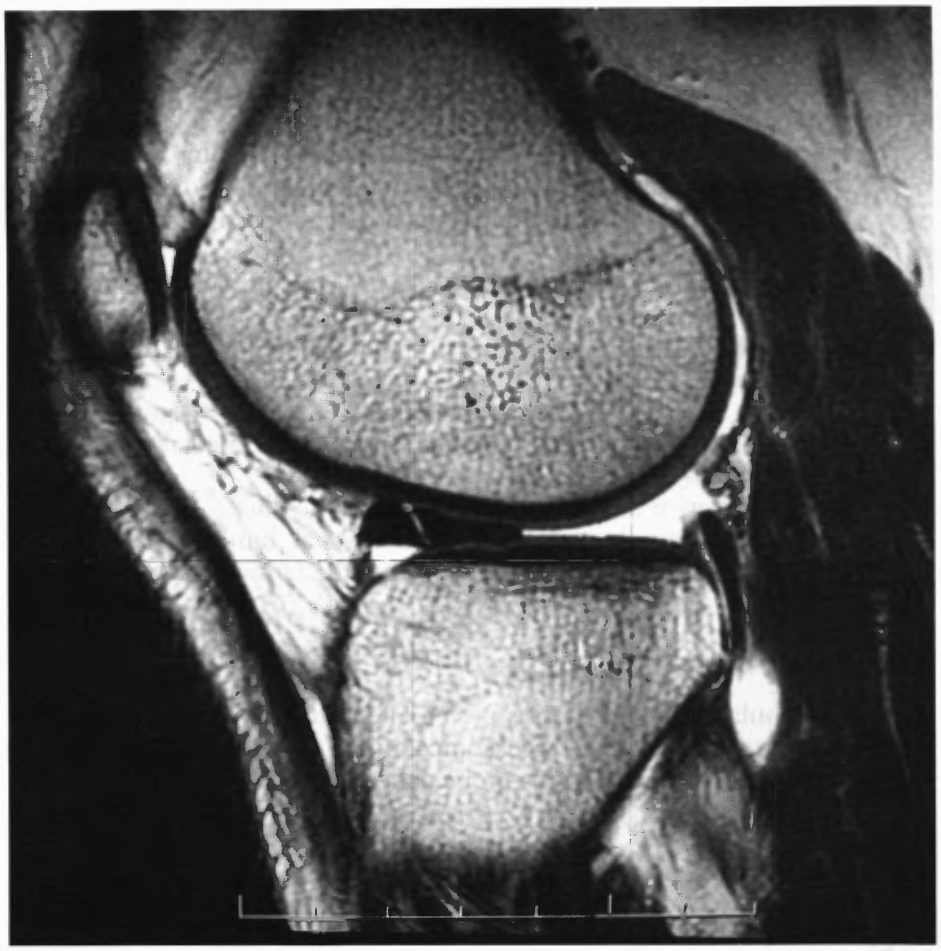

FIGURE 5-10. Bucket handle meniscal tear. Posterior horn meniscal tear displaced anteriorly into the joint.

- Discoid lateral meniscus: Magnetic resonance imaging (MRI) shows "bowtie" on three 5-mm slices (normal width, 10–12 mm); if symptomatic, saucerize.
- Meniscus is more elastic and less permeable than articular cartilage.
- Meniscal allograft is contraindicated if significant degenerative changes are present.
- Correct allograft size is more important than preservation technique for successful transplantation.
- Meniscal repair techniques show that vertical mattress sutures are the strongest.
- Adult meniscus is 25% vascularized from the lateral and medial geniculate arteries.
- Meniscetomy decreases contact area by 75%, increases local contact stress by > 200%.
- In the ACL-deficient knee, menisci are the primary stabilizers to anterior translation.
- **Meniscal repair risks:**
  - Medial: Saphenous nerve and vein, popliteal vessels.
  - Lateral: Peroneal nerve, popliteal vessels.
- **Fibrochondrocyte** is the cell responsible for meniscal healing.

Meniscal repairs have a higher rate of healing if performed at the same time as an ACL reconstruction.

Patella

- Symptomatic lateral tilt failing conservative management: Consider arthroscopic lateral release.
- Symptomatic lateral tilt and subluxation failing conservative management: Consider lateral release and anteromedial transfer of tubercle.
- Lateral patellar dislocation: Disruption of the medial patellofemoral ligament, which is the major static soft tissue restraint (often while batting).
- **Patellar tendinitis (jumper's knee):**
  - Pain at inferior patellar pole; common in basketball players.
  - Initial treatment is quadriceps and hamstring strengthening.
  - If conservative treatment fails and mucoid degeneration is present within the tendon, consider operative debridement.
  - Be leery of placing steroids in tendons.

Iliotibial (IT) Band Friction Syndrome

- Pain over distal IT band and lateral femoral epicondyle.
- Pain is greatest at –30 degrees flexion.
- Common in runners, especially those running on sloped surfaces.
- Physical therapy is successful in the majority of patients.
- Rarely, debridement of an ellipse of the IT band is required to provide relief.

Additional Key Knee Facts

- The knee capsular reflection is most distal *posterior to the fibula.*
- Reflex sympathetic dystrophy (RSD) is treated with:
  - Alpha-blocking agents
  - Sympathetic blockade
  - Active-assist ROM
- Prepatellar abscess: Attempt treatment with aspiration, compression, and antibiotics.
- Osteochondral defect (OCD) prognosis is dependent on physeal age.
- Tibial tubercle avulsion: Beware of concomitant anterior compartment syndrome.
- A knee brace during sports can reduce MCL injuries.

Cartilage Lesions

- Proteoglycans retain fluid in cartilage matrix.
- Chondrocyte modulation is via mechanotransduction.
- IL-1 is part of the pathogenesis of OA.
- Tidemark = calcified cartilage (rests on subchondral bone).
- A lesion that does not penetrate subchondral bone will not heal (avascular).
- Deep lesions that cross the tidemark heel with Type I cartilage.
- Most lesions heal with fibrocartilage.

FOOT AND ANKLE

Windlass Mechanism

- Dorsiflexing the great toe while standing accentuates the rigidity of the transverse tarsal joint.
- Dorsiflexing the great toe will tighten the plantar fascia and stabilize the longitudinal arch.

- Supination makes the talonavicular and calcaneocuboid joints nonparallel, which accentuates the rigidity of the transverse tarsal articulation.
- Heel goes into varus, resulting in obligatory tibial ER.

Syndesmosis Injury

- Dorsiflexion ER ankle sprain can cause syndesmosis injury.
- Sideline evaluation: Diagnose with inability to do single-leg hop.
- The best determinant for return to play is amount of tenderness along the syndesmosis, as measured from the distal tip of the fibula up the syndesmosis.
- Klieger ER test indicates syndesmosis injury.
- Can result in tibiofibular synostosis 6–12 months after injury. Treat conservatively until it is "cold" on bone scan. Operate only if it continues to be painful.

Turf Toe

- Rupture of plantar plate.
- Caused by forceful hyperextension of the first MTP joint.
- Treatment: Initially conservative; consider stiff-sole shoe, rocker bottom.

Acute Peroneal Tendon Dislocation

- Treat with cast immobilization and partial weight bearing.
- Consider acute superior retinacular repair in a high-level athlete.
- If chronic and symptomatic, consider fibular groove–deepening procedures.

Talar Osteochondral Lesion

- Anterolateral talar dome is a common location from trauma.
- Posteromedial talar dome is a common location from chronic injury.

Navicular Stress Fracture

- Cast and *non–weight-bearing* immediately.
- Consider ORIF in an athlete.

Lateral Process of the Talus Fracture

- Snowboarder's fracture.
- Obtain CT to rule the diagnosis out or in.
- Depending on the size of the fragment: ORIF vs. excision.

Additional Key Ankle Facts

- Calcaneal apophysitis (*Sever disease*): Initial treatment is a stretching program.
- Anterior tibiotalar osteophytes can cause pain with passive dorsiflexion.
- Ballet dancer: Posterior ankle pain (flexor hallucis longus [FHL] tendinitis vs. os trigonum syndrome).

- Dancer's fracture: Fifth metatarsal shaft. Treat with brief immobilization and symptomatic treatment.
- Jones fracture in high-level athlete: IM screw.
- Superficial peroneal nerve compression:
  - 10 cm proximal to lateral ankle
  - Pain and paresthesias in runners
  - Treatment: Fascial release and neurolysis

SPINE AND HEAD INJURIES

- C-spine fracture in an athlete with neurologic deficit is typically due to a flexion–compression force.
- C-spine injury in the athlete: (1) immobilize, (2) remove facemask, **not** helmet.
- Transient quadriplegia: No return to play if there is MRI documentation of spinal stenosis.
- Adolescent disk: The only consistent physical exam finding is a positive straight leg raise.
- Bone scan with single photon–emission computed tomography (SPECT): Sensitive early in pars interarticularis stress fracture.
- **Burner/Stinger:**
  - Often from tackling with the helmet.
  - Unilateral symptoms.
  - Resolves quickly (minutes).
  - May return to play without further studies if neuro/motor exam is normal and symptoms are gone.
- **Cervical neuropraxia:**
  - Same mechanism.
  - Bilateral symptoms.
  - Takes longer to resolve (several minutes to hours).
  - Return to play is contraindicated until MRI of C-spine is evaluated.

The most sensitive test in early pars interarticularis stress fractures is a SPECT scan.

Concussion

- Grade I: No loss of consciousness (LOC) or amnesia; may return to play after 15 minutes.
- Grade II: LOC < 5 minutes; may return in 1 week.
- Grade III: LOC > 5 minutes or amnesia; no play for a month.
- Three grade I or II or two grade III concussions: Out for season.

Miscellaneous Sports Topics

- Force of muscle contracture most dependent on cross-sectional area.
- Traumatic mydriasis: Contusion to the iris sphincter that results in transient pupil dilatation.
- Fluid replenishment:
  - Low-osmolality fluids (e.g., water) are best.
  - Glucose actually enhances absorption.
  - Fructose (e.g., orange juice) lessens absorption.
  - Adding carbohydrates can enhance athletic performance.
- Water debt at onset of exercise affects magnitude of core temperature increase as well as heart rate increase.
- Auricular hematoma is often seen in a wrestler not using proper headgear. If no sign of infection, aspirate and apply a compression dressing.

- Postexercise soreness is due to inflammation.
- Rowers can obtain rib stress fractures; treat conservatively.
- Hypertrophic cardiomyopathy:
  - Suspect if murmur increases with Valsalva maneuver; may find on a preseason physical.
  - Absolute contraindication to participate in sports.
- Active myocarditis means restricting athletics for 6 months.
- Myositis ossificans worsens with *passive* stretching. Initially, no ultrasound or massage therapy as these may exacerbate symptoms.
- Heat stroke: Hyperthermia, CNS dysfunction, cessation of sweating; need emergent cooling and fluids.
- Deep-freezing grafts has no deleterious clinical effects on ligaments.
- Collagen in cartilage provides tensile strength.
- Proteoglycans are for compressive strength.
- Hamstring injury usually occurs at the *musculotendinous junction.*
- Scalene block: The most common complication is inadequate block.
- Proprioceptive neuromuscular facilitation is best for flexibility and joint ROM.
- Prepubescent athlete: Strength gain is via neurogenic adaptations.
- Myogenic adaptations after puberty: Thickened connective tissue, more contractile proteins, increased short-term energy sources (e.g., creatine phosphate).
- "Commotio cordis": Sudden cardiac arrest in a child following a blow to the chest (baseball). Treat with immediate cardiac defibrillation.
- Female athlete triad: Menstrual dysfunction, eating disorder, stress fracture. Treat with oral contraceptives, calcium and vitamin D, cross-training.
- Subacromial steroid injection can cause potentially elevated and fluctuating glucose in diabetic patients.
- The spleen is the most commonly injured organ in blunt trauma (football).
- Mononucleosis: May return to sport 4 weeks after onset as long as the spleen is normal size. Risk of splenic rupture in contact sports.
- Creatine converts to phosphocreatine (PCr) and acts as an energy reservoir for adenosine triphosphate (ATP) in muscle.
- Sodium deficiency can cause heat cramps.
- Synovial type A cells are important in phagocytosis.
- Synovial type B cells produce synovial fluid.
- Undifferentiated perivascular mesenchyme is the target cell for bone morphogenic protein.

Collagen Types

- *Type I*: Found in healing cartilage lesions, also in *annulus* of disks, tendon, bone, meniscus, and skin.
- *Type II*: Articular cartilage and nucleus pulposus.
- *Type III*: Skin and blood vessels.
- *Type IV*: Basement membrane.
- *Type X*: Calcified layer of cartilage.
- Produced only by hypertrophied chondrocytes.

CHAPTER 6

The Hand

Hand Anatomy 128
- Swan-Neck Deformity 128
- Boutonniere Deformity 128

Wrist 128
- Radial-Side Wrist Pain 128
- Ulnar-Side Wrist Pain 129
- Dorsal Wrist Pain 129
- Carpal Instability 130

Arthritis 131
- RA 131
- Juvenile Rheumatoid Arthritis (JRA) 131
- Gout 131
- Psoriatic Arthritis 131
- CMC Joint 131
- Miscellaneous 132

Vascular Hand Lesions 132
- Raynaud 132
- Thromboangiitis Obliterans (Buerger Disease) 132
- Giant Cell Arteritis 132
- Takayasu's Arteritis 132
- Polyarteritis Nodosa 132
- Miscellaneous 133

Tendons 133
- Extensor Tendons 133
- Flexor Tendons 133
- Tendon Repair 133
- Boutonniere Deformity 134
- Swan-Neck Deformity 134

Replantation 134

Amputations, Flaps, and Skin Grafts 134
- Fingertip Amputation 134
- Vascularized Grafts 135

Flaps 135
Thumb 135
Nerves 135
Double Crush Phenomenon 136
Order of Nerve Recovery 136
Electromyography (EMG)/Nerve Conduction Velocity (NCV) 136
COMPRESSION NEUROPATHIES 136
Neuropathy Risk Factors 136
Median Nerve Compression 136
Ulnar Nerve Compression 137
Radial Nerve Compression 138
Nerve Injury 138
Congenital Hand Disorders 138
Autosomal Dominant 138
Duplication 139
Radial Club Hand 139
Ulnar Club Hand 139
Radioulnar Synostosis 139
Syndactyly 139
Symphylangism 139
Camptodactyly 140
Hypoplastic Thumb 140
Flexed Thumb 140
Pollicization 140
Arthrogryposis 140
Poland Syndrome 140
Apert Syndrome 140
Madelung Deformity 140
Miscellaneous 141
Tendon Transfers 141
Severity of Injury 141
Surgical Priorities 141
Excursion 3-5-7 Rule 141
Cerebral Palsy (CP) 141
Radial Nerve Transfers 142
Pin Palsy 142
Opposition Transfers 142
Low Ulnar Nerve Palsy 142
High Ulnar Nerve Palsy 142
Commonly Tested Transfers 142
Hand Infections 142
Necrotizing Fasciitis 143
Pyoderma Gangrenosum 143
Parona's Space 143
Herpetic Whitlow 143

Dupuytren Disease 143

Hand Tumors 144

- Giant Cell Tumor of Tendon Sheath 144
- Neurilemmoma 144
- Glomus Tumor 144
- Ganglion 144
- Calcinosis 144
- Carpal Boss 144
- Enchondroma 144
- Osteoid Osteoma 145
- Squamous Cell Carcinoma 145
- Melanoma 145
- Epithelioid Sarcoma 145
- Miscellaneous 145

Hand Trauma 145

- Mallet Finger 145
- Dorsal Dislocation of PIP 145
- Volar Dislocation PIP 145
- Rotary Dislocation 146
- Lateral PIP Dislocation 146
- Dorsal MCP Dislocation 146
- MCP Hyperextension Dislocations 146
- Gamekeeper's Thumb 146
- Simple Finger Fracture 146
- Metacarpal Fracture 146
- Scaphoid Fracture 146
- Elbow 147
- Miscellaneous 148

HAND ANATOMY

- 3+ **ulnar variance** increases ulnar load by 42%.
- **Central band of the interosseous (IO) membrane** of the forearm (IO ligament): Primary function is to transfer load from the *radius to the ulna*.
- **Abductor pollicis brevis (APB)** is main palmar abductor of the thumb.
- **Flexor pollicis brevis (FPB):** Dual-innervation ulnar nerve (deep head, terminal branch) and median nerve (superficial head).
- **Lumbrical:** Origin and insert on tendon (flexor digitorum profundus [FDP] to lateral band); relaxes its own antagonist (FDP).
- **Superficial arch:** Dominant feed is from ulnar artery (one-third of people are codominant).
- Palmar cutaneous branch of median nerve between palmaris longus (PL) and flexor carpi radialis (FCR) at wrist.
- Recurrent motor branch of the median nerve is extraligamentous 50%, subligamentous 30%, and transligamentous 20% of the time.
- Carpal tunnel contains nine ligaments and one nerve; flexor pollicis longus (FPL) is the most radial structure
- **Parona's space:** Potential space between pronator quadratus (PQ) and FDP; connects thumb and small finger.
- **Ligament of Landsmeer:** Oblique retinacular ligament (ORL) (proximal phalanx to dorsal distal phalanx.
- **Intrinsic plus hand:** Bunnel test—positive for intrinsic tightness when there is less interphalangeal (IP) flexion with metacarpophalangeal (MCP) extension.
- **Intrinsic minus hand** (claw hand): MCP hyperextension and IP joint flexion. **Lumbrical plus finger** causes:
  - FDP laceration.
  - Distal amputation.
  - Loose FDP reconstruction.
  - Lumbrical adhesion to FDP.

A malreduced distal radius fracture with 3+ ulnar variance will significantly increase loads across the ulna by more than 40%.

Swan-Neck Deformity

- Proximal interphalangeal (PIP) hyperextension, distal interphalangeal (DIP) flexion.
- Volar plate issues (MCP volar subluxation, mallet finger, laceration or transfer of flexor digitorum superficialis [FDS], intrinsic contracture).

Boutonniere Deformity

- PIP flexion, DIP hyperextension.
- Central slip rupture (volar subluxation of lateral bands).

WRIST

Radial-Side Wrist Pain

- **Intersection syndrome:** Problem between the first and second compartments. Treatment: Bursectomy.
- **DeQuervain:** Extensor digitorum brevis (EDB) often has its own slip.

- **Scaphoid fracture:** 80% blood from dorsal ridge; 100% avascular necrosis (AVN) for proximal one-fifth, 30% AVN for proximal one-third.
  - *Long arm cast—shorter time to union and decreased nonunion.*
  - Time to union depends on location (proximal much longer: 12–23 weeks).
  - **Scaphoid nonunion advanced collapse (SNAC)** progression of degenerative changes is radial styloid, capitate, then capitolunate; spares the lunate fossa.
  - Vascularized bone graft: *1,2 intercompartmental supraretinacular artery.*
- **Scaphotrapeziotrapezoid (STT) arthritis:** Similar presentation as DeQuervain, x-ray differentiates the two diagnoses.
- *Preiser disease* is scaphoid AVN.
- *Thumb carpometacarpal (CMC) arthritis:* Pain with grind or axial load; suspension arthroplasty; use all of FCR.
- *FCR tendinitis:* FCR goes through fibro-osseous sheath.
- *Volar ganglion:* 20% volar recur, 5% dorsal recur; injection not a good idea—(no benefit); STT or scaphoradial ligament.

Scaphoid fractures have 100% AVN with proximal fifth location.

Ulnar-Side Wrist Pain

- 20% load goes through the ulna (+2 mm get 40%, –2 mm get 5%).
- Lister's tubercle is the CT cut to assess the distal radioulnar joint (DRUJ).
- **Flexor carpi ulnaris (FCU) tendinitis:** Calcific occasionally (looks like infection); otherwise, same treatment as any other tendinitis.
- **Triangular fibrocartilage complex (TFCC) tear:** Main anchor point is the fovea just in front of the ulnar styloid.
  - Mode of injury: Wrist extension, forearm pronation.
  - *Pronation*: The volar ligaments prevent dorsal subluxation.
  - *Supination*: The dorsal ligaments prevent volar subluxation.
  - Type I: Traumatic.
  - Type II: Degenerative (ulnocarpal impaction) (A—TFCC wear, B—lunate carpometacarpal, C—LT tear, D—ulnocarpal arthritis).
- **Extensor carpi ulnaris (ECU) subluxation:** *Tear of ECU subsheath*; stability is not from retinaculum but from subsheath.
- **Hamate hook fracture:** Golfers; acute (< 6 weeks) immobilize; if chronic, excise.

Dorsal Wrist Pain

- **Dorsal ganglion:** 70% from scapholunate ligament; recurs less than volar.
- **Extensor tenosynovitis:** Rheumatoid arthritis (RA) workup.
- **Scapholunate advanced collapse (SLAC)** (see below):
  - Stages: I—radial tip, II—scaphoid fossa, III—capitate, IV—wrist (spared lunate fossa).
- **Kienböck's:** Associated with *ulnar minus wrist*; Lichtman staging system:
  - I: MRI changes only.
  - II: Lunate sclerosis.
  - IIIa: Sclerosis and fragmentation.
  - IIIb: 3A with fixed scaphoid rotation (ring sign).
  - IV: Degenerative arthritis in adjacent intercarpal ligaments.
    - I–IIIa: Joint leveling (radial shortening [unless ulnar neutral] or STT or scaphocapitate [SC] arthrodesis).
    - IIIb: STT or SC fusion (scaphoid ring sign).
    - IV: *Wrist fusion*, intercarpal fusion, or PRC.

Golfers with wrist pain: Beware of occult hamate fracture; diagnose with computed tomography (CT) or carpal tunnel radiographic view.

- **SLAC wrist:** The leading cause of radiocarpal arthritis (lunate fossa is preserved!).
  - I: Radial styloid tip; conservative treatment (*or* styloidectomy *or* STT fusion).
  - II: Scaphoid fossa; PRC (no capitate changes!) *or* four-corner fusion *or* wrist fusion.
  - III: Capitate; wrist fusion *or* four-corner fusion.
  - IV: Wrist; wrist fusion *or* scaphoid excision with four-corner fusion.
  - PRC: Better motion; PRC fails if there is capitate arthritis; no clinical difference between PRC and four-corner fusion.
  - *Wrist fusion*: Best pain relief, good grip strength, but no motion.
  - *PRC*: Best motion, worst grip, worst pain relief.
  - *Scaphoid excision with four-corner fusion*: Good compromise.
- **SNAC wrist:** Proximal pole scaphoid and radial surface spared from arthritis because not typically loaded:
  - I: Radial styloid tip.
  - II: Capitate.
  - III: Capitolunate articulation.
  - **Treatment:** PRC vs. scaphoidectomy and four-corner fusion.

Dorsal wrist ganglia most often originate at the scapholunate ligament.

Carpal Instability

- **Dorsal ligaments:** Dorsal carpal ligament (DCL) or dorsal intercarpal ligament (DIC) and radiolunotriquetral ligament (RLT); both insert on triquetrum.
- **Volar ligaments:** Radioscaphocapitate (RSC), long radiolunate ligament (LRL), short radiolunate ligament (SRL), ulnolunate ligament (UL), ulnotriquetral ligaments (UT).
  - Also between SRL and LRL is the **ligament of Testut** (radioscapholunate—neurovascular (NV) conduit).
  - SRL and LRL are very stout.
- Scaphoid wants to flex, triquetrum wants to extend.
- Ulnar deviation causes scaphoid to extend; radial deviation causes scaphoid to flex.
- **Lunotriquetral (LT) instability:** Tear LT ligament and the dorsal radioulnar ligament.
- **Carpal instability, dissociative (CID):** Dorsal intercalated segmental instability (DISI) and volar intercalated segmental instability (VISI); disruption of an intercarpal ligament within a row.
- **DISI:** Scapholunate ligament disruption; scaphoid flexes, scapholunate angle >60 degrees; acute treatment is repair.
- **SLAC:** *Watson test*—get clunk when scaphoid rides over the dorsal lip of radius and reduces with radial deviation.
- **VISI:** LT ligament; get volar lunate flexion.
  - Isolated **LT** tear, no VISI: Must tear some of the **RLT** too.
  - Acute: Open repair.
  - Late: LT fusion.
- **Carpal instability, nondissociative (CIND):** Ligament instability between rows (either radiocarpal or midcarpal).
- **Carpal instability, combined (CIC):** Ligament disruption both within *and* between rows.
- **Fusions:** Motion lost with radiocarpal (55%–60%), midcarpal (20%–35%), within row (10%–20%).

The most motion is lost with a radiocarpal fusion (60%), while midcarpal fusion is less (35%).

RA

- Caput ulnae: Vaughn-Jackson syndrome—ruptured extensor tendons.
  - Single tendon—side-to-side repair.
  - Two tendons—side-to-side plus extensor indicis proprius (EIP).
  - Three tendons—EIP to ring and small, side-to-side for middle finger to index finger.
  - Four tendons—FDS transfer.
- **Mannerfelt lesion:** Osteophyte on scaphoid; get FPL rupture; treat with interposition graft or FDS transfer.
- Treat flexor tendon ruptures *quickly*!
- MCP joints: Swanson arthroplasty; *must* correct wrist.
- If carpus translates, supination and volar; consider extensor carpi radialis longus (ECRL) to ECU transfer.

Juvenile Rheumatoid Arthritis (JRA)

- Systemic (Still disease), fever, rash, myalgia.
- Polyarticular five or more joints, symmetric.
- Pauciarticular, asymmetric, and fewer than five joints.

Gout

- Negative birefringence.
- Monosodium urate crystals.
- Yellow when parallel to light.
- Needle crystals.
- Treat with indomethacin or intramuscular adrenocorticotrophic hormone (ACTH).
  - *Colchicine*: Inhibit granulocyte migration (granulocytopenia); acute treatment.
  - *Indocin*: Also for acute attacks (diarrhea and granulocytopenia).
  - *Allopurinol*: Inhibit xanthine oxidase (not for acute attacks).
  - *Probenecid*: Increase urine excretion of uric acid.
- **Calcium pyrophosphate deposition (CPPD):** Positive birefringence rhomboid crystals.

Gout is negative birefringence, yellow when parallel to light, and needle shaped, while CPPD is positive birefringence, blue when parallel to light, and blunt shaped.

Psoriatic Arthritis

- Nail pitting.
- "Pencil in cup."

CMC Joint

- *Palmar beak ligament* is critical.
- Thumb CMC fusion: 30–40 degrees palmar abduction, 30–35 degrees radial abduction, 15 degrees pronation.
- Ligament reconstruction tendon interposition (**LRTI**) with 25% subsidence postoperatively: *No* change in functional outcome.

Miscellaneous

- **Scaphoid nonunion:** The first sign of osteoarthritis (OA) is at the distal pole scaphoid and radial styloid.
- **Radiocarpal arthritis:** Dorsal tilt > 30 degrees after distal radius fracture is associated with radiocarpal arthritis.
- **Psoriatic arthritis:** Methotrexate can provide good relief.
- **Mucous cyst:** Debride osteophyte at DIP joint and cyst goes away.

▶ VASCULAR HAND LESIONS

Raynaud

- *Phenomenon*: Episodic.
- *Syndrome*: Older, trophic changes; angiogram shows a lesion.
- *Disease*: Primary vasospastic disorder; young women.
- Allen and Brown's criteria:
  - Intermittent attacks, discoloration of acral parts.
  - Bilateral.
  - Absence of clinical occlusion.
  - Trophic, gangrene rare.
  - > 2 years of symptoms.
  - No other disease.
- Intra-arterial reserpine does *not* heal ulcers, but does help.
- Calcium channel blockers, aspirin, Persantine (dipyridamole), Trental (pentoxifylline).
- Thermal biofeedback good in 67%–92%.
- Digital sympathectomy (get pulse volume recordings first).

Thromboangiitis Obliterans (Buerger Disease)

- *Stop smoking.*
- Starts distal and progresses proximally.

Giant Cell Arteritis

- Older women.
- Biopsy temporal artery (polymyalgia rheumatica).
- Treat with high-dose steroids.

Takayasu's Arteritis

- Young women.
- Subclavian and axillary artery.
- Intimal proliferation.

CREST:

Calcinosis
Raynaud
Esophageal dysfunction
Sclerodactyly
Telangiectasias

Polyarteritis Nodosa

- Necrotizing arteritis with aneurysmal dilatations of small vessels.
- Commonly affects digital arteries and bifurcations.

Miscellaneous

- **Volkmann's ischemic contractures:** FPL and FDP are most commonly affected.
- **Compartment syndrome:** Pain with passive stretch is the most sensitive sign.
- **Scleroderma:** Treat recurrent ulcers with a sympathectomy.
- **Pulmonary hypertrophic osteoarthropathy:** ~12% have an associated bronchogenic carcinoma.
- **Systemic lupus erythematosus (SLE):** Soft tissue procedures fail.
- **CREST:** Calcinosis, Raynaud, Esophageal dysfunction, Sclerodactyly, Telangiectasias.

TENDONS

- Tendons have more collagen and are less viscoelastic than are ligaments.
- Thumb's *oblique pulley* is the most important, and *A1* is the next most important.
- Repair failure is most often due to gap formation (number of strands that cross the repair are most important).
- 34% of people do not have an FDS to small finger.

Extensor tendon subluxation is ulnar, and the long finger is most often affected.

Extensor Tendons

- Traumatic dislocation of the extensor tendon at MCP: The tendon will go ulnar; long finger most commonly affected.
- Extensor repair results: Best if no fracture; the most common problem is flexor lag; combination injuries do worse.

Flexor Tendons

- **Zone 1:** Distal to FDS insertion.
  - May advance up to 1 cm.
  - DIP contracture is the most common problem.
- **Zone 2:** "No man's land"; FDS insertion to fibro-osseous sheath.
- **Zone 3:** No pulleys; better results.
- **Zone 4:** Z-lengthen the transverse carpal ligament.
- **Thumb:** Preserve oblique pulley (A2 and A4 in digits).

Tendon Repair

- 15%–20% rerupture rate.
- 2 weeks is weakest time of repair (6–12 days).
- Epitenon suture adds 20% to repair.
- Four strands at least for early active range of motion (AROM).
- A4 over extensor tendon, while A2 pulley reconstruction goes under the extensor ligament.
- For distal FDP disruption with an intact FDS, fuse DIP and no repair (may attempt repair if patient's occupation requires a high level of manual dexterity).
- Flexor tendon repair: Active mobilization utilizes wrist extension and MCP joint flexion.
- Flexor tendon zone II: Early active motion improves tendon excursion.
- If repairing flexor tendons in carpal tunnel, repair transverse carpal ligament in a *lengthened* position.

Strength of tendon repair is related to the number of strands crossing the repair site.

Boutonniere Deformity

- Disruption of central slip, triangular ligament.
- Lateral bands migrate volarly.
- ORL and transverse retinacular ligament (TRL) develop contractures.
- DIP and PIP capsular contracture.
- Poor prognostic signs: Age > 45, fixed PIP contracture, associated fracture, prior surgery.
- Elson test: PIP 90 degrees and try extension.
- Statically splint in full extension.

Swan-Neck Deformity

- PIP extension, DIP flexion.
- **Treatment:**
  - At the DIP: SORL reconstruction.
  - At PIP: FDS tenodesis or lateral band translocation.

▶ REPLANTATION

Indications for replantation:

- Thumb amputation.
- Any amputation in a child.
- Multiple digits amputated.
- Wrist or forearm amputation with warm ischemic time < 6 hours.
- Individual digit amputation distal to FDS insertion.

Relative contraindications:

- Amputations distal to DIP joint or proximal to FDS insertion.
- Warm ischemia time > 6 hours for wrist/forearm and > 12 hours for digits.
- Crushed or mangled parts.
- Multiple level amputations.
- Atherosclerotic vessels.
- Mentally unstable patients.
- Replant steps: **BEFANV**
  - **B**ones, **E**xtensors, **F**lexors, **A**rtery, **N**erve, **V**ein.
  - Thumb, long, ring, small, then index.
  - Complications: Most common—infection; second most common—cold intolerance (up to 2 years postoperatively).
- Expect 10-mm 2-pt discrimination and 50% ROM.
- Leeches: Treat venous congestion (hirudin).
  - 8–12 hours of anticoagulation.
  - *Aeromonas hydrophila* infection is a risk.
- Forearm amputation: Do not replant if warm ischemia is > 6 hours.

Digit replant order of repair–

BEFANV

- **B**ones
- **E**xtensors
- **F**lexors
- **A**rtery
- **N**erve
- **V**ein

▶ AMPUTATIONS, FLAPS, AND SKIN GRAFTS

Fingertip Amputation

- Up to 1 cm^2 exposed skin; no bone exposed—can allow healing by secondary intention.
  - **Primary closure:** Worse with central; dog-ears do *not* go away.
  - **Volar V-Y flap**: For 25% fingertip amputations.

- **Cross-finger flap:** Release from flap at 10–14 days.
- **Split-thickness graft:**
  - Contracts.
  - Less durable.
  - Poor sensibility.
  - OK for dorsal hand.
- **Full-thickness skin graft:**
  - Minimal contraction.
  - Durable.
  - Better in palm and fingertip.
  - Better sensibility.

Dorsal hand: Utilize split-thickness grafts.

Palm and fingertip: Utilize full-thickness grafts (better sensibility and durability).

Vascularized Grafts

- Free fibula transfer: Six months to union; peroneal artery–based flap.
- Iliac crest: Deep circumflex iliac artery–based flap.

Flaps

- Complex wounds need flap coverage within 6 days to minimize complication rates.
- Flaps: Z-plasty longitudinal is aggregate gain, whereas transverse loss is not.
  - Random pattern flap not longer than the base's width or risk vascular problems.
  - If the motor nerve is not preserved, a muscle flap will atrophy to 50% of its original size.
- Flap anastomoses must be out of the zone of injury.
- **Moberg** flap: Thumb.
- **Cross-finger** flap: Volar aspect of digits.
- **Thenar** flap: Finger tips.

Thumb

- Groin flap is workhorse for thumb.
- Moberg advancement flap.
- FDMA flap (first dorsal metacarpal artery—branch of dorsal radial artery): Kite flap (can be an innervated flap).
- 3-cm length can be gained with thumb distraction osteogenesis.
- Pollicization: Congenital, need length:
  - EIP → EPL, EDC → APL, first volar IO → AP, first dorsal IO → APB.
- Thumb reconstruction: Wrap-around best duplicates appearance and size.
- Great toe: Provides mobility, growth potential, and very stable.
  - Second toe: Provides mobility, growth potential, yet less stable.
    - Same artery → first dorsal metatarsal artery, branch dorsalis pedis; 78% dorsal, 22% volar.

Thumb flap workhorse is the groin flap.

▶ NERVES

- **Meissner corpuscle:** Rapid adapting, *moving two-point discrimination* (2-PD), small discrete field, located along interdermal ridges.
- **Merkel cells:** Slow adapting, small discrete field, *static* 2-PD.
- **Pacinian corpuscles:** Rapid adapting, in subcutaneous tissue, large field, pressure sensation.
- Severe nerve compression leads to endoneurial fibrosis.

Moving two-point discrimination via Meissner corpuscles and static via Merkel cells.

Double Crush Phenomenon

- C6 radiculopathy and carpal tunnel syndrome.
- Thoracic outlet syndrome and cubital tunnel syndrome.

Order of Nerve Recovery

- Anesthesia, pressure (proprioceptive), pain (protective), moving touch, moving 2-PD (Meissner), static 2-PD (Merkel), threshold tests (monofilaments and vibration).
- *Threshold is lost first* and regained last.
- Sensory changes first because less myelin than motor nerves.

Electromyography (EMG)/Nerve Conduction Velocity (NCV)

- Fibrillation: Abnormal (single–muscle fiber activity).
- Sharp waves: Seen with fibrillation:
  - Fasciculations: Single–motor unit activity (good thing, relatively) indicates neuromuscular disorder.
  - Polyphasics: Indicates nerve will recover; often seen 2 months ahead of time.
  - Decreased *amplitude* = loss of functional axons.
  - Increased *latency* = demyelination.

COMPRESSION NEUROPATHIES

Neuropathy Risk Factors

- Diabetes
- Hypothyroid
- EtOH
- Peripheral edema

Median Nerve Compression

- **Carpal tunnel syndrome (CTS):**
  - Durkin's compression test is most sensitive (time with compression).
  - Semmes Weinstein most sensitive for *early* CTS.
    - EMG/NCS in CTS.
  - Distal motor latency > 4.5 seconds.
  - Distal sensory latency > 3.5 seconds.
  - Denervation = fibrillations at rest, positive sharp waves.
  - Edema and fibrosis is pathology (not inflammation).
  - 80% improve with injection (only 20% last 12 months).
  - Night pain is primary symptom cured; motor weakness does not improve significantly with decompression.
  - Primary reason for failure of decompression: Incomplete release of transverse carpal ligament.
- **Pronator syndrome:** Like CTS, yet no night pain, EMG positive at PQ and FPL.
- Locations of possible median nerve compression: Ligament of Struthers, supracondylar process, lacertus fibrosus, pronator teres, FDS.
  - **Supracondylar process:** Associated with median nerve compression (bony process points toward the joint).
  - Ligament of Struthers.

The main reason carpal tunnel release fails: Incomplete release.

- Bicipital aponeurosis.
- Pronator teres origin deep.
- Under origin of FDS.

- **Anterior IO nerve:** No sensory changes, lose function and vague forearm pain, motor loss without sensory loss (+/– pain); unable to do precision pinch.
  - EMG is diagnostic; rule out Parsonage-Turner syndrome.
  - Potential causes: Fibrous bands within pronator teres (PT), edge of lacertus fibrosus, enlarged bicipital bursa, and Gantzer's muscle (accessory head of FPL).

Median nerve compression can occur at the following: Ligament of Struthers, supracondylar process, lacertus fibrosus, pronator teres, and FDS.

Ulnar Nerve Compression

- **Cubital tunnel syndrome** causes: Arcade of Struthers, intramembranous septum, cubital tunnel, Osborne's ligament, *anconeus epitrochlearis* (Figure 6-1), FCU.
  - Poor prognosis if intrinsic atrophy exists.
  - Night sling with upper extremity in 45 degrees of elbow flexion and neutral forearm rotation.
  - FCU is the most frequent site of compression.
  - Medial antebrachial cutaneous nerve (MACN) is the most common injury after ulnar nerve release.
- **Ulnar tunnel syndrome:** Compression at Guyon's canal: The most common cause is ganglion.
  - Roof is the volar carpal ligament, floor is the transverse carpal ligament and pisohamate ligament.
  - Ulnar wall is hamate; radial wall is pisiform and adductor digiti minimi (ADM) muscle.
  - Common cause is ganglion from the triquetrohamate joint.
  - Location of compression:
    - If proximal compression: Mixed motor and sensory.
    - At hamate: Motor only.
    - Distal to hamate: Sensory only.
    - Pathology is proximal to wrist if sensation is out on dorsal ulnar hand.
- Distal humeral intra-articular fracture: The most common complication *ulnar nerve injury.*

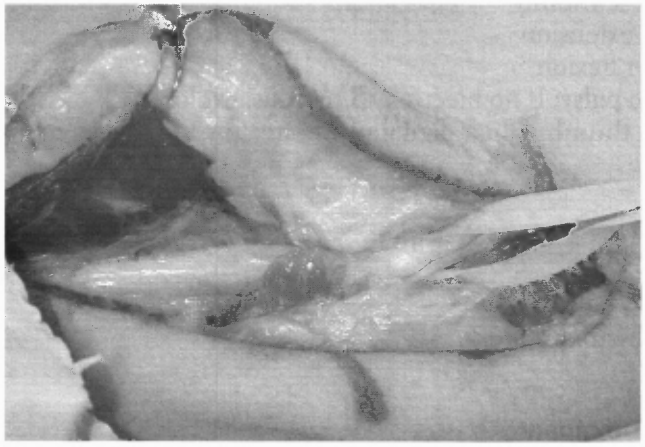

FIGURE 6-1. Ulnar nerve compression at the elbow due to an anomalous anconeus epitrochlearis.

Structures that must be released for full radial nerve release at the elbow—

FREAS

- **F**ascia at radiocapitellar joint
- **R**ecurrent radial artery
- **E**CRB
- **A**rcade of Frohse
- **S**upinator (distal border)

Radial Nerve Compression

- **Radial tunnel syndrome:** Pain without weakness; long finger extension test or resisted supination test; *normal* nerve studies, vague arm pain.
- **FREAS:** Fascia at radiocapitellar joint, **R**ecurrent radial artery, **E**xtensor carpi radialis brevis (ECRB), **A**rcade of Frohse, **S**upinator (distal border); EMG/NCV is *not* helpful here.
- **Posterior interosseous nerve (PIN) syndrome:** Pain at elbow and weakness with radial drift.
  - EMG/NCV abnormal.
  - Decompress if no recovery at 3 months.
- **Wartenberg syndrome** (cheiralgia paresthetica): Compression of the sensory branch of the radial nerve as it exits the brachioradialis (BR); compression between ECRL and BR with pronation.
- BR muscle splitting approach is the most direct route to the arcade.
- **Thompson** (dorsal) is best for entire supinator exposure.
- **Thoracic outlet syndrome:** *Anterior scalene* is the offending muscle (between this and medial scalene); travels with artery, not vein (vein is anterior).

▶ NERVE INJURY

- **Neurapraxia:** Absent Tinel's; will recover; axon intact.
- **Axonotmesis:** Axon ruptured, nerve sheath intact; start sprouting in 4–6 weeks.
  - Polyphasics with low amplitude show healing.
  - Advancing Tinel's.
- **Neurotmesis:** Complete transection of the nerve and sheath.
- **Wallerian degeneration:** Breakdown of myelin sheath and axon.
- Age of the patient is the most significant outcome determinant (age 40 is cutoff) of nerve injury.
- Tension increase in nerve of 8% elongation results in 46% *decreased* perfusion.
- Nerve conduits are as good as grafting but are limited to 3-cm defects.
- **Horner syndrome** is associated with C8–T1 root avulsion.
- **Restore function to plexus** (most important to least important function to restore):
  - Elbow flexion
  - Shoulder abduction
  - Hand sensibility
  - Wrist extension
  - Finger flexion
- **Obstetric palsy:** If no biceps by 3 months, explore.
- **Bowler's thumb:** Ulnar digital nerve; treat by modifying equipment (bowling ball).

Nerve recovery probability main determinant is age of the patient.

▶ CONGENITAL HAND DISORDERS

- **Preaxial**—radial side.
- **Postaxial**—ulnar side.

Autosomal Dominant

- Postaxial (ulna) polydactyly.
- Camptodactyly.

- Brachydactyly.
- Symphalangism.
- Triphalangeal thumb.
- Lobster claw hand.

Duplication

- Preaxial polydactyly: Thumb duplication.
- Postaxial polydactyly: Small finger duplication.
  - Blacks: More common and usually without genetic problem.
  - Whites: There usually is an associated genetic problem.

Radial Club Hand

- Most common is type IV wherein the entire radius is absent; 50% bilateral.
- TAR (**T**hrombocytopenia, **A**bsent **R**adius), Fanconi's (aplastic anemia), Holt-Oram (cardiac septal defects):
  - Fanconi's anemia or TAR: Get hematology workup.
  - Holt-Oram: Get cardiac workup.
- Chromosomes 18, 13, 17, 21.
- **VATERR**: **V**ertebral anomaly, **A**nal atresia (imperforate anus), **T**racheal–Esophageal fistula, **R**adial ray deficiency, **R**enal abnormalities.
  - Centralization.
  - No elbow function, no surgery.
  - Absent radial artery and nerve.
  - *Median nerve* will be on radial side.

Ulnar Club Hand

- Much more rare.
- Associated with other musculoskeletal defects.

Radioulnar Synostosis

- 60% bilateral.
- Operate at age 5, if needed.

Syndactyly

- Most common congenital hand disorder.
- Simple vs. complex.
- Complete vs. partial.
- 5/15/50/30 rule.
- Release at 18 months to 5 years (size issues).

Symphylangism

- Ankylosis of PIP (congenital stiffness).
- Associated with correctable deafness.
- Associated with Poland syndrome, brachydactyly, and Apert syndrome.

The most common congenital hand disorder is syndactyly.

Camptodactyly

- Congenital digital flexion of small finger PIP.
- Abnormal lumbrical or FDS insertion.

Hypoplastic Thumb

- Check for CMC joint presence.
  - If absent, need amputation.
  - If present, consider reconstruction.
- Wassel classification.

Flexed Thumb

- Congenital trigger thumb:
  - At IP joint only.
  - Observe for 12 months, then release A1 pulley.
- Congenital clasped thumb:
  - Initial treatment: Stretch.
  - Operative treatment: EIP to EPL transfer.

Pollicization

- First palmar IO → adductor pollicis.
- First dorsal IO → APB.
- EIP → EPL.
- EDC index → APL.

Elbow reconstruction patients benefit from one in extension and the other in flexion (mouth and perineum).

Arthrogryposis

- Congenitally curved/stiff joints; motor unit problem.
- Neurogenic, 90%.
- Myopathic, 10%.
- Need one elbow in flexion, one in extension, and wrist extension.

Poland Syndrome

- Hand hypoplasia.
- Unilateral short fingers.
- Simple complete syndactyly.
- Absence of sternocostal head pectoralis major muscle.

Apert Syndrome

- Spoon hand, acrocephalosyndactyly.
- Acrocephaly.
- Hypertelorism.
- Bilateral complex syndactyly with symphalagism.
- *Ring, index, and long fingers share a nail.*

Madelung's deformity is caused by an ulnar volar distal radial tether.

Madelung's Deformity

- Undergrowth (tether) of the *ulnar volar* distal radial epiphysis.
- Lose supination and get ulnocarpal impaction.
- Patients present as adolescents.

Miscellaneous

- **Central deficiency:** Cleft hand—involves feet too (different from symbrachydactyly).
- **Symbrachydactyly:** Central nubbins between the digits.
- **Acrosyndactyly:** Distal fused with fenestration (Apert syndrome).
- **Clinodactyly:** Congenital curvature of digit in radioulnar plane.
- **Kirner's deformity:** *AP* curvature (as opposed to clinodactyly)—apex dorsal.

▶ TENDON TRANSFERS

- Age is the leading prognostic factor (worse after age 30); location is the second leading factor; distal better than proximal.
- Delayed repairs lose 1% of nerve function per week delay (after third week).
- Lose one motor grade with transfer (thus should transfer only M5).
- Epineural repair = fascicular repair.
- Group fascicular repairs (three indications)—distal forearm median nerve, ulnar nerve, and sciatic nerve in thigh.

Severity of Injury

- Horner's sign: Often 2–3 days after injury (correlates with C8–T1 root avulsion).
- Severe pain in an anesthetic limb could indicate a root avulsion.
- Lack of rhomboid function could indicate root avulsion.
- Sensory and motor evoked potentials better than standard EMG/NCV.
- Early surgical intervention (3 weeks to 3 months):
  - Total or near total plexus injury.
  - High-energy injury.
- Late surgical intervention (3–6 months):
  - Low-energy injury.
  - Partial upper-level palsy.
- Surgery before 6 months is essential (if it is to be done).
- Isolated C8–T1: Best to do early tendon transfers.

Upper extremity reconstruction: First priority is elbow flexion.

Surgical Priorities

- Elbow flexion (musculocutaneous nerve).
- Shoulder stabilization (suprascapular nerve).
- Brachiothoracic pinch (pectoral nerve).
- Sensation C6–7 (lateral cord).
- Wrist extension and finger flexion (lateral and posterior cords).

Excursion 3-5-7 Rule

- 3 cm excursion: Wrist flexors, wrist extensors.
- 5 cm excursion: EDC, FPL, EPL.
- 7 cm excursion: FDS, FDP.

Cerebral Palsy (CP)

- Wrist extension by *Green transfer*, which is FCU to ECRB around ulna.

Radial Nerve Transfers

- PT to ECRB for wrist extension—workhorse for transfers.
- FDS middle, FDS ring: Second choice for wrist extension.
- FCR to EDC for finger extension.
- Thumb extension: FCU or PL (crosses two joints and thus makes up for short excursion).
- PL or FCU for EPL, EIP, APL, EPB.

Pin Palsy

- Wrist extension is intact; need finger and thumb extension.
- FCR to EDC for finger extension.
- PL to EPL for thumb extension.

Opposition Transfers

- **FDS ring** → (pulley) FCU—most useful and anatomic.
- **EIP** → ulnar (Burkhalter) best for combined median and nerve injury, *transfer EIP → APB*.
- **Abductor digiti quinti (ADQ)** → ulnar (Huber—most for congenital).
- **PL** → none, gives worst function (Camitz).

Low Ulnar Nerve Palsy

- Need MCP flexion in the ring and small fingers, as well as adduction in the thumb and index and small fingers.
- FDS ring, middle → MCP ring and small.
- EIP → thumb adductors, index abductors, small adductors.

High Ulnar Nerve Palsy

- Do not use FDS ring or FDS small.
- Side-to-side transfer of FDP.

Commonly Tested Transfers

- PT → ECRB (or FDS middle, FDS ring to ECRB).
- FCU → EDC (or FCR to EDC).
- PL → EPL (or FCU to EPL).
- ECRL → ECU (rheumatoid).
- FCU → ECRB (CP patient, Green transfer).

HAND INFECTIONS

Eikenella corrodens *is often the offending organism in fight bite wounds.*

- **Chronic paronychia**: *Candida* is main culprit; treat with clotrimazole and tolnaftate.
- **Fight bite**: Think about *Eikenella corrodens*, not primary agent—penicillin; most common is *Staphylococcus* or alpha-hemolytic streptococci.
- **Rose thorn**: *Sporothrix schenckii*: Treat with potassium iodide topical or oral itraconazole (better choice).
- **Felon treatment**: Incision and drainage (I&D) through longitudinal volar incision.

Necrotizing Fasciitis

- Group A beta-hemolytic strep—32% mortality rate.
- Emergent aggressive I&D and antibiotics (penicillin, metronidazole, clindamycin, aminoglycoside).

Pyoderma Gangrenosum

- Treat with steroids, not antibiotics.
- Question will say failed multiple courses of antibiotics.

Parona's Space

- Potential space between PQ and FDP connects thumb and small finger.
- Pus likes to track here.

Herpetic Whitlow

- More common on hands of health care workers.
- Common infection in a toddler's hand.

Herpetic whitlow is common in health care workers and children.

DUPUYTREN DISEASE

- **Risk factors:**
  - EtOH
  - Diabetes mellitus (DM)
  - Epilepsy
  - Chronic obstructive pulmonary disease (COPD)
- *Myofibroblast.*
- Autosomal dominant.
- Epithelioid sarcoma: Can cause confusion (more invasive lesion).
- Northern European descent.
- **Anatomy:**
  - **Pretendinous cord**—MCP contracture only.
  - **Spiral cord**—PIP contracture (pulls neurovascular [NV] bundle midline).
    - Formed by lateral digital sheath, spiral band, pretendinous band, and Grayson's ligament.
    - Remember in anatomic position *Grayson's* are to the *ground* and *Cleland's* are to the *ceiling*.
    - Natatory ligament is the only one *not* part of spiral cord.
  - Best predictor of central NV bundle displacement is presence of PIP joint flexion contracture (77% PPV).
- **Stages:**
  - **Proliferative stage:** Large myofibroblasts, minimal extracellular matrix, very vascular, lots of gap junctions.
  - **Involution stage:** Dense myofibroblasts, **collagen type III** > I.
  - **Residual stage:** Myofibroblasts disappear; smaller fibrocyte dominates.
- **Treatment:**
  - Physical therapy or splints do *not* help.
  - Do not excise nodules.
  - Partial fasciectomy is the most often used technique; 50% recur, but not recurrent contracture.

- Open palm technique has *lowest complication* rate (not better outcome).
- Night splints postoperatively, but not preoperatively.
- PIP release does *not* work.
- Concomitant carpal tunnel release is a bad idea; leads to worse postoperative flares.

▶ HAND TUMORS

Dupuytren's release should not include a concomitant carpal tunnel release.

Giant Cell Tumor of Tendon Sheath

- 10% recur.
- Off flexor sheath is most common.
- Marginal excision.

Glomus tumor triad includes pinpoint pain, cold intolerance, and bluish color.

Neurilemmoma

- *Most common peripheral nerve tumor.*
- Eccentric.
- Easily shelled out from the nerve.
- Marginal excision.

Glomus Tumor

- Small; 50% subungual and 50% in fingertip.
- Pinpoint pain and tenderness, cold intolerance, bluish color.

Most common hand mass is a ganglion, with dorsal more common than volar.

Ganglion

- Most common hand mass.
- Aspiration 59% effective.
- Dorsal > volar (70:30).
- Dorsal ganglion: Typically from scapholunate ligament.
- Volar ganglion: Radiocarpal or STT ligament.
- Volar retinacular ganglion cyst: At MCP flexion crease.

The most common malignancy period in the hand is squamous cell carcinoma. The most common malignancy of bone in the hand is chondrosarcoma. The most common soft tissue sarcoma of the hand is epithelioid sarcoma.

Calcinosis

- Soft tissue calcium.
- Seen in FCU, MCP joints.
- RA, SLE, scleroderma (treat underlying disease).

Carpal Boss

- Base of the capitate and third metacarpal osteophyte.
- **Treatment:** Observe or excise and fuse.

Enchondroma

- Symmetric fusiform enlargement of proximal or middle phalanx.
- **Treatment:** Curettage and bone graft.

Osteoid Osteoma

- Phalanx, carpus.
- Worse with EtOH, better with aspirin.

Squamous Cell Carcinoma

- *Most common malignancy in the hand.*
- Firm ulcerative lesion.
- Slow growing.
- **Treatment:** Wide resection with radiation.

Melanoma

- Often thin (< 1 mm).
- Excise with at least a 1-cm margin.
- Sentinel node biopsy.

Epithelioid Sarcoma

- Most common soft tissue sarcoma of the hand (beware Dupuytren's).
- **Treatment:** Wide excision, spread via lymphatics—radical margin.

Most common metastasis distal to the elbow and knee is lung, and next is renal.

Miscellaneous

- **Epidermal inclusion cyst:** Associated with prior penetrating trauma (keratinizing tissue gets deep).
- **Pyogenic granuloma:** Prior trauma, treat with *excision*.
- **Metastasis:** Lung cancer is the *most common* to metastasize to *hands and feet*.
- **Chondrosarcoma:** Most common malignancy *of bone* in the hand.
- **Bowen disease**: Interepidermal squamous cell in nail fold.

▶ HAND TRAUMA

Mallet Finger

- Disruption of extensor tendon insertion into distal phalanx (forced flexion).
- Treat with DIP extension splint.
- Surgery only for volar subluxation of the distal phalanx.

Dorsal PIP dislocations occur more often than volar, yet volar require more stringent treatment protocols.

Dorsal Dislocation of PIP

- Most common.
- Volar plate injured.
- Reduce and buddy tape, begin ROM.

Volar Dislocation PIP

- Central slip rupture.
- Palmar plate and LCL rupture.
- Pin in extension, 3–4 weeks at most.
- No good/excellent results.

Rotary Dislocation

- Condyle trapped between central slip and lateral band.
- Reduce via MCP and PIP flexion; translate middle phalanx on proximal phalanx; *no traction* (or get Chinese finger trap effect).

Lateral PIP Dislocation

- Torn collateral ligament can prevent reduction.

Dorsal MCP Dislocation

- Entrapped *volar plate* can lead to difficult reduction.

MCP Hyperextension Dislocations

- Reduce by flexing wrist and translate MCP (no traction).
- MCP complex dislocation: Proximal phalanx is parallel to metacarpal; volar or dorsal exposure.
- Volar approach is the most direct, yet beware of radial digital nerve.
- Dorsal approach is less risky, yet exposure is not as good.

Gamekeeper's thumb was named for those who would break a fowl's neck while hunting and sustain injury to the thumb's UCL.

Gamekeeper's Thumb

- Stener lesion is likely if > 35 degrees of side-to-side difference with MCP flexed.
- Adductor aponeurosis traps ulnar collateral ligament (UCL).

Simple Finger Fracture

- Initiate motion by 4 weeks no matter what or it gets stiff (do not wait for callus).
- *Rotation* is least well tolerated in finger fractures.

Metacarpal Fracture

- Physical exam to check for malrotated metacarpal fractures (Figure 6-2); have patient clench hand, and all fingertips should point to the scaphoid.
- There is a 7-degree extensor lag for every 2-mm *shortening*.
- X-ray for *fourth and fifth metacarpal* fractures is a 30-degree *pronated* lateral (get a 30-degree *supinated* lateral for the *index*); ECU is deforming force.

Bennett's fracture deforming force is the abductor pollicis longus.

Scaphoid Fracture (Figure 6-3)

- Usually from fall on outstretched hand with wrist dorsiflexed and radially deviated.
- Snuff box tenderness.
- Plain x-ray may not show a fracture for several days.
- CT scan or bone scan better early studies in the face of normal x-ray.
- Transverse fracture can disrupt retrograde blood supply to proximal pole (nonunion and AVN).

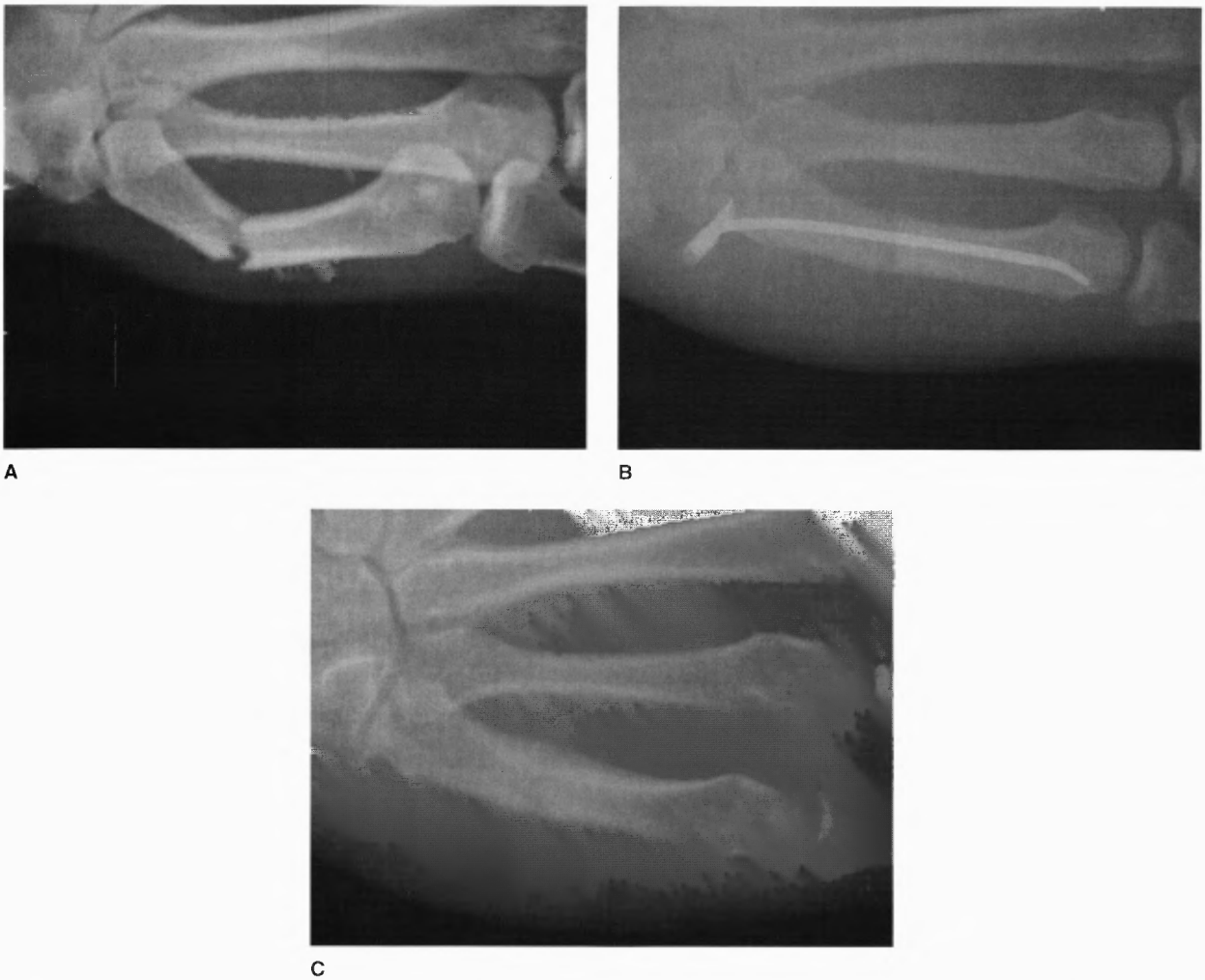

FIGURE 6-2. Metacarpal fracture. (A) Metacarpal fracture with malrotation that could not be retained in a reduced position. **(B)** The same fracture has been pinned to maintain reduction and correct rotation. **(C)** The same fracture after pin removal.

- Treatment:
  - For truly nondisplaced fractures: Cast for a minimum of 12 weeks (usually requires longer) or percutaneous pinning.
  - For any degree of displacement: Compression screw.
  - For nonunion: Bone graft and compression screw.
  - Humpback deformity (dorsal gaping) can result from nonunion.
- Scaphoid nonunion: First sign of OA is at distal pole scaphoid and radial styloid.

Elbow

- Heterotopic ossification (HO) after ORIF: Now earlier release with resection (<8 weeks).
- Supracondylar humerus fracture with postoperative cubitus varus: The most common indication for reoperation is poor cosmesis.

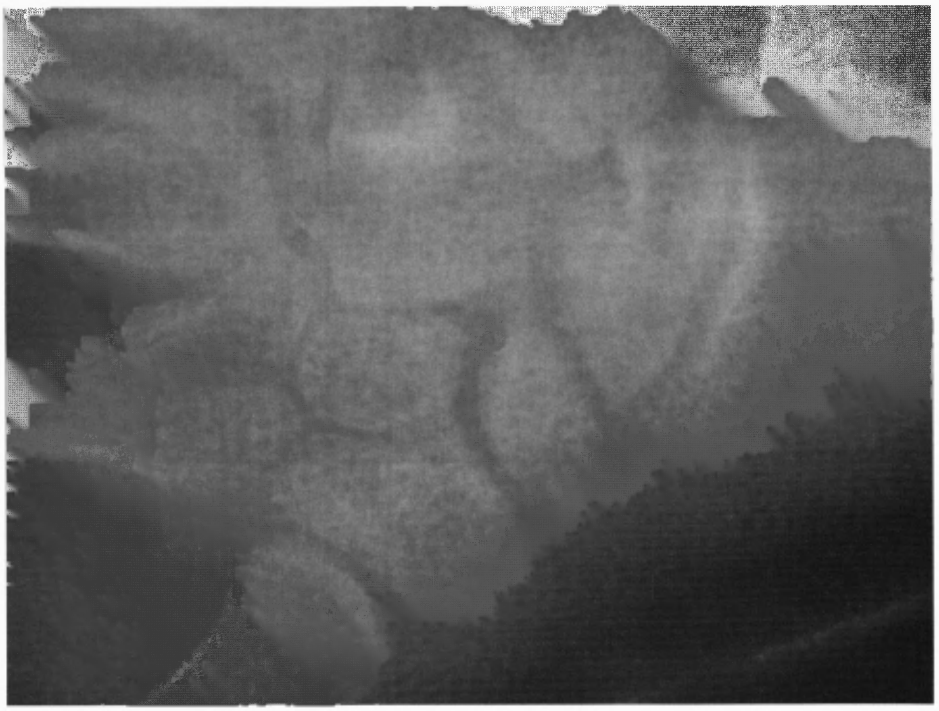

FIGURE 6-3. A midwaist scaphoid fracture. This is displaced and requires fixation with compression screws.

Miscellaneous

For every 2 mm of shortening resulting from a metacarpal fracture, there can be 7 degrees of extensor lag.

- **Bennett's fracture**: Deforming force is **APL**; closed reduction and pin.
- **Rolando fracture**: A comminuted Bennett's fracture; ORIF vs. *traction*.
- Hook of hamate fracture (golfer, baseball player): Splint, then excise fragment if not healed and symptomatic.
- **DRUJ** becomes incongruent at > 20 degrees dorsal tilt of distal radius fractures.
- **Fusion of digits**: DIP, PIP, MCP—index (0, 40, 25), long (0, 45, 30), ring (0, 40, 35), small (0, 50, 40).
- **High-pressure injection injuries**:
  - Material injected most important factor in outcome.
  - Worse prognosis if patient presents > 10 hours after injury.
  - Oil-based paint is worst.
  - 45%–50% overall amputation rate.
  - 80% amputation rate with paint.
  - Treatment: Exploration, multiple debridements, IV abx (broad spectrum), leave wounds open.

CHAPTER 7

Foot and Ankle

Foot Anatomy 151

- Nine Foot Compartments 151
- Foot Muscle Layers (Superficial [Plantar] to Deep) 151
- Talus Vascular Supply 151
- Posterior Tibial Tendon (PTT) 151
- OS Trigonum Syndrome 151
- Sural Nerve 151
- Peroneus Brevis 151
- Lisfranc Ligament 151
- X-Ray Views 152

Ankle 152

- Ankle Sprain 152
- Osteochondral Lesions of the Talus 153
- Snowboarder's Ankle Injury 153
- Ankle Arthroscopy 153

Heel Pain 153

- Plantar Fasciitis 153
- Plantar Fibroma 153

Great Toe 153

- Hallux Rigidus 153
- Hallux Valgus (HV) 153
- Hallux Varus 156
- Turf Toe 156
- Lesser Toe Deformity 156
- Sesamoids 157
- Tendon Disorders 157
- Achilles Tendon Injury 158
- Peroneal Tendon Injury 158

Foot Nerve Topics 158

- Morton's Neuroma 158
- Tarsal Tunnel Syndrome 159
- Baxter's Nerve 159

Medial Plantar Nerve Entrapment 159
Common Peroneal Nerve Palsy 159
Neurologic Disorders 159
Charcot-Marie-Tooth (CMT) Disease (Hereditary Motor Sensory Neuropathy [HMSN]) 159
Stroke (Cerebrovascular Accident [CVA]) 160
Polio 160
Cavus 160
Arthritic Disease 160
Red, Swollen MTP Joint 160
Rheumatoid Arthritis (RA) 161
Gout 161
Pseudogout (Calcium Pyrophosphate Disease [CPPD]) 161
Seronegative Spondyloarthropathies 161
Total Ankle Arthroplasty 161
Arthrodesis 161
Foot and Ankle Infection 162
Lyme Disease 162
Madura Foot 162
Onychocryptosis 162
Frostbite 162
Shoe Nail Puncture 162
Necrotizing Fasciitis 162
Diabetic Foot (and Charcot Neuropathy) 162
Foot Tumors 163
Congenital Foot Topics 163
Amputations 163
Foot and Ankle Trauma 163
Ankle 164
Calcaneus 164
Talus 164
Navicular 164
Metatarsals 164
Lisfranc Injury 164
Gait, Prosthetics, and Rehabilitation 165
Gait 165
Inserts 165
Orthoses 165

▶ FOOT ANATOMY

Nine Foot Compartments

- Medial, superficial, lateral, calcaneal, adductor, interossei (4).
- Deep calcaneal compartment of the quadratus plantae often has the highest pressures.

Foot Muscle Layers (Superficial [Plantar] to Deep)

- First: Abductor hallucis, flexor digitorum brevis, abductor digiti minimi.
- Second: Quadratus plantae, lumbricals.
- Third: Flexor digiti minimi, FHB, adductor hallucis brevis.
- Fourth: Dorsal and plantar interossei.
- *Hint:* 3-2-3-2 (the number of muscles per layer).

Main blood supply to the talus is via the artery to the tarsal canal.

Talus Vascular Supply

- Artery to tarsal canal: *Primary* supply and is from posterior tibial artery.
- Artery sinus tarsi: From peroneal artery.
- Deltoid branches from posterior tibial artery as well and no muscle attachments.
- **Watershed zone:** Central one-third.

Posterior Tibial Tendon (PTT)

- Poorest blood supply is between navicular insertion and distal medial malleolus.

OS Trigonum Syndrome

- Posterior ankle impingement in dancers (associated with flexor hallucis longus [FHL] tendinitis).
- FHL is lateral to the os trigonum.

Sural Nerve

- Crosses from medial to lateral at musculotendinous junction of Achilles.

Peroneus Brevis

- Unlocks transverse tarsal joint and everts hindfoot (opposes posterior tibialis).
- Longitudinal tears most often occur at the fibular groove.
- Runs closer to fibular than longus in the groove.
- Repair of the superior peroneal retinaculum is required if conservative measures fail (Figure 7-1).

Lisfranc Ligament

- Runs from medial cuneiform to second metatarsal, plantar.
- Repair must be anatomic as any displacement predisposes degeneration.

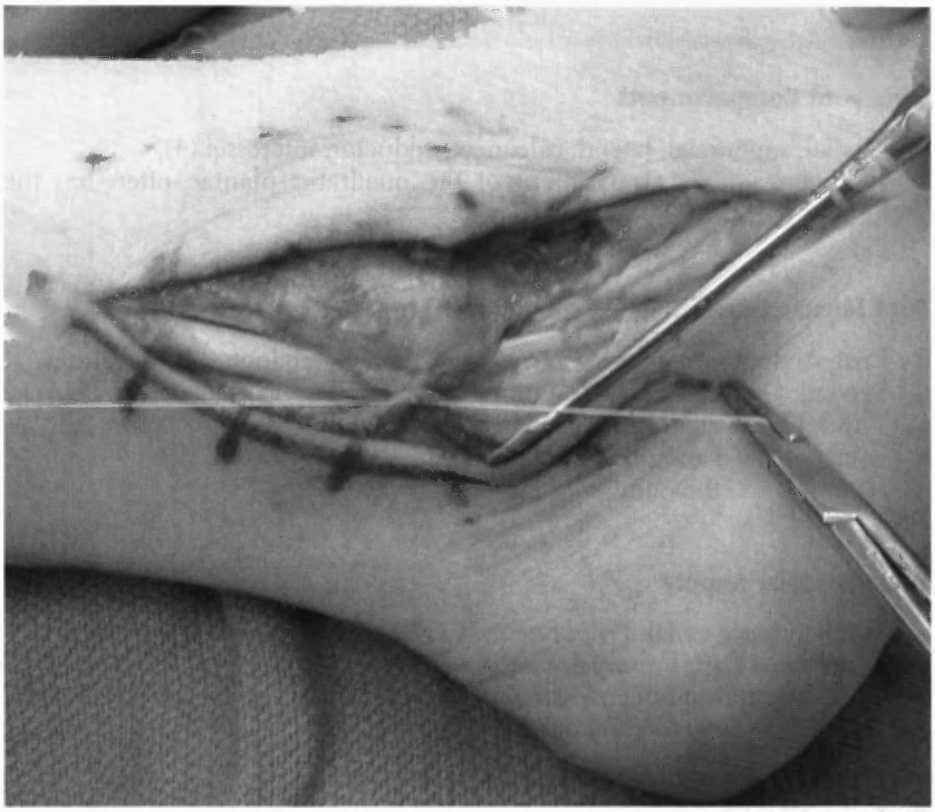

FIGURE 7-1. Repair of the superior peroneal retinaculum after an acute injury did not respond to conservative treatment.

X-Ray Views

- Calcaneus views: Bohler's angle (25–40 degrees), angle of Gissane (120–145 degrees), Broden's view, Harris heel view.
- Canale view: Visualize the talar neck (maximum plantar flexion with foot pronated 15 degrees).
- Broden's view: Posterior facet of subtalar joint.

ANKLE

Ankle Sprain

- Primary ankle stabilizer is the **deltoid ligament**.
- Ankle dorsiflexion results in the fibula's moving proximally and external rotation (ER).
- **Anterior talofibular ligament (ATFL)** prevents anterior translation in ankle plantar flexion. 90% are tight in plantar flexion; calcaneal fibular ligament (CFL) is tight in dorsiflexion.
- **Basset's ligament:** Most inferior aspect of the anterior tibiotalar ligament. Thickened in chronic ankle sprains; treat with scope debridement.
- **Modified Brostrom:** Repair ATFL and CFL; reinforce with lateral talocalcaneal ligament and/or inferior retinaculum.
- **Subtalar instability:** Inferior retinaculum (Gould procedure) or peroneus brevis procedure.

Osteochondral Lesions of the Talus

- Anterolateral lesions are shallow and results of *acute trauma*.
- Posteromedial lesions are deep and results of *chronic injury*.

Osteochondral lesions of the talus: Acute trauma occurs anterolaterally, while chronic are more often posteromedial.

Snowboarder's Ankle Injury

- Lateral process of the talus fracture; may need a computed tomographic (CT) scan to confirm.
- **Mechanism:** Dorsiflexion, axial load, inversion, ER.
- Open reduction and internal fixation (ORIF) (if large enough fragment) vs. excision.

Ankle Arthroscopy

- Most common nerve injury is to the superficial peroneal nerve at the anterolateral portal.
- Anteromedial portal: Beware of the saphenous nerve and vein.

▶ HEEL PAIN

Plantar Fasciitis

- Associated with Achilles tendon contracture.
- First branch lateral plantar nerve (medial calcaneal nerve).
- Utilize stretching (night splints) and silicone inserts first.
- Ultrasound is an option.
- Endoscopic plantar fascia release: The most common complication is plantar nerve injury.
- Plantar fascia's central *component* is the strongest.
- Consider Reiter's and other rheumatologic disorders.

Plantar Fibroma

- Observe if at all possible because of the high recurrence rate.
- If operation is necessary, excise the entire plantar fascia because 60% recur with local resection only.

▶ GREAT TOE

Hallux Rigidus

- Worse *without* shoes because metatarsophalangeal (MTP) joint moves more (hallux valgus worse with shoes).
- Dorsal one-third: Cheilectomy works for most.
- If for severe osteoarthritis (OA), MTP fusion is the preferred treatment.
- Surgical intraoperative goal is 70 degrees of dorsiflexion, and patient should retain half that at 2 months (35 degrees) (Figure 7-2).

Hallux rigidus has pain with plantar flexion due to tendon abrasion over dorsal osteophytes.

Hallux Valgus (HV)

- Maternal predisposition.
- First problem is valgus deviation, then attenuated medial structures, varus metatarsal (MT) head deviation (sesamoid "subluxation"), hallux pronation, and finally lateral contracture.

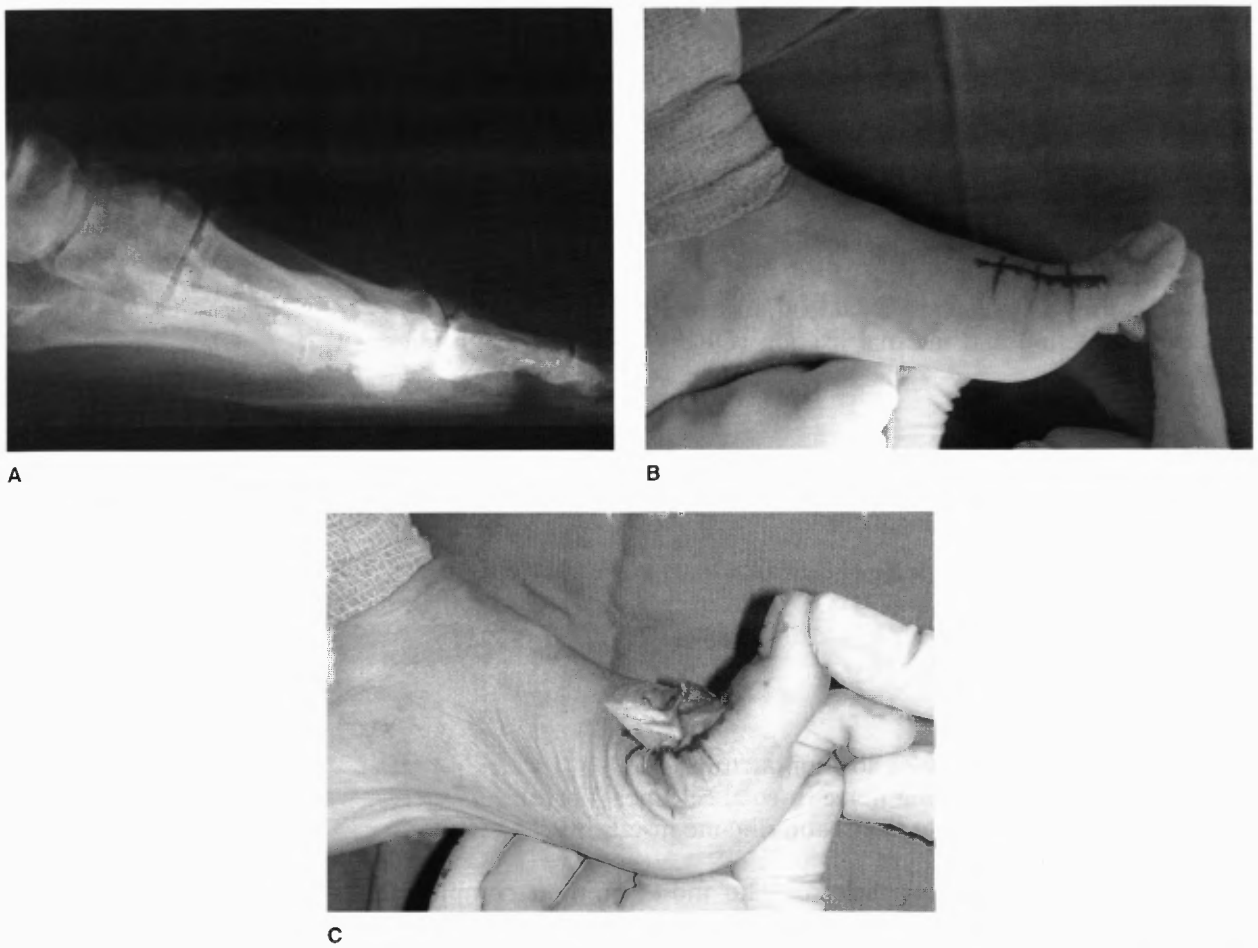

FIGURE 7-2. Hallux rigidus. Lateral radiograph demonstrating dorsal osteophytes typical of HR **(A)**. Preoperative ROM **(B)** and intraoperative ROM **(C)** demonstrated on the clinical photographs. The goal is to get 70 degrees intraoperative ROM and to maintain at least half postoperatively.

- **Radiographic findings:**
  - Distal metatarsal articular angle (DMAA): Normal 6–10 degrees.
  - MTP angle: Normal < 9 degrees; abnormal if > 15 degrees.
  - Intermetatarsal angle (IMA): > 9 degrees is abnormal.
- **Congruent joint:** If DMAA is high (> 10 degrees), do *not* need to do lateral release, just osteotomy.
- **Surgical options** (see **Figure 7-3**):
  - Silver simple bunionectomy (rarely performed alone).
  - Distal osteotomy: Need congruent joint (no lateral release for this procedure or will increase risk of avascular necrosis [AVN]).
  - Chevron for smaller deformity.
  - Mitchell: Shortening of MT; for larger deformity, not performed often.
- Nerve at risk: Dorsomedial cutaneous branch of the superficial peroneal nerve.
- **Incongruent joint: Modified McBride:** Leave lateral sesamoid (higher incidence of hallux varus if lateral sesamoid is taken).
  - Lateral release (adductor, lateral capsule, intermetatarsal ligament).
  - Medial imbrication.
  - MT osteotomy.

Nerve at risk in bunion surgery: Dorsomedial cutaneous branch of the superficial peroneal nerve.

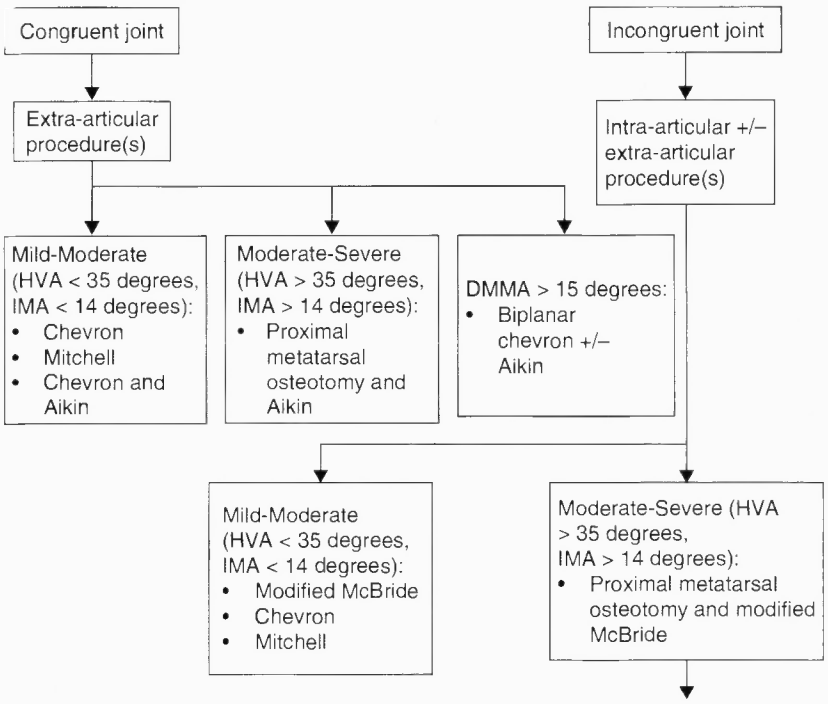

FIGURE 7-3. Quick reference: surgical decision-making for adult hallux valgus.

- **MT osteotomy:**
  - Proximal: Crescentic, chevron, wedge.
  - Shaft: Ludloff.
- **Joint resection** (Keller bunionectomy): Resect medial eminence and take off proximal phalanx.
  - Indications: Ulcer, elderly, or MTP degenerative joint disease (DJD).
  - Can cause cock-up toe, recurrence, or transfer metatarsalgia.
- **Fusion:** Do not add an osteotomy because the IMA will lessen with time.
- **Lapidus:** First tarsometatarsal (TMT) fusion if hypermobility here (look for a plantar gap on lateral x-ray).
  - HV and hypermobile first ray: Lapidus procedure (first TMT fusion) and distal soft tissue procedure.
- **HV double osteotomy:** Congruent MTP joint with HV.
- **Special circumstances:**
  - First TMT instability (hypermobile): First TMT fusion and modified McBride.
  - MTP arthritis.
  - Young active patientt: MTP fusion.
  - Elderly sedentary: Keller resection arathroplasty.
  - Spasticity, CP, RA: MTP fusion.
- **Juvenile hallux valgus** correction: Most common complication is *recurrence*.
  - Typically congruent joint with increased DMAA (> 14 degrees).
  - *Nonoperative treatment* is first choice, but if operating, osteotomy must be used.
- **Special cases:**
  - **Rheumatoid arthritis** (RA) treated with HV fusion and lesser MT head resections: The most common complication is plantar callosities.
  - **Cerebral palsy** patient with HV needs a fusion.

In juvenile hallux valgus, the most common operative complication is recurrence.

  - **Down syndrome** with HV: Operative treatment of choice is fusion.
  - Dancer with HV: Delay surgery until career is complete, or else the career will be over sooner than the patient may want.
  - Neuropathic ulcer of the great toe earns a Keller resection arthroplasty as this offloads and shortens.
- Typically, if a proximal valgus and a distal varus osteotomy is performed, then do not do soft tissue work.
- Severe HV (often defined as > 15 degrees and an incongruent joint) necessitates distal soft tissue procedure with proximal MT osteotomy.
- **Failed, painful hallux valgus surgery:** MTP fusion.

Hallux Varus

- Hallux varus is the most common complication from HV surgery. Reasons include:
  - Overcorrection of the IMA.
  - Too much medial eminence resection.
  - Overplication of medial structures.
  - Excessive lateral release.
  - Overpull of the abductor hallucis against an incompetent lateral ligamentous complex.
  - Excision of the fibular (lateral) sesamoid.
  - Medial displacement of the tibial (medial) sesamoid.
  - Excessive varus postoperative dressing.
- Flexible hallux varus deformity can be reconstructed with extensor hallucis longus (EHL) or extensor hallucis brevis (EHB) tendon.

Turf Toe

Turf toe is a plantar plate injury at the insertion on the proximal phalanx.

- Dorsiflexion sprain.
- The *plantar plate* is the main stabilizer of the MTP joint.
- Tear is at the *insertion* of the plantar plate on the proximal phalanx, not from the MT.
- Turf toe with recurrent symptoms is often due to incompetent sesamoid complex.

Lesser Toe Deformity

- **Bunionette:** Resect lateral head, osteotomy but first try new shoes.
- **Hammer toes:** Reducible MTP dorsiflexion, proximal interphalangeal joint (PIP) flexion deformity.
  - Dorsal subluxation of the interossei.
  - Treatment: Flexor-to-extensor transfer.
- **Claw toes:** PIP flexion, MTP hyperextension (*irreducible*), +/– distal interphalangeal joint (DIP) flexion.
  - Dorsal subluxation of the interossei.
  - Capsule release with bony work; *plantar plate* disorder.
- Claw toe in Charcot-Marie-Tooth (CMT): Flexor digitorum longus (FDL).
- Claw toe and hammer toe: Dorsal subluxation of interossei.
- Claw toe vs. hammer toe: Claw toe has dorsiflexion at MCP joint.
- Treatment: Weil shortening osteotomy.
  - RA: Metatarsal head resection.
  - Spasticity: PIP fusion +/– FDL tenotomy.

- **Mallet toe:** DIP flexion deformity, end bearing callus, nail pain. Treat with toe pads, DIP resection, fusion, FDL tenotomy.
- **MTP synovitis**—often at second MT head:
  - Associated with HV, long second MT, and close second-third MT heads.
  - *Not* a second-third space neuroma.
  - Positive Lachman on exam.
  - If unstable, first treat with steroid injection and stiff shoe (rigid steel shank, rocker bottom).
  - Flexor-to-extensor transfer for painful and unstable second MTP joint (Girdlestone-Taylor procedure); add extensor lengthening and debridement.
- **Neuroma:** Third-fourth web space; feels better with shoes off.
  - At second-third web space, think synovitis.
  - ~14% failure rate of neurectomy (adhesions or wrong diagnosis).
    - Intermetatarsal ligament does redevelop.
    - Release intermetatarsal ligament if more than one web space or previous neurectomy at adjacent web space.
- **Freiberg's infraction:** Consider if pain at second MT, adolescents, female > male. Treat with debridement if nonoperative measures fail.
- **Intractable plantar keratosis (IPK):** Under sesamoids (tibia > fibula) or fibular condyle of a metatarsal head.
- **Soft corn:** Remove offending distal aspect of the PIP.
- Recurrent second toe crossing over first toe is due to plantar plate.

If second-third neuroma is diagnosed, reconsider a second MT synovitis.

Sesamoids

- Fracture: Medial ≫ lateral.
- Beware of the nonpathologic bipartite sesamoid.
- Orthosis with metatarsal bar should be first treatment.
- Excise if there is a nonunion and shave if just irritated.
- Sesamoids are in the flexor hallucis brevis (FHB).
- Intra-articular displacement of the sesamoids means irreducible hallux MTP dislocation.
- Removal of both sesamoids = cock-up toe deformity.
- Removal of fibular sesamoid = chance of hallux varus.
- Removal of tibial sesamoid = chance of hallux valgus.
- If fibular sesamoid is already gone and symptoms recur, then try a plantar exostectomy of the remaining sesamoid.

Tendon Disorders

PTT disruption: Adult acquired flatfoot:

- Cast is initial treatment, nonsteroidal anti-inflammatory drugs (NSAIDs), arch support.
- **Stage 1:** Nonoperatively.
- **Stage 2:** FDL transfer, medial displacement osteotomy, +/– Achilles lengthening, +/– spring ligament repair.
- **Stage 3:** Triple arthrodesis.
- No prior treatment: Needs trial with walking cast.
- Poorest blood supply to PTT is between navicular insertion and distal medial malleolus.
- Symptomatic flexible flat foot: Brace of choice is Arizona (custom-molded leather/polypropylene).

Rigid PTT deformity does not respond well to orthotics; fusion is usually necessary. An RA PTT should be treated with fusion and not a soft tissue procedure.

- Flexible PTT dysfunction that fails bracing is treated with PTT reconstruction and medial displacement calcaneal osteotomy.
- Rigid deformity: Triple arthrodesis.
- Bridle procedure involves transferring the PTT to the anterior tibialis and peroneus longus (which has been rerouted anterior to the ankle); used for foot-drop patients.
- Acquired flatfoot often treated with lateral column lengthening and medial displacement calcaneal osteotomy.
- RA with a flexible or rigid flatfoot: Do a triple arthrodesis.
- Insufficiency of the PTT is the most common cause of hindfoot valgus in RA patient.
- When surgically correct hindfoot valgus will have forefoot supination due to chronic tightness.
- If surgically treating PTT disorder, consider adding an Achilles lengthening.

Achilles Tendon Injury

Achilles tendon repair has less rerupture, yet risks wound healing issues.

- Rerupture is more common with nonoperative treatment, but there are fewer skin complications.
- Must do nonoperative treatment of plantar flexion casting within 48 hours.
- Operative repair has higher skin complications, lower rerupture rates, same rehabilitation time yet earlier mobility, and stronger with repair.
- Operative expectations: Sural nerve risk, wound risk, 2% rerupture, return to sport in 3 months.
- Position of foot immobilization after Achilles repair: 20 degrees plantarflexion to maximize perfusion and protect repair.
- **Chronic Achilles rupture:** FHL is the most direct and best transfer to calcaneus.
- Retrocalcaneal bursa: Between Achilles tendon and superior calcaneal tuberosity.
- **Fluoroquinolones** (inhibit DNA gyrase): Stop if worried about Achilles tendinosis as they can precipitate tendon rupture.
- **Achilles tendinitis** due to hyperpronation, overuse:
  - Noninsertional—typically athletes.
  - Insertional—older (retrocalcaneal bursitis), associated with Hagland's deformity.

Optimal position of foot after Achilles repair: 20 degrees plantarflexion.

Peroneal Tendon Injury

- **Peroneus brevis tears:** If > 50% tear, tenodesis to peroneus longus; if < 50%, debride and tubularize. Peroneus brevis is more anterior in the fibular groove than longus.

FOOT NERVE TOPICS

Morton's Neuroma

- Third-fourth web space (most common).
- Gold standard for diagnosis: Physical exam and history.
- Release transverse intermetatarsal ligament if nerve appears normal.
- Failure rate: ~15%
- Complication of surgery: Traumatic neuroma.

Tarsal Tunnel Syndrome

- Intermittent paresthesias and numbness, increase with activity.
- Tarsal tunnel formed by flexor retinaculum posterior and distal to medial maleolus.
- Contains tibial nerve as it branches into the medial and lateral plantar nerves and the medial calcaneal branch.
- Can be confused with plantar fasciitis.
- Often caused by ganglion cyst.
- Complete release requires release of the deep fascia of the *abductor hallucis* muscle.
- Favorable outcome if there is a space-occupying lesion (ganglion, lipoma, neurilemmoma).

Baxter's nerve: First branch of the lateral plantar nerve, nerve to abductor digiti quinti.

Baxter's Nerve

- First branch of the lateral plantar nerve, nerve to abductor digiti quinti.
- Release nerve, fascia, abductor hallucis, and quadratus plantae as well as the plantar fascia.
- Do not need to resect the spur.

Medial Plantar Nerve Entrapment

- More frequent in *runners* and radiates to medial second-third toes.

Common Peroneal Nerve Palsy

- Treat supple drop foot with ankle-foot orthosis (AFO) with dorsiflexion assist.
- If bracing fails, consider tendon transfer.
- Transfer PTT through the interosseous membrane to the lateral foot.
- Achilles lengthening is required if food is not flexible and plantigrade.

NEUROLOGIC DISORDERS

Charcot-Marie-Tooth (CMT) Disease (Hereditary Motor Sensory Neuropathy [HMSN])

- **HMSN type I:**
  - Most common.
  - Chromosome 1 and 17 defects.
  - Autosomal dominant.
  - Symptoms begin around the second decade.
- **HMSN type II:**
  - Less pronounced than type I.
  - Symptoms begin during third decade.
  - No clear hereditary pattern.
- Peroneal nerve is typically affected first.
- Muscles affected: Foot intrinsics, anterior compartment muscles (tibialis anterior), and peroneus brevis (longus typically spared).
- Extensor digitorum longus (EDL) unopposed extension of MTP and proximal phalanx.
- Extrinsic flexors become unopposed flexors of PIP and DIP joints.
- Cavus due to imbalance between peroneus longus and anterior tibialis.

- Coleman block test:
  - If hindfoot varus corrects, first-ray dorsiflexion osteotomy.
  - If varus does not correct, hindfoot procedure needed.
- Surgical options:
  - Peroneus longus–to–peroneus brevis transfer.
  - Plantar fascia release.
  - Dwyer lateral calcaneal closing wedge osteotomy.
  - First-ray dorsiflexion osteotomy.
  - PTT reroute to dorsal cuneiform.
- Surgical intervention sequence: Calcaneal osteotomy, peroneus longus-to-peroneus brevis transfer if early enough, plantar fascia release, triple arthrodesis (try to avoid this answer on the test), claw toe correction.

Stroke (Cerebrovascular Accident [CVA])

- Spasticity from CVA stabilizes at 6 months (improvement can be expected up to 6 months).
- Incomplete spinal cord injury stabilizes at 12 months.
- Traumatic brain injury stabilizes at 18–24 months.

Polio

- Affects anterior horn cells; motor weakness; paralysis is most severe at time of infection. Any recovery is expected during the following year.
- Don't do surgery for 2 years.
- Postpolio syndrome:
  - L4 most common (quadriceps, anterior tibialis), valgus and equinus, fatigable.
  - Increased weakness in both previously normal muscle and paretic muscle.
  - Vigorous physical therapy is detrimental because it can precipitate fatigue, joint pain, muscle atrophy, respiratory insufficiency, dysphagia, and sleep apnea.
- Fixed hindfoot deformity with equinus contracture: Triple arthrodesis with Achilles lengthening.

Cavus

- Imbalance between anterior tibialis and peroneus longus (an isolated unilateral case merits a neurologic workup). Plantar-flexed first ray is a common radiographic sign.
- Use Coleman block test to evaluate hindfoot flexibility:
- If heel varus corrects with block under lateral foot, problem is in *forefoot* and requires correction of plantarflexed first ray.
- If heel varus does not correct with block under lateral foot, problem is in *hindfoot* and requires a lateralizing calcaneal osteotomy to correct hindfoot varus.

ARTHRITIC DISEASE

Red, Swollen MTP Joint

- Gout vs. infection.
- Need aspiration with evaluation of crystals, cell count, and culture.
- Serum acid levels less helpful.

Rheumatoid Arthritis (RA)

- Bilaterally symmetric; forefoot earliest joints affected; human leukocyte antigen (HLA)-DR4 positive.
- Talonavicular most common to have degenerative changes first; recommend fusion.

Gout

- Purine metabolism, monosodium urate crystals, negative needle yellow when parallel to light.
- Colchicine to treat acute gout attacks (1 mg, then 0.5 mg/hr until diarrhea or resolves).
- Allopurinol for chronic cases.

Pseudogout (Calcium Pyrophosphate Disease [CPPD])

- Tends to affect talonavicular and subtalar joints.

Seronegative Spondyloarthropathies

- Psoriasis, Reiter syndrome, ankylosing spondylitis, ulcerative colitis.
- Psoriasis: Rash, HLA-B27, dactylitis.
- X-ray differences between seronegative spondyloarthropathies and RA:
  - Intra-articular ankylosis.
  - Calcifications within adventitia.
  - Lack of osteopenia.

Total Ankle Arthroplasty

- Previous triple is best indication.
- Contraindications: Weight > 230 lb, talar AVN, Charcot joint, previous sepsis, tobacco use, ankle varus > 20 degrees, range of motion (ROM) < 20 degrees.

Arthrodesis

- **Ankle fusion:** 10 degrees equinus, 5 degrees valgus, 7 degrees ER. Postoperative motion is through the ipsilateral midfoot.
- Stress fracture after ankle fusion: Treat with short leg cast (SLC).
- **Triple arthrodesis:** Talonavicular joint is the most common site of nonunion. Adult acquired flatfoot is best treated with triple arthrodesis (especially if rigid deformity).
- **Midfoot deformity:** Fuse 1, 2, 3 and resect at 4, 5 (2, 3 OA is most common for the TMT).
- **First MTP fusion:** 10–15 degrees valgus, 10–15 degrees dorsiflexion from floor (or 20–30 degrees from foot).
- **Interphalangeal joint of great toe fusion:** 5 degrees plantar flexion.
- Lateral column lengthening with calcaneo-cuboid fusion can lead to fourth and fifth TMT arthritis.

Triple arthrodesis nonunion: Most common site is the talonavicular joint.

Lyme Disease

- Treat with amoxicillin or doxycycline.
- Great masquerader.
- Diagnose via antibody titers.

Madura Foot

- Mycetoma, sulfur granules, *sinus tracts*.
- Treat with antifungal therapy.

Onychocryptosis

- Ingrown toenail.
- Winograd procedure for nail ablation.

A shoe puncture into the foot may inoculate Pseudomonas aeruginosa.

Frostbite

- Rapid rewarming: 104.0°F–107.6°F (40°C–42°C); same for hands.

Shoe Nail Puncture

- *Pseudomonas aeruginosa* is common and characteristic, yet *Staphylococcus* is still the most common.

Necrotizing Fasciitis

- Urgent debridement and intravenous antibiotics (can manifest in the early postoperative period).

Diabetic Foot (and Charcot Neuropathy)

- Diabetic ulcer healing good prognostic factors:
  - Ankle-brachial index (ABI) > 0.45.
  - Transcutaneous oxygen tension (TcO_2) > 30 (normal, 60–90).
  - Toe pressures > 40–45 mm Hg.
  - Serum albumin > 3.5 mg/Dl.
  - Total lymphocyte count (TLC) > 1500.
- Semmes-Weinstein: 5.07 or 10 g monofilament detection is sign of **protective sensation**.
- Amputation rate ~2% without protective sensation vs. –0.1% with.
- *Painful ulcer*—get vascular study because neuropathic ulcers are *not* painful.
- Midfoot is the most common site of these ulcers.
- Indium-111 scan to discern foot infection.
- History of previous ulcer is the most common predictor of increased risk of foot ulcer in a diabetic.
- Total-contact cast in diabetic foot ulcer benefits by minimizing shear stresses and decreasing pressure.
- After ulcer is healed: Protective shoe wear and patient education to prevent further ulcers.

Diabetic protective sensation detection via Semmes-Weinstein: 5.07 or 10 g monofilament.

- Forefoot ulcer in diabetic: Achilles lengthening and total-contact cast is a good starting point.
- Swelling, erythema in diabetic foot following ORIF of ankle fracture: Charcot arthropathy.

▶ FOOT TUMORS

- **Pigmented villonodular synovitis (PVNS):** Hemosiderin on biopsy, often at ankle.
- **Osteoid osteoma:** Night pain relieved by NSAIDs; treat with en bloc excision.
- Most common foot mass: *Ganglion.*
- Most common sarcoma: *Synovial sarcoma.*
- Most common malignant foot tumor: *Melanoma.*
- Dark nail: Melanoma or Addison disease.
- **Subungual exostosis:** Pediatric cases on medial aspect of the great toe.

▶ CONGENITAL FOOT TOPICS

- **Arthrogryposis:** Clubfoot common.
- **Myelomeningocele:** Clubfoot common.
- **Diastrophic dysplasia:** Rhizomelic short stature, cauliflower ears, joint contracture (knees and hips most common locations), hitchhiker's thumb, cleft palate; most common are rigid equinovarus feet.
- **Congenital vertical talus:** Irreducible at talonavicular joint; cast for 3+ months, then correct with operation at 6–12 months.
- **Tarsal coalition:** Most common in children is the calcaneonavicular joint (*anteater sign*).
- **Accessory navicular:** Always start with casting; surgical excision if refractory.
- **Duchenne's muscular dystrophy equinovarus foot:** Due to gastrocnemius-soleus contracture and posterior tibialis persistent function.

An irreducible talonavicular joint means congenital vertical talus; best visualized on lateral radiograph.

▶ AMPUTATIONS

- **Toe amputations:**
  - Ulcers/infections at tip of toe.
  - Maintain plantar plate.
- **Great toe:** Leave base of the proximal phalanx if possible to preserve plantar fascia function.
- **Ray resection:**
  - MT head osteo, plantar MTP ulcer.
  - Bevel saw cut plantarly to prevent plantar bone/skin irritation.
  - Use a toe spacer in shoes post op.
- **Transmetatarsal:** Cushioned molded insole and filler over a carbon fiber footplate +/– rocker bottom; lengthen Achilles tendon.
- **Chopart amputation:** Talonavicular and calcaneo-cuboid joint; do simultaneous Achilles tendon lengthening.
- **Syme's amputation:** Prosthesis (ankle disarticulation)—no auxiliary mechanisms, end bearing.

Consider simultaneous Achilles tendon lengthening for any foot amputation involving more than phalanges.

▶ FOOT AND ANKLE TRAUMA

The main trauma information appears in Chapter 3. However, some information is worth repeating for emphasis.

Ankle

- **Lateral subtalar dislocation:** Impediments to reduction—PTT or interlocked impaction fracture of talus head or navicular.
- **Medial subtalar dislocation:** Impediments to reduction—extensor digitorum brevis (EDB) muscle, extensor retinaculum, impaction fracture of navicular or talus, transverse fibers of the cruciate–crural ligaments or talonavicular joint capsule.
- **Medial tibiotalar dislocation:** Impediment to reduction—peroneus brevis muscle/tendon.
- **Lateral tibiotalar dislocation:** Impedimant to reduction—tibialis posterior.
- **Juvenile Tillaux fracture:** *Anterior distal tibiofibular ligament* is attached to the fragment; anterior lateral distal tibia physis is the last to close.
- Dorsiflexion and eversion of ankle injures the CFL.
- Acute peroneal tendon dislocation: Early surgical repair for athletes/active patients; nonsurgical management only 50% successful.

Calcaneus

Hawkins sign is a good prognostic factor for talus vascularity.

- Fracture: Medial collapse and *varus* deformity; anterior process is attachment of *bifurcate ligament*.
- Tongue-type calcaneus fracture: Closed reduction and pinning (Essex-Lopresti-type technique).
- Sustentaculum tali fractures: FHL adhesions.
- Laborer with comminuted calcaneus fracture: Consider ORIF with primary subtalar fusion.

Talus

- Talar neck fracture: Most common complication is subtalar arthritis.
- Talar neck healing in 20 degrees of varus will cause lateral foot overload.
- **Hawkins sign** in talar neck fracture is a *good sign* of revascularization. No Hawkins sign indicates AVN of the talus.
- Talus fracture: Strongest screws are from posterolateral to anteromedial.

Navicular

- Köhler disease: Self-limiting osteochondritis of navicular; cast immobilization for 6–12 weeks, should resolve.
- Navicular stress fracture: Immobilization and *non–weight bearing*.

Metatarsals

- ORIF is recommended for first MT, in elite athlete, and if more than one central MT is fractured.
- Jones fracture: Chronic nonunion injury to intramedullary nutrient artery; intramedullary screw has higher failure rate in elite athletes.

Lisfranc Injury

- Anatomic reduction is mandatory.
- Lisfranc ligament runs from the medial cuneiform to the second MT.

GAIT, PROSTHETICS, AND REHABILITATION

To push off, the subtalar joint is rigid (nonparallel) and the tibia externally rotates, while the talus inverts and the calcaneus is in varus.

Gait

- Initial contact: Supple hindfoot, eversion, internal rotation (IR) of the tibia, valgus calcaneus.
- Foot-off: Locked hindfoot (parallel), inversion, ER of the tibia, calcaneus varus.
- Dorsiflexion: Fibular ER and proximal translation.
- Heelstrike: Tibial IR, talus everts, calcaneus valgus; subtalar joint is *flexible and parallel.*
- Push-off: Tibial ER, talus inverts, calcaneus varus; subtalar joint is *rigid and nonparallel.*
- The central nervous system controls dorsiflexion and plantar flexion.
- Gastrocnemius contracture test: Ankle dorsiflexion is tight with an extended knee but is not with a flexed knee.
- PTT test: Start with dorsiflexed everted foot (if inverted, use anterior tibialis and not PTT).

Inserts

- Plastizote: Closed cell; bottoms out yet is moldable.
- Cross-linked polyethylene foam has the greatest shock-absorbing properties.
- Poron: Open cell, not moldable, but doesn't bottom out.

Orthoses

- **UCBL** (University of California Berkley Lab): Orthosis works by controlling the *hindfoot* in *flexible* deformities.
- **CROW** (Charcot restraining orthotic walker) for total-contact removable casting: Used as a customized total-contact-fit removable brace to maintain foot alignment as patient evolves from Eichenholz stage 1 to stage 3 Charcot arthropathy.
- In-shoe orthoses *cannot* correct rigid deformity; these benefit accommodative deformities.
- Maximum hindfoot posting should be 5 degrees.
- Hyperpronation in a runner: Manage with a semirigid orthosis with a medial arch support.
- Midfoot arthritis needs extended steel shank in orthosis; also include a rocker sole.
- Carbon-reinforced Morton's extension for hallux rigidus.

NOTES

CHAPTER 8

Orthopaedic Tumors

Bone-Producing Lesions 170
- Osteoid Osteoma 170
- Osteoblastoma 170
- Enostosis 170
- Osteosarcoma (OS) 170
- Myositis Ossificans Traumatica (MOT) 171
- Osteochondral Exostosis (OCE) 171
- Pathologic Fracture 171
- Multidrug-Resistance Gene 171

Cartilage-Producing Lesions 171
- Enchondroma 171
- Periosteal Chondroma 172
- Osteochondroma 172
- Multiple Hereditary Osteochondroma (Multiple Hereditary Exostosis [MHE]) 172
- Chondromyxoid Fibroma 172
- Chondroblastoma 172
- Chondrosarcoma 172

Fibrous Lesions of Bone 173
- Nonossifying Fibroma (Fibrous Cortical Defect or Metaphyseal Fibrous Defect) 173
- Elastofibroma Dorsi 173
- Desmoplastic Fibroma 173
- Fibrosarcoma of Bone 173

Histiocytic Lesions of Bone 174
- Benign Fibrous Hystiocytoma (BFH) 174
- Malignant Fibrous Histiocytoma (MFH) 174
- Chordoma 174

Vascular Lesions of Bone 174
- Benign Lesions 174
- Malignant Lesions 174

Hematopoietic Bone Lesions 174
- Lymphoma 174
- Multiple Myeloma 175

Solitary Plasmacytoma 175
Osteosclerotic Myeloma 175
Bone Tumors of Unknown Origin 175
Giant Cell Tumor of Bone 175
Ewing's Sarcoma/Primitive Neuroectodermal Tumor (PNET) 176
Adamantinoma 176
Tumor-Like Conditions of Bone 177
Aneurysmal Bone Cyst (ABC) 177
Simple Bone Cyst (SBC) 177
Histiocytosis (Langerhans' Cell Histiocytosis) 177
Fibrous Dysplasia (FD) 177
Osteofibrous Dysplasia (OFD) 178
Paget Disease 178
Metastatic Bone Disease 178
Mirel's Tumor Criteria 179
Infection 180
Soft Tissue Lesions 180
Calcifying Aponeurotic Fibroma 180
Fibromatosis 180
Nodular Fasciitis 180
MFH 180
Dermatofibrosarcoma Protuberans (DFSP) 180
Fatty Tissue Lesions 181
Lipoma 181
Lipoblastoma 181
Liposarcoma 181
Neural Tissue Lesions 181
Neurilemmoma (Benign Schwannoma) 181
Neurofibroma 181
Neurofibromatosis (NF) (Von Recklinghausen's) 181
Neurofibrosarcoma 181
Malignant Peripheral Nerve Sheath Tumor (MPNST) 182
Muscle Lesions 182
Leiomyosarcoma 182
Rhabdomyosarcoma 182
Vascular Lesions 182
Hemangioma 182
Angiosarcoma 182
Synovial Disorders 182
Ganglion 182
Pigmented Villonodular Synovitis (PVNS) 182
Synovial Chondromatosis 182
Synovial Cell Sarcoma 183
Miscellaneous Sarcomas Of Soft Tissue 183

Hand Tumors 183
Giant Cell Tumor of Tendon Sheath 183
Neurilemmoma 183
Glomus Tumor 183
Epidermal Inclusion Cyst 183
Pyogenic Granuloma 183
Ganglion 183
Calcinosis 183
Carpal Boss 184
Enchondroma 184
Osteoid Osteoma 184
Chondrosarcoma 184
Bowen Disease 184
Squamous Cell Carcinoma 184
Melanoma 184
Epithelioid Sarcoma 184
Tumor Pearls 184
Benign Tumor Staging 184
Malignant Tumor Staging 184
Prognostic Factors (In Order of Importance) 185
Pediatric Tumor 185
Diagnostic Tumor Continuum 185
Epiphyseal Tumors 185
Tumors with Soft Tissue Mineralization 185
Lesion on Both Sides of the Joint 186
Sacral Lesions: Old (40–80 years) 186
Sacral Lesions: Young (10–40 years) 186
Surface Lesions 186
Tibial Lesions 186
Multiple Lesions: Young 187
Multiple Lesions: Old 187
The Big Five that can Look Like Anything (MC FIE) 187
Tumor Workup 187
Biopsy 187
Immunostains: Bone Tumors 188
Immunostains: Soft Tissue Tumors 188
Tumor Resection 188
Chemotherapy 188
Radiation 189
Bisphosphonate Therapy 190
Quick Reference: Tumor Treatment 190
Common Chromosomal Translocations 191
Tumor Suppressor Gene 191
Oncogenes 191
Tumor Miscellaneous 191

▶ BONE-PRODUCING LESIONS

Osteoid Osteoma

- Young (< 30 years old), lower extremity, pain better with nonsteroidal anti-inflammatory drugs (NSAIDs), referred pain.
- Central nidus with reactive bone, hot on bone scan, *always* < 1–1.5 cm.
- **Treatment:** Radiofrequency ablation or observation.
- **Histology:** Woven bone, sharp border.
- Rare, but is the most common benign bone tumor of carpal bones.

Osteoid osteoma pain is relieved with NSAIDs, while pain due to the big brother lesion, osteoblastoma, is not.

Osteoblastoma

- Big brother to osteoid osteoma; pain not relieved by NSAIDs.
- 2–6 cm in size (blastic in extremity, lytic in spine).
- Spine posterior elements are a common location.
- **Histology:** Same as osteoid osteoma—woven bone with distinct border.

Enostosis

- "Bone island" focus of mature compact (cortical) bone within the cancellous bone (spongiosa).
- *Cold* on bone scan.

Osteosarcoma (OS)

- Most common primary sarcoma of bone; affects young patients and is associated with *retinoblastoma*.
- Remember, the most common malignancy of bone is *metastatic*, and the most common primary malignancy of bone is *myeloma*.
- Most commonly presents in the second and third decades (secondary OS in older adults with Paget disease).
- Most important predictive tool of survival is *stage* of the disease.
- Most common presentation is stage IIB (high grade and extracompartmental).
- **High-grade intramedullary:**
  - Most common type of OS—85%.
  - 75% present as IIB lesions and 10%–20% present with metastases (most often to lung).
  - 50% occur around the knee.
  - Image *entire bone* to look for *skip metastases* (equivalent of stage III lesion if found).
  - **Bone scan:** Hot and photopenic in center (cystic or necrosis—giant cell tumor [GCT] or OS).
  - **Histology:** Lacy osteoid.
  - **Treatment:** Multiagent chemotherapy, wide resection, chemo again.
  - Necrosis > 98%: Will have an 80%–85% survival; only 50% survival if only 90% initial necrosis is achieved.
  - Percentage of preoperative necrosis from chemo is the main prognostic factor.
- **Telangiectatic OS:**
  - Looks similar to aneurysmal bone cyst (ABC)—watch out.
  - Lytic, no mineralization (or just a bit).

TABLE 8-1. Differentiation of Three Bone-Producing Tumors

Parosteal osteosarcoma	Stuck on the bone
Myositis ossificans	Juxtaposed to the bone
Osteochondral exostosis	Shares the cortex with the bone.

  - Ulnar side distal radius = OS (if radial side distal radius = GCT).
  - Donut sign on bone scan = necrosis.
- Parosteal OS (see Table 8-1):
  - Low-grade surface lesion, "stuck on the bone."
  - 80% distal femur, 20–30-year-old females most often, *painless* mass.
  - Often confused with fibrous dysplasia (FD) by the pathologist.
  - Bland spindle cells around the bone (*not* FD).
  - **Treatment**: Wide excision, *no chemo* (unless high grade).
  - Common location: *Posterior distal femur.*
- Periosteal OS:
  - Rare, diaphyseal (tibia and femur), second decade, sunburst pattern, chondroblastic.
  - **Treatment**: Chemo, surgery (wide resection), chemo.
  - Prognosis is worse than for *parosteal* OS, yet better than for *intramedullary* OS.

Myositis Ossificans Traumatica (MOT)

- Often some space—"juxtaposed to bone," not stuck on like parosteal OS.
- Mineralizes from periphery inward; OS mineralizes from inside out.
- Be leery of synovial cell sarcoma.

Myositis ossificans and synovial cell sarcoma can look similar.

Osteochondral Exostosis (OCE)

- Shares the cortex with native bone.

Pathologic Fracture

- Used to require amputation; not so now because there is no difference in survival compared with limb salvage.

Multidrug-Resistance Gene

- Very poor prognosis; 25% of primary lesions and 50% of metastases have gene.

▶ CARTILAGE-PRODUCING LESIONS

Enchondroma

- Benign, metaphyseal; 60% are in the hand (more cellular lesions).
- Most common primary tumor of the metacarpals, often asymptomatic in the foot.

- Stippled rings and arches, popcorn calcifications, blue balls of cartilage. *Beware of the calcified lesion with a lytic focus.*
- **Differential diagnosis:** Bone infarct.
- X-ray appearance: "Smoke up the chimney" for infarct.
- Intralesion curettage, no adjuvant treatment required.
- **Ollier disease:** Multiple lesions, 30% malignant.
- **Mafucci disease:** Multiple bone lesions and soft tissue lesions, 100% malignant; associated *visceral malignancies.*

Mafucci disease has multiple bone lesions and soft tissue lesions, including visceral malignancies, and the malignant degeneration potential is nearly 100%.

Periosteal Chondroma

- Rare; occurs in 10–20-year-olds; presents under the periosteum, 50% at proximal humerus.

Osteochondroma

- 35% of all benign lesions, very common; lesion should not grow in adults.
- Sessile, broad based, and points away from the joint; rare malignant change.
- Cartilage cap is typically 2–3 mm; if cap is > 2 cm, beware of sarcoma.

Multiple Hereditary Osteochondroma (Multiple Hereditary Exostosis [MHE])

- A subset of osteochondromas.
- Most frequent lesions to have secondary chondrosarcomas, especially if the lesion grows after skeletal maturity.
- If the cartilage cap is > 2 cm, suspect chondrosarcoma.

Chondromyxoid Fibroma

- Occurs in 20–30-year-olds in proximal tibia or foot; metaphyseal.
- Eccentric, well-demarcated lesion; 25% recur.
- **Treatment:** Curettage and bone graft.
- **Histology:** Stellate-appearing cells; mercedes benz, "soap bubble."

Chondroblastoma

- *Epiphyseal* lesions of young about the knee, proximal humerus, and proximal femur.
- *Painful;* often abut joint, and these can cross the physis.
- 2%–5% metastasize to lung (GCT can also do this).
- Calcaneus lesion (Codman's tumor).
- **Histology:** Chicken-wire calcifications; cobblestone appearance.
- **Treatment:** Extended *intralesional curettage and bone graft.*

Chondrosarcoma

- Occurs in patients > 50 years old; most common locations are pelvis (25%), ribs (20%), and femur (15%).
- **Intramedullary chondrosarcoma:** Location is key:
  - Most present as *stage IA.*
  - Same lesion in hand = enchondroma; femur = chondrosarcoma.

- Axial and proximal skeleton lesions are more aggressive (distal femur and pelvis are common spots).
- **Treatment:** Wide surgical excision (most are chemo and radiotherapy *insensitive*).
- Histologic grade correlates with percentage chance of metastases:
  - Grade I, 0%–5%.
  - Grade II, 20%.
  - Grade III, 60%
  - Dedifferentiated, 85%

- **Clear cell chondrosarcoma:** Epiphyseal location; large cells with central nuclei that occur most commonly in the proximal humerus and the proximal femur.
- **Mesenchymal chondrosarcoma:** Lowest 5-year survival rates.
- **Dedifferentiated chondrosarcoma:**
  - Most malignant cartilage lesion.
  - 50% have *pathologic fracture* due to tumor's aggressive and very destructive nature.
  - **Treatment:** As for any other sarcoma—chemo, surgery, chemo again (13% 5-year survival); very poor prognosis.

Exact diagnosis via pathology depends on lesion's location: Hand = enchondroma, pelvis = chondrosarcoma.

▶ FIBROUS LESIONS OF BONE

Nonossifying Fibroma (Fibrous Cortical Defect or Metaphyseal Fibrous Defect)

- Occurs in 30% of skeletally immature patients; most often resolves after skeletal maturity.
- **Pathologic fracture:** Scrape out, then bone graft.
- **Histology:** Bubbly appearance with whirling appearance (think helicopter on a wheat field).
- **Jaffe-Campanacci syndrome:** Multiple larger nonossifying fibromas (NOFs):
  - Retinal problems
  - Café au lait spots
  - Mental retardation

Elastofibroma Dorsi

- Posterior chest wall under the scapula is the typical location.

Herringbone pattern is associated with fibrosarcoma.

Desmoplastic Fibroma

- Rare; occurs in 15–25-year-olds.
- Equivalent of a soft tissue desmoid and is *not* a periosteal desmoid.
- Lytic, expansile with dense fibrous tissue.
- **Treatment:** Aggressive curettage; 40% recur.

Fibrosarcoma of Bone

- Rare malignant tumor in patients > 50 years old.
- **Treatment:** Chemo, resect, chemo again (poor results). Fibrosarcoma and malignant fibrous histiocytoma (MFH): Wide resection and add radiation if large lesions (> 5 cm).
- **Histology:** *Herringbone* pattern with spindle cells and purely ill-defined lytic lesions.

▶ HISTIOCYTIC LESIONS OF BONE

Benign Fibrous Hystiocytoma (BFH)

- Uncommon; ilium and ribs most common.
- Differential diagnosis includes NOF, except there is pain.
- **Histology:** Spindle cells.

Physaliferous cells are seen with chordoma.

Malignant Fibrous Histiocytoma (MFH)

- 30% have an underlying chronic condition (infection, implant, etc.).
- **Histology:** Lytic and destructive, giant cells, storiform.
- **Treatment:** Chemo, resect, chemo again.
- **Prognosis:** 60% survival at 5 years.

Chordoma

- Notochordal nest cells; malignant (at ends of spine, head, and pelvis).
- Pain vague—rectal exam warranted.
- **Histology:** *Physaliferous* cells.
- **Treatment:** Wide resection (add radiation if poor margins obtained).
- Metastasizes 30%–50% of the time.

▶ VASCULAR LESIONS OF BONE

Benign Lesions

- **Hemangioma:**
  - Rare vascular lesion that can occur at any age and can *wax and wane in size*.
  - Spine common location +/– pain.
  - **"Jail bar"** vertebrae because the disease takes some trabeculae and leaves others.
  - **Treatment:** Observe; curettage with bone graft or low-dose radiation.
- **Lymphangioma:**
- **Gorham disease:** Vanishing bone disease.

Malignant Lesions

- **Hemangioendothelioma:**
  - Crawling up bone in multiple spots; can involve *multiple bones* in the same extremity (skip lesions).
  - **Treatment:** Wide resection or curettage if low grade.
  - **Hemangiopericytoma.**
  - **Angiosarcoma.**

Multiple myeloma frequently contains plasma cells with clock-face nuclei and cold bone scans.

▶ HEMATOPOIETIC BONE LESIONS

Lymphoma

- Primary is usually is non-Hodgkin's lymphoma (NHL).
- Mottled, blastic, *very hot* on bone scan, mixed round cell infiltrate.
- **Treatment:** Radiation and chemotherapy.

Multiple Myeloma

- Plasma cell malignancy in patients > 50 years old.
- Plasma cells produce *immunoglobulins*.
- Bone destruction caused by *RANKL*.
- **Bisphosphonates** reduce the number of skeletal events in patients with multiple myeloma.
- "Punched out" lesions.
- *30% are cold on bone scan.*
- **Serum protein electrophoresis (SPEP)** is critical in workup: *"M" spike*—immunoglobulin G (50%), immunoglobulin A (25%).
- **Treatment:** Chemo and radiation.
- Poor prognostic factors:
  - Deletion of chromosome 13 or its long arm.
  - Translocation (t4;14), 4(14;16).
  - Circulating plasma cells.
  - Increased serum beta 2 microglobulin.
  - Decreased serum albumin.
  - Increased marrow microvessels.
- **Histology:** Hoffa's clear zone, clock-face cells.

Solitary Plasmacytoma

- A local disease, not diffuse.
- **Treatment:** Radiation.

Osteosclerotic Myeloma

- Associated with neuropathy; can be lytic or sclerotic.
- **POEMS syndrome:**
  - Polyneuropathy, Organomegaly, Endocrinopathy, M protein, Skin changes.
  - **Treatment:** Radiation.
  - Neurologic changes often do not improve.

▶ BONE TUMORS OF UNKNOWN ORIGIN

Giant Cell Tumor of Bone

- Aggressive benign lesion in 20–40-year-olds; distal radius and proximal tibia.
- If ulnar side of distal radius, think of *telangiectatic* OS.
- **X-rays:**
  - Well-marginated lytic lesion.
  - Subchondral (abuts the articular surface).
  - Eccentric.
  - Closed physis.
- Sacral involvement often present with neurologic changes.
- Multicentric GCT resembles hyperparathyroidism.
- Histology: Multinucleated giant cells (Figure 8-1).
- **Treatment:** Aggressive curettage with bone graft (+/– phenol or other local adjuvant to minimize recurrence) with a recurrence rate of 2%–5%.

Giant cell tumor radiographic diagnosis: Well marginated, subchondral, closed physis, eccentric.

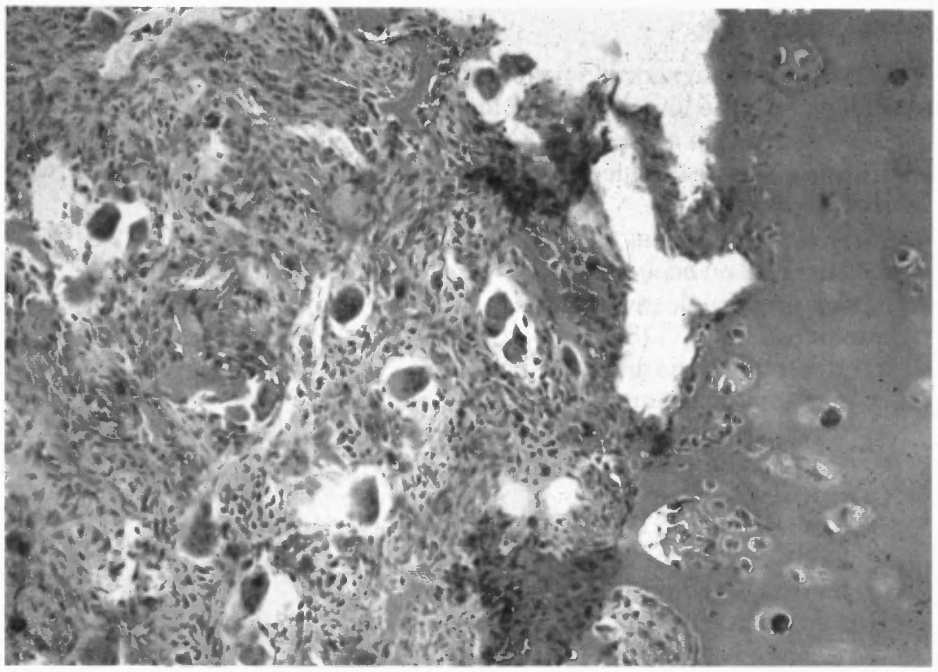

FIGURE 8-1. Giant cell tumor of bone micrograph. Notice the multinucleated giant cells.

Ewing's Sarcoma/Primitive Neuroectodermal Tumor (PNET)

- Malignant round cell sarcoma affecting young patients 5–25 years old.
- Commonly diaphyseal.
- < 5 years old: Consider leukemia or metastatic neuroblastoma.
- > 30 years old: Consider metastatic carcinoma or lymphoma.
- Third most common primary sarcoma of bone (most common, osteogenic sarcoma; second most common, chondrosarcoma).
- Most common locations are pelvis and femur.
- If in ribs, think **Askin's tumor.**
- **Chromosomal translocation:** t(11;22) found in 90% of patients, positive vimentin stain (sarcoma stain), CD 99 reactivity.
- **Histology:** Monotonous sheets of small smudgy blue cells, pseudorosettes (necrosis in middle).
- Neuroblastomas in contrast have true rosettes.
- Lung metastases common (get chest computed tomography [CT]), temperature fluctuation (similar to infection).
- **Treatment:** Chemo, resect, chemo again (some say chemo and radiation).

Adamantinoma and OFD appear similar on radiographs but have drastically different outcomes.

Adamantinoma

- Tibial lesion in patients > 20 years old; can involve tibia and fibula in up to 50% of cases.
- Precursor may be *osteofibrous dysplasia (OFD) (Campanacci disease).*
- *Adamantinoma* and *OFD* mimic radiographically.
- **Histology:** Fibrous tissue with epithelioid tissue.
- **Treatment:** Wide en bloc excision; if diaphyseal tibia, consider a wide intercalary tibial resection.

- 40% recur with amputation (thus do not amputate).
- Lung metastasis, 25%.

▶ TUMOR-LIKE CONDITIONS OF BONE

Aneurysmal Bone Cyst (ABC)

- Vertebrae and long bones (any bone) are typical locations and have lytic, expansile lesions in patients < 20 years old.
- Fluid-fluid lines on x-ray: *GCT, chondroblastoma, FD, simple cyst.*
- **Bone scan:** *Donut sign.*
- **Differential diagnosis:** *Telangiectatic OS.*
- **Treatment:** Curettage and bone graft; 25% recur.

Simple Bone Cyst (SBC)

- Cystic lesion, metaphysis of long bones (80% in proximal humerus or femur); 2%–3% cross-physis.
- **Active:** Next to physis; **latent:** Normal intervening bone.
- **Treatment:** Observe; aspiration/steroid or curettage and bone grafting.
- Does *not* go away with fracture; bone will heal, but cyst remains until it goes away on its own.
- **Histology:** Bone with fibrous lining.

Histiocytosis (Langerhans' Cell Histiocytosis)

- Continuum: Eosinophilic granuloma → Hand-Schüller-Christian disease → Letterer-Siwe disease.
- **Eosinophilic granuloma:**
  - Most common of the three, affecting multiple bones and occurring in the first three decades.
  - "Punched out" lesions on x-ray; most involute.
  - **Vertebra plana** does reconstitute with time but never look normal; treat with brace if no neurologic changes and the spine gets a uniform collapse.
  - **Histology:** Langerhans' cell (histiocyte with grooved nucleus), Birbeck granules on electromyogram (EM) (tennis racquet).
  - **Treatment:** Low-dose radiation (600 cGy), bone graft with curettage, steroid injection, or observation.
- **Hand-Schüller-Christian disease:**
  - Bone and visceral involvement.
  - Classic triad (< 25% patients): Diabetes insipidus, exophthalmos, lytic bone (often skull).
  - **Letterer-Siwe disease:** Fatal in young because histiocytosis is everywhere in these patients.

Vertebra plana is associated with histiocytosis and does remodel some over time but never appears "normal."

Fibrous Dysplasia (FD)

- Developmental abnormality that can be *mono- or polyostotic.*
- **Café au lait spots:** Coast of Maine (as opposed to coast of California with neurofibromatosis [NF]).
- Common location: Proximal femur; associated with Gs-alpha protein (*GNASrm* pt).

Coast of Maine = FD. Coast of California = NF.

- **Polyostotic form** is usually lower extremity and homolateral with rare vertebral involvement.
- **X-ray:** Ground glass appearance that looks like anything and sometimes is not hot on bone scan.
- *Microfractures* can be a cause of pain.
- Endocrine abnormality—**McCune-Albright syndrome:** Precocious puberty, café au lait spots, and polyostotic FD.
- **Histology:** Chinese letters, C and O (woven bone, yet *no osteoblastic rimming*).
- **Treatment:** Observe vs. internal fixation; if bone graft must be used, use cortical allograft.
- "Fibrous dysplasia heals with fibrous dysplasia" (i.e., it does not heal with normal bone).

Osteofibrous Dysplasia (OFD)

- Expansile cortical lesion often affecting the *tibia* in children.
- **Histology:** Fibrous and immature trabeculae.
- *Do* have rimming osteoblasts, unlike FD.

Paget Disease

- Disease of abnormal bone remodeling occurring in the fifth decade (3%–4% of the population).
- May be associated with *paramyxovirus.*
- Can present with *high-output cardiac failure.*
- Elevated *hydroxyproline* (collagen breakdown marker).
- **X-rays show:**
  - *Coarse purposeful trabeculae.*
  - *Mixed lytic–blastic.*
  - *Thickening of the cortex.*
  - *Enlargment of the bone.*
  - Lytic, then both, then blastic.
  - "Blade of grass."
  - **Osteitis circumscripta** or cotton wool exudates in skull.
  - **Histology:** Prominent cement lines with lots of osteoclasts.
  - **Treatment:** Initially, treat with *bisphosphonates* (to retard osteoclasts and reduce hypervascularity and bleeding), *calcitonin.*
- **Paget's sarcoma:**
  - Patient complains of new-onset pain; rule out sarcomatous transformation.
  - 1%–15% transformation with poor prognosis requiring chemo, surgery, and more chemo.
  - **Prognosis:** High grade has a dismal prognosis.

Paget disease associations: Paramyxovirus, hydroxyproline, osteitis circumscripta.

Metastatic Bone Disease

- Most common bone lesion in the older patient, lung metastases being the single most common (definitely the number one metastasis to the distal phalanx—bronchogenic carcinoma).
- Treated breast cancer can often present with bone metastases without any sign at original location.
- **Hypercalcemia (with metastases):** Confusion, muscle weakness, polyuria, polydipsia, nausea, vomiting, anorexia, dehydration. Treat with hydration, diuretics, bisphosphonates.

- Pathologic fracture in 30% of metastatic cases.
- Most common primary metastases to bone are **BLT PK** (**B**reast, **L**ung, **T**hyroid, **P**rostate, **K**idney).
- **Spine metastases are due to Batson's venous plexus,** which is valveless in the spine and the way metastatic tumor cells get to the spine.
  - Suspect a thoracic location of spine metastases if there is acute deterioration in neurologic status (due to this area's smaller diameter).
  - Metastatic prostate to spine: *blastic*.
  - Metastatic renal cell to spine: *lytic*.
  - Adenocarcinoma's favorite location to metastasize is the spine.
- **30/60/90 rule:**
  - 30% lung is blastic.
  - 60% breast is blastic.
  - 90% prostate is blastic.
- Metastases distal to knee or elbow: *Lung* (by far the most common) or renal.
- Highly vascular tumors (will bleed a lot if operated on): *Renal cell and thyroid metastases*.
- **Thyroid metastases:** Cold on bone scan (like myeloma).
- Lymphatic metastases (rare): The most common are *synovial sarcoma*, rhabdomyosarcoma, clear cell sarcoma, and epithelioid sarcoma.
- Sarcomas metastasize to lungs preferentially and those with hematogenous metastases require aggressive treatment.
- **Metastases to lung:**
  - **Malignant:** MFH and synovial sarcoma.
  - **Benign:** GCT and chondroblastoma.
- **Treatment:** Aimed at maintaining skeletal integrity.
- **Strontium:** Pain treatment option in patients with diffuse *blastic metastases*.
- Survival with metastatic bony lesions:
  - Breast and prostate: 24 months.
  - Lung, kidney, melanoma: < 6 months.

Metastatic lesions that have a propensity to bleed are renal and thyroid.

Mirel's Tumor Criteria (Table 8-2)

- Score of ≥ 8 requires operative fixation (8 = 15% chance of pathologic fracture, 9 = 30%).
- ≤ 7: Consider radiation treatment.

TABLE 8-2. Mirel's Tumor Criteria

Scoring	1 Point	2 Points	3 Points
Site	Upper extremity	Lower extremity	Peritrochanteric
Pain	Mild	Moderate	Functional
Lesion	Blastic	Mixed	Lytic
Size	< 1/3	1/3–2/3	> 2/3

Chronic infection areas can develop squamous cell carcinoma.

Infection

- **Sequestrum** (necrosis), **involucrum** (reactive bone around the necrosis).
- **Chronic infection** can develop *squamous cell carcinoma.*
- The presence of spores on histology signifies a fungal lesion.
- **Chronic recurrent multifocal osteomyelitis (CRMO):** Treat with NSAIDs.
- *Staphylococcus epidermidis* is the most common bacteria isolated from large reconstructive allograft.
- **Brodie's abscess:** Curettage and antibiotics.
- **Lyme disease:** Treat with amoxicillin or doxycycline for 30 days (ceftriaxone for nonresponders).
- **Subcutaneous granuloma annulare** is a self-limited process.
- **Cat scratch fever:**
  - *Bartonella henselae* can present with epitrochlear lymph nodes.
  - Treat with oral erythromycin.
  - **Tuberculosis** to spine displays anterior destruction with disk space preservation.

▶ SOFT TISSUE LESIONS

Calcifying Aponeurotic Fibroma

- Occurs on the hands and feet in children.
- **Treatment:** Local excision needed.

Fibromatosis

- Do not operate on painful nodules as these often come back worse.
- Palmar and plantar locations exist.
- Fibromatosis is a stage 3 metastatic soft tissue sarcoma (MSTS).
- **Extra-abdominal desmoid:**
  - Most locally invasive of all soft tissue tumors.
  - *Resect*, radiation, and/or chemo (new development).
  - **Desmoid tumor:** Treat with wide excision or marginal excision with radiation.

Nodular Fasciitis

- Most common benign fibrous proliferation.
- **Treatment:** Warrants excision.

MFH

- Similar to fibrosarcoma.
- **Histology:** Storiform cells, *herringbone* pattern (just like fibrosarcoma of bone).
- **Treatment:** Wide resection and radiation.
- **MFH and liposarcoma** are the two *most common* soft tissue sarcomas.

Dermatofibrosarcoma Protuberans (DFSP)

- Rare nodular cutaneous tumor affecting young adults.
- Commonly involves the foot.
- Treated with wide resection (> 3 cm margins) +/– radiation.

▶ FATTY TISSUE LESIONS

Lipoma

- Mature fat can have some mineralization (worry about synovial cell sarcoma, which can also have calcifications).

Lipoblastoma

- Occurs in children (they do not get lipomas).

Liposarcoma

- **Myxoid** is the most common type; can metastasize to the *retroperitoneum*.
- Mixed signal on MRI; does not follow fat signal, as a lipoma will.
- **Atypical lipoma:**
  - If above fascia, most likely benign.
  - If below fascia, most likely malignant.

Antoni A neurilemmomas are highly organized and have Verocay bodies, while Antoni B are more haphazard in orientation.

▶ NEURAL TISSUE LESIONS

Neurilemmoma (Benign Schwannoma)

- Benign nerve sheath tumor with a true capsule of nerve epineurium.
- **Antoni A:** Highly ordered, compact spindle cells; nuclear palisading; *Verocay bodies*.
- **Antoni B:** Loose, haphazard myxoid matrix with delicate collagen; large irregular vessels.
- **Treatment:** Marginal excisions, leave nerve; good prognosis.

Neurofibroma

- Solitary or multiple, resembling a *bag of worms*.
- Scalloping "from without" on radiographs.
- **Treatment:** Marginal excision.

Neurofibromatosis (NF) (Von Recklinghausen's)

- 1/3000 live births.
- Autosomal dominant (50% spontaneous mutations).
- Type I: Chromosome 17 (*hint*: 17 letters in NF).
- Peripheral type I, central type II.
- Lisch nodules (eyes), café au lait spots (coast of California).
- **NF-1:** Bone changes as in NOF.
- **NF-2:** Little bony involvement.

Neurofibrosarcoma

- Can spread along the nerve.

Malignant Peripheral Nerve Sheath Tumor (MPNST)

- Malignant schwannoma.
- Neurofibrosarcoma.
- 4% chance of getting this if patient has NF.

▶ MUSCLE LESIONS

Leiomyosarcoma

- Deep sarcoma with a poor prognosis and *cigar-shaped nuclei.*
- Positive for vimentin, actin, and desmin.

The most common soft tissue sarcoma in children < 10 years old is rhabdomyosarcoma (alveolar in limbs, embryonal overall).

Rhabdomyosarcoma

- Tumor of young children.
- Small blue cells; positive for vimentin, desmin, and myosin.
- t(2;13) = alveolar rhabdomyosarcoma.
- *Most common soft tissue sarcoma in children* < 10 years old, with *embryonal* being the most common type overall and *alveolar* the most common in the limbs.
- **Treatment:** Chemo and resection (possible role for radiation); very chemo sensitive!

▶ VASCULAR LESIONS

Hemangioma

- Can have calcifications and fatty infiltrate juxtaposed to the bone.
- **Treatment:** Observe or percutaneous sclerosis with EtOH.

Angiosarcoma

- Rare, cutaneous lesions.
- Chronic edema.

▶ SYNOVIAL DISORDERS

Ganglion

- Take care of joint pathology when excising a ganglion in order to minimize recurrence (see Chapter 6).

Pigmented Villonodular Synovitis (PVNS)

- Erosive changes on *both sides* of the joint!
- Bone lesions in tibia and calcaneus.

Lymph node metastases are common with synovial cell sarcoma (common in lower extremities).

Synovial Chondromatosis

- Benign metaplasia of synovium.
- Nodules within the joint.
- **Treatment:** Synovectomy.

Synovial Cell Sarcoma

- Highly malignant occurring near joints, but rarely arises from a joint.
- *Most common* sarcoma of the lower extremities.
- **Treatment:** Wide resection, then radiation.
- *Lymph node* metastases are a common physical exam finding.

▶ MISCELLANEOUS SARCOMAS OF SOFT TISSUE

- **Epithelioid sarcoma:** Often in the hand.
- **Clear cell sarcoma:** Often associated with tendons.
- **Alveolar cell sarcoma:** Common presentation is a slow-growing anterior thigh mass.

▶ HAND TUMORS

Giant Cell Tumor of Tendon Sheath

- 10% recur.
- Off flexor sheath most common.
- **Treatment:** Marginal excision.

Neurilemmoma

- *Most common peripheral nerve tumor.*
- Eccentric.
- Easily shelled out from the nerve.
- **Treatment:** Marginal excision.

Glomus Tumor

- Small; 50% subungual and 50% in fingertip.
- Hemangioma family.
- **Triad:** Bluish color, cold intolerance, pinpoint tenderness.

Epidermal Inclusion Cyst

- Associated with prior penetrating trauma (keratinizing tissue gets deep).

Pyogenic Granuloma

- Prior trauma; treat with *excision.*

Ganglion

- *Most common hand mass*; aspiration 59% effective.
- Dorsal ganglion: From scapholunate joint.
- Volar ganglion: From radiocarpal, scaphotrapeziotrapezoid (STT) joint.

Calcinosis

- Soft tissue calcification, seen in flexor carpi ulnaris (FCU), MP joints.
- Associated with rheumatoid arthritis (RA), systemic lupus erythematosus (SLE), scleroderma (treat underlying disease).

Carpal Boss

- Base of capitate and third metacarpal osteophyte.
- Observe or excise and fuse.

Enchondroma

- Symmetric fusiform enlargement of proximal and middle phalanges.
- Curettage and bone graft.

Osteoid Osteoma

- Phalanx, carpus.
- Worse with EtOH, better with aspirin; nothing helps in fingertips.

Chondrosarcoma

- *Most common malignancy of bone in the hand.*

Bowen Disease

- Interepidermal squamous cell in nail fold.

Squamous Cell Carcinoma

- *Most common malignancy of hand*; firm, ulcerated lesion; slow growing.
- Wide resection with radiation.

Melanoma

- Often thin (< 1 mm).
- Excise with 1–3 cm margin.
- Sentinel node biopsy.

Epithelioid Sarcoma

- *Most common soft tissue sarcoma of the hand.*
- Spread via lymphatics; radical margins.
- Upper extremities most common; wide excision or amputation.

▶ TUMOR PEARLS

Benign Tumor Staging

- Stage 1: Latent
- Stage 2: Active
- Stage 3: Benign aggressive

Malignant Tumor Staging

- Stage IA: Low grade.
- Stage IB: Low grade, extracompartmental.

- Stage IIA: High grade.
- Stage IIB: High grade, extracompartmental.
- Stage III: Metastases.

Prognostic factors affecting survival is a frequent test question; know their order of importance: Stage, metastases, skip lesions, grade, size.

Prognostic Factors (In Order of Importance)

- Stage
- Presence of metastases
- Presence of "skip" lesions (discontinuous tumor)
- Grade
- Size

Pediatric Tumor

- Leukemia in children can involve the synovium and cause arthralgias.
- The most common primary malignant bone tumors in children are OS and Ewing's sarcoma.
- The most common soft tissue sarcoma in children is rhabdomysosarcoma (then synovial sarcoma and firbrosarcoma).
- The most common epiphyseal lesion in children is infection.

Diagnostic Tumor Continuum

- See Table 8-3.

Epiphyseal Tumors

- Giant cell tumor
- Chondroblastoma
- Clear cell chondroblastoma
- Eosinophilic granuloma
- Tuberculosis

Tumors with Soft Tissue Mineralization

Benign

- Lipoma
- Hemangioma

TABLE 8-3. Diagnostic Tumor Continuum by Lesion Type

Lesion	Age
Eosinophilic granuloma	First 10 years
Ewing's sarcoma	10–25 years old
Lymphoma	30–50 years old
Myeloma or metastatic disease	> 50 years old
Infection	Anywhere, anytime

- Chondroma
- MOT

Malignant

- Synovial cell sarcoma
- Liposarcoma
- Angiosarcoma
- Chondrosarcoma
- Malignant schwannoma
- Neurofibrosarcoma

Lesion on Both Sides of the Joint

- Blood (hemophilia)
- Pus (infection)
- Pannus (inflammatory arthridity)
- PVNS
- Tuberculosis
- Osteoarthritis

Sacral Lesions: Old (40–80 years)

- Chordoma
- Mets
- Myeloma
- Lymphoma
- Chondrosarcoma

Sacral Lesions: Young (10–40 years)

- Giant cell tumor
- ABC
- Ewing's
- OS

Surface Lesions

- Osteochondroma
- Multiple exostosis
- Periosteal chondroma
- Parosteal OS
- Periosteal OS

Tibial Lesions

- Adamantinoma
- OFD
- FD
- Osteomyelitis

Multiple Lesions: Young

Benign

- EOG
- Enchondromatosis
- FD
- Multiple exostosis

Malignant

- Hemangioendothelioma
- Leukemia/lymphoma

Multiple Lesions: Old

Benign

- Paget
- Bone infarcts

Malignant

- Metastases
- Multiple myeloma
- Lymphoma

The Big Five that Can Look Like Anything (MC FIE)

- Metastatic carcinoma
- Cartilage lesions
- Fibrous dysplasia
- Infection
- Eosinophic granuloma

Tumor Workup

- Blood work—complete blood count, erythrocyte sedimentation rate, smear, SPEP, urine protein electrophoresis (UPEP), urinalysis, prostate-specific antigen, chemistries.
- Chest x-ray, chest CT—obtain if suspected malignancy before putting patient under anesthesia.
- Whole-body bone scan (myeloma is *cold* on bone scan at least 30%).
- Magnetic resonance imaging (MRI) or positron emission tomography (PET) scan.

Biopsy

- Do not do the biopsy unless you are the one who is going to take care of the patient.
- Never use a transverse incision.
- Hemostasis is vitally important.
- 2–12 times greater biopsy complication if done elsewhere and 27% wrong diagnosis.
- Fine-needle aspiration (FNA), 70%–75% accurate; core needle biopsy, 85%; open biopsy, 96%–98%.

Immunostains: Bone Tumors

Immunostain	Tumor(s)
S-100	Eosinophilic granuloma, chordoma
Keratin	Metastases, chordoma, adamantinoma
CD1A	EG
CD20	Lymphoma
CD99	Ewing's
CD138	Myeloma

Immunostains: Soft Tissue Tumors

Immunostain	Tumor(s)
Keratin	Synovial sarcoma, epithelioid sarcoma
EMA	Synovial sarcoma
Smooth muscle actin	Leiomyosarcoma
Desmin	Rhabdomyosarcoma
Myoglobin	Rhabdomyosarcoma
S100	Clear cell sarcoma, nerve sheath tumors
CD34	Angiosarcoma
Factor VIII	Angiosarcoma
Elastin	Elastofibroma

Tumor Resection

- **Intralesional:** Through the tumor.
- **Marginal:** Through the reactive zone.
- **Wide:** En bloc removal (standard).
- **Radical:** Entire compartment removed.
  - Resection with prosthesis and allograft (Figure 8-2).

Chemotherapy

- Induces programmed cell death.
- Eliminates micrometastases in lung.

FIGURE 8-2. Proximal humerus with radical resection reconstructed with allograft and prosthesis.

- Improves survival with > 95% tumor kill.
- Reduces recurrence.
- Multiagent treatment is the reason patients survive malignant bone lesions.
- 60%–70% 5-year survival with chemotherapy (11% if no chemo).
- **Bleomycin:** Concern for *pulmonary fibrosis.*
- **Adriamycin:** Concern for *cardiomyopathy.*
- **G1 → S phase:** Most vulnerable time for chemo cells.

Radiation

- Stops tumors by making free radicals and causing genetic damage.
- Good for soft tissue tumors.
- 1 rad = 1 centigray.
- Typically 180–200 cGy/day.
- Total dose: < 45 gray—tissue should heal; 45–55 gray—probably will heal but have problems; > 60 gray—no healing.

- Postradiation sarcoma risk is 13% (poor prognosis for these patients).
- Lymphoma and myeloma are radiation sensitive.

Bisphosphonate Therapy

- Inhibit osteoclasts.
- Inhibit protein prenylation.
- Works on mevalonate (cholesterol) pathway.
- Disrupts ruffled border microtubules.
- Causes apoptosis.

Quick Reference: Tumor Treatment

- **Observation:**
  - NOF
  - FD
  - Enchondroma
  - Osteochondroma
  - Paget
- **Aspiration and injection (only 2!):**
  - UBC
  - EG
- **Curettage and grafting:**
  - Giant cell tumor (cement or graft)
  - ABC
  - NOF (if symptomatic)
  - Chondroblastoma
  - Chondromyxoid fibroma
  - Osteoblastoma
- **Wide resection:**
  - Chondrosarcoma
  - OS
  - Ewing's
  - MFH
  - Fibrosarcoma
  - Chordoma
  - Adamantinoma
- **Chemotherapy:**
  - Medium- and high-grade tumors
  - OS
  - Ewing's
  - Rhabdomyosarcoma
  - Lyphoma
- **Irradiation:**
  - Ewing's
  - Myeloma
  - Lymphoma
  - Metastatic bone tumors (after surgery)
- **Bisphosphonate therapy:**
  - Metastatic bone disease
  - Multipe myeloma
  - Paget
  - Polyostotic FD

RANKL

Note that this material on RANKL also appears in Chapter 1, but it bears repeating here.

- Released by osteoblasts
- Binds to RANK receptor on osteoclast
- Activates osteoclast
- Leads to bone destruction
- Important in tumors—especially multiple myeloma
- **OPG** is a decoy inhibitor and stops osteoclast activation
- **Upregulate RANKL and downregulate OPG (increase bone destruction):**
  - PTH
  - 1,25-, (OH_2) VitD
  - IL-1 β
  - TNF-α
  - PGE2
- **Downregulate RANKL and upregulate OPG (decrease bone destruction):**
  - IL-4
  - TNF-β
  - Interferon N gamma

Common Chromosomal Translocations

- Ewing's sarcoma, t(11;22).
- Alveoloar rhabdomyosarcoma, t(2;13).
- Synovial sarcoma, t(X;18).
- Myxoid liposarcoma, t(12;16).
- Clear cell sarcoma, t(12;22).
- Chondrosarcoma, t(9;22).

Tumor Suppressor Gene

- **Rb-1**: Regulates gene expression.
  - Both must be gone (recessive).
  - 35% OSs.
- **p53**: Prevents entrance into S-phase (OS, chondrosarcoma).
  - One bad copy and you have the tumor (dominant).
  - 20%–65% OSs.

Oncogenes

- Induce uncontrolled growth, recessive.
- FAK, erb-2.
- **Chemotherapy** for these tumors: **ROPEL**—Rhabdomyosarcoma, Osteosarcoma, PNET < Ewing's, Lymphoma.

▶ TUMOR MISCELLANEOUS

- **Pain at night:** Most common presenting symptom in a patient with a high-grade malignant bone tumor.
- **Phemister's law:** Lesions of bone occur in areas of greatest bony activity.
- **Periacetabular lesions:** Consider chondroid lesions.
- **Renal cell tumors** require embolization, and then the surgery must be performed within 24 hours.

- **Synovial cell sarcoma** mineralizes in soft tissue.
- **Fibrosarcoma and MPNST** have higher recurrence rates than most other tumors.
- **MFH and liposarcoma** are the two most common soft tissue sarcomas.
- Soft tissue sarcoma is the prime suspect if > 5 cm and deep to the fascia.
- Sarcoma soft tissue 5-year survival overall: 70% (with high-grade, only 50% survival).
- **Bone scan:** Often not necessary to diagnose sarcomas because they rarely have bone metastases.
- **Bony destruction > 40 years old**: Metastases, myeloma, lymphoma, and chondrosarcoma.
- **Tumoral calcinosis:** Calcified periarticular soft tissue masses (associated with long-term dialysis).
- Bone and soft tissue sarcomas: < 1% all cancers.
- **Ovarian carcinoma** is associated with *bilateral diffuse palmar fasciitis.*
- **Histologic grade** is the most important criterion for tumor survival.
- **Local recurrence:** Correlates with surgical margins.
- **Soft tissue sarcoma:** Radiation and chemotherapy required.
- **Bone sarcoma:** Chemo, resect, chemo again.

CHAPTER 9

Pediatric Orthopaedics

Pediatric Diseases 196

- Arthrogryposis 196
- Larsen Syndrome 196
- Duchenne's Muscular Dystrophy 196
- Fascioscapulohumeral Muscular Dystrophy 196
- Becker's Muscular Dystrophy 196
- Friedreich's Ataxia 196
- Charcot-Marie-Tooth 197
- Cerebral Palsy (CP) 197
- Neuromuscular Hip Dysplasia 197
- Neuromuscular Foot 198
- Myelodysplasia 198
- Adolescent Idiopathic Scoliosis 198
- Infantile Idiopathic Scoliosis 199
- Juvenile Idiopathic Scoliosis 199
- Congenital Spine Deformity 199
- Scheuermann's Kyphosis 199
- Neurofibromatosis 200
- Spondylolysis 200
- Klippel-Feil Syndrome 200
- Ehlers-Danlos Syndrome 200
- Atlantoaxial Instability 200
- Rotatory Subluxation 200
- Pseudosubluxation 200
- Pediatric Orthopaedic Infections 200
- Diskitis 201
- Delayed Spine Infection after Fusion 201
- Spinal Muscular Atrophy 201
- Sacral Agenesis 201
- Sacroiliac Joint Infection 201

Pediatric Upper Extremity 201

- Brachial Plexus Birth Injury 201
- Sprengel's Deformity 202

Congenital Pseudoarthrosis of the Clavicle 202
Congenital Dislocation of the Radial Head 202
Radioulnar Synostosis 202
Radial Club Hand (Radial Deficiency) 202
Ulnar Club Hand (Ulnar Deficiency) 202
Cleft Hand, Lobster Claw Hand, Ectrodactyly (Central Deficiency) 203

Pediatric Lower Extremity 203
Developmental Dysplasia of the Hip (DDH) 203
Congenital Coxa Vara 204
Legg-Calvé-Perthes (LCP) Disease 205
Slipped Capital Femoral Epiphysis (SCFE) 205
Femoral Torsion 205
Proximal Femoral Focal Deficiency (PFFD) 205
Congenital Short Femur 205
Leg Length Discrepancy (LLD) 206
Pediatric Amputations 206
Congenital Knee Dislocation 206
Tibial Torsion 206
Osgood-Schlatter Disease 206
Patella Ossification 206
Nail Patella Syndrome 206
Discoid Lateral Meniscus 207
Fibular Hemimelia 207
Tibial Hemimelia 207
Congenital Pseudoarthrosis of the Tibia 207
Posteromedial Bowing of the Tibia 207
Infantile Blount Disease 207
Clubfoot 207
Congenital Vertical Talus 208
Calcaneovalgus Foot 208
Metatarsus Adductus 208
Adolescent Bunion 208
Cavus Foot 208
Flexible Flatfoot 208
Accessory Navicular 208
Köhler Disease 208
Peroneal Spastic Flatfoot 209
Freiberg's Infraction 209
Curly Toes 209

Dysplasias and Syndromes 209
Achondroplasia 209
Pseudoachondrodysplasia 209
Spondyloepiphyseal Dysplasia (SED) 209
Multiple Epiphyseal Dysplasia (MED) 210
Chondrodysplasia Punctate 210
Kneist Syndrome 210
Dysplasia Epiphysealis Hemimelica (Trevor Disease) 211

Metaphyseal Chondrodysplasia 211
Diastrophic Dysplasia 211
Cleidocranial Dysplasia (Dysostosis) 211
Mucopolysaccharidoses 211
Spondylometaphyseal Dysplasia 211
Diaphyseal Dysplasia 212
Osteopetrosis 212
Gaucher Disease 212
Marfan Syndrome 212
Homocystinuria 212
Down Syndrome 212
Osteogenesis Imperfecta 212

Pediatric Trauma 212
Fracture Remodeling 212
Physeal Fractures 213
Galeazzi Fracture 213
Supracondylar Humerus Fracture 213
Lateral Condyle Fracture 213
Medial Epicondyle Fracture 213
Both-Bone Forearm Fracture 213
Radial Head Fracture 214
Olecranon Fracture 214
Humerus Fracture 214
AVN Risk with Femoral Head/Neck Fractures 214
Femoral Neck Nonunion 214
Femoral Shaft Fractures 214
OCD Lesions 214
Intercondylar Eminence Fractures 214
Tibial Tubercle Fracture 215
Patella Sleeve Fracture 215
Toddler's Fracture 215
Proximal Metaphyseal Fracture 215
Tillaux Fracture 215
Triplane Fracture 215
Corner Fractures 215
Odontoid Fracture 215
Thoracic and Lumbar Compression Fracture 215

Arthrogryposis

- Sensation intact, *normal intelligence*, *multiple rigid joints*, few anterior horn cells, oligohydramnios.
- No skin creases with rigid clubfeet.
  - Must do surgery, possible talectomy.
  - Triple arthrodesis in adolescent patients.
- Teratologic hip dislocation: Pavlik harness not indicated.
- Pseudoacetabulum bilateral at presentation; treat with open reduction.

Larsen Syndrome

- Multiple joint dislocations.
- Flattened facies.
- Scoliosis.
- Cervical kyphosis (may present with extremity weakness).

Duchenne's Muscular Dystrophy

Scoliosis in Duchenne's patients: Operate early if deformity > 20 degrees, while pulmonary status can still handle surgery; PSF only, use segmental fixation.

- Sex-linked recessive.
- Elevated creatine phosphokinase (CPK).
- Most patients will die at ~20 years old.
- Gower's sign.
- Calf pseudohypertrophy.
- *Absent dystrophin* protein.
- Myofiber membrane fragility leads to inflammatory response and fibrosis.
- Effects eccentric muscle contraction most.
- **Corticosteroids** improve symptoms and natural history; upregulates *utrophin*.
- **Scoliosis:** Operate early; posterior spinal fusion (PSF) for > 20 degrees; segmental fixation.

Fascioscapulohumeral Muscular Dystrophy

- Autosomal dominant (AD).
- Normal CPK.
- Scapular winging.
- Not able to whistle.

Becker's Muscular Dystrophy

- Late-onset Duchenne's, but not as bad and patients live longer.
- *Abnormal dystrophin* protein.

Friedreich's Ataxia

- Spinocerebellar degenerative disease.
- Staggering wide-based gait.
- Cardiomyopathy.
- Cavovarus foot similar to Charcot-Marie-Tooth (CMT).
- Sensory and motor problems.
- Scoliosis (different than CMT).

Charcot-Marie-Tooth

- Weakness in anterior tibialis, peroneus brevis, foot intrinsics, and hand intrinsics.
- AD.
- Cavus feet.
- Hammer toes.
- Mainly motor problems.
- Defect of peripheral myelin protein 22.

Cerebral Palsy (CP)

- Nonprogressive.
- Upper motor neuron disease.
- Injury to immature brain, onset before 2 years old.
- Best predictor for ability to walk: Sitting independently by age 2.
- **Types:**
  - Spastic (most common).
  - Athetoid.
  - Ataxic.
  - Mixed.
- **Treatments** for spacticity:
  - Botox, baclofen, rhizotomy.
  - **Botox:** Competitive inhibitor at motor endplate; *presynaptic cholinergic* receptor.
  - **Baclofen:** Gamma-aminobutyric acid (GABA) agonist (mechanism unknown); oral and intrathecal.
  - Botox and baclofen do not treat contractures.
  - Dorsal rhizotomy for ambulatory spastic kids who don't need spasticity for function.
- **Toe walking:**
  - Ankle dorsiflexion > 5 degrees: Treat with ankle-foot orthosis (AFO).
  - If < 10 degrees dorsiflexion: Achilles lengthening.
- **Crouched gait:** Never treat with Achilles lengthening alone, which would increase crouch; need multilevel release.
- **Stiff knee gait:**
  - Limited knee flexion during swing phase.
  - Rectus femoris firing out of phase.
  - Consider rectus femoris transfer.
- **Scoliosis with CP:**
  - Typically more involved.
  - Be aware of neurologic risk as cause.
- **Surgical indications:**
  - Progressive deformity.
  - Sitting imbalance.
  - Pelvic obliquity.
- **Hallux valgus:**
  First try orthotics.
  First MTP fusion has fewest complications.

When treating scoliosis in a patient with CP, segmental fixation is needed; consider fusing to the pelvis or else increase chance of losing correction.

Neuromuscular Hip Dysplasia

- Goal is to prevent dislocation.
- **Early treatment** (< 4–5 years old): Adductor and flexor release and splinting.

For a chronic painful neuromuscular hip dislocation, consider abduction osteotomy/proximal femoral resection.

- **Later** (> 4 years old): Bony work is often required.
- If < 7 years old, then *varus derotational osteotomy (VDRO)*.
- If > 7 years old, add *pelvic osteotomy*.
- Chronic painful dislocation: Abduction osteotomy, proximal femoral resection.

Neuromuscular Foot

- **Equinovalgus:** Cause is spastic peroneals, spastic heelcord, and ligamentous laxity.
  - **Treatment:** Achilles lengthening, calcaneal osteotomy vs. Grice subtalar fusion.
- **Equinovarus:** Cause is overpull of anterior tibialis or posterior tibialis and tight Achilles.
  - **Treatment:** Achilles lengthening and split posterior tibial tendon transfer vs. Rancho procedure.
  - Only for flexible equinovarus deformities.

Myelodysplasia

- Failure of neural tube to close.
- **Patient's functional level** is the lowest functioning nerve root.
- **Risk factors:**
  - Maternal hypothermia.
  - Maternal insulin-dependent diabetes.
  - Valproic acid.
  - Folate deficiency.
- Change in patient's function, get magnetic resonance imaging (MRI) (*evaluate for a tethered cord*).
- **Latex allergy** (*IgE mediated*): Can cause anaphylactic shock during surgery.
- Rigid clubfeet, vertical talus, calcaneus feet are common.
- **Fractures:**
  - Common; present with a swollen, erythematous leg.
  - No infection usually, yet this is possible.
- **Hip dislocation:**
  - Most common with L3–4 level because hip flexors and adductors are unopposed (get abduction at L4 and extension at L5).
  - **General rules:**
    - If myelodysplasia level is L2 or higher, leave hips out.
    - If L4 or lower, try and get them reduced (functioning quads is the key).
- **Scoliosis with myelodysplasia:** Thoracic levels are most often affected, and bracing does not work.
  - **Treatment:** Anterior–posterior spinal fusion.
    - High pseudoarthrosis rate.
    - High infection rate (15%–25%).

Adolescent Idiopathic Scoliosis

- **Right thoracic scoliosis** is the most common form.
- **If left curve**, then get *MRI* to rule out spine lesions.
- **Etiology**: Unknown.

- **Suspected causes:**
  - Hormonal
  - Platelet
  - Calmodulin
  - Multifactorial
- **Curve progression:**
  - Age.
  - Skeletal maturity.
  - *Peak growth velocity.*
  - Curve magnitude (> 20 degrees).
  - Curve type.
  - Thoracic ≫ lumbar.
  - Double > single.
  - Progression after maturity likely if *thoracic* > 50 degrees and *lumbar* > 30 degrees.
- **Anterior–posterior spinal fusion indicated if:**
  - Young patient (*crankshaft phenomenon* if < 10 years old).
  - Severe curves > 75 degrees.
- **Complications:**
  - Neuro injury.
  - Pseudoarthrosis.
  - Flat back syndrome.
  - Crankshaft.
  - Superior mesenteric artery (SMA) syndrome.
  - Delayed infections (*Propionibacterium acnes* is the most common organism).

The highest chance of rapid progression in a patient with idiopathic adolescent scoliosis is during peak growth velocity.

Infantile Idiopathic Scoliosis

- Age 2 months to 3 years.
- Males >> females.
- Left thoracic more common.
- Rib vertebral angle difference (RVAD) > 20 degrees means a high risk of progression; this reading measures vertebral rotation.

Juvenile Idiopathic Scoliosis

- Age 3–10 years.
- 50% require surgery.
- Obtain MRI to rule out other pathology.
- Crankshaft phenomenon: To avoid, do anterior–posterior spinal fusion.

Congenital Spine Deformity

- Failure of segmentation or formation.
- **Worst prognosis:** Unilateral bar with contralateral hemivertebrae.
- **Anterior–posterior spinal fusion:** In situ, no hardware.
- Treatment for L5 hemivertebra with an oblique takeoff: *Hemivertebrectomy.*

Scheuermann's Kyphosis

- If bracing is needed, use *Milwaukee extension brace.*
- **X-rays:** Kyphosis > 5 degrees at three consecutive levels, Schmorl's nodes.

Neurofibromatosis

- AD.
- Café au lait spots (coast of California).
- Rib penciling.
- Kyphoscoliosis, short-segment C sharp angle.
- Vertebral scalloping.
- **Scoliosis surgery:**
  - High rate of pseudoarthrosis.
  - Anterior–posterior spinal fusion.
  - Obtain MRI preoperatively.

Spondylolysis

- **Mechanism:** Repetitive hyperextension.
- **Slip angle:** If high, then greater junctional kyphosis.

Klippel-Feil Syndrome

- Congenital fusion of the cervical vertebrae.
- Web neck.
- Short hairline.
- Limited cervical range of motion (ROM).
- High incidence of *renal* problems.

Ehlers-Danlos Syndrome

- Developmental dysplasia of the hip (DDH).
- Clubfoot.
- Scoliosis.
- Tissue-paper skin.
- Lax joints.

Atlantoaxial Instability

- Seen most commonly with Down and juvenile rheumatoid arthritis (JRA).
- Normal: Up to 5 mm in adult and 7 mm in children.

Rotatory Subluxation

- Can be seen with recent upper respiratory infection (URI) (*Grisel disease*) with retropharyngeal irritation.
- **Treatment:** Early traction; fuse in resistant cases (4–6 weeks).

Pseudosubluxation

- C2–3 location.
- Age < 8 years.
- Facet orientation is *more parallel* at this level.

Pediatric Orthopaedic Infections

- Most common location is metaphyseal via hematogenous spread.
- Joints with intra-articular metaphysis: *Hip, shoulder, elbow, ankle.*

- Gonorrhea is most common joint infection in sexually active adolescents.
- Puncture injury through shoe: Think *Pseudomonas* (gram-negative rod).

Osteomyelitis or a septic joint in pediatric patients is most commonly from hematagenous spread, and the metaphysis is the most common location.

Diskitis

- Fever, abdominal pain; patient refuses to walk.
- **MRI:** Disk erosion; plain film changes take at least 7–10 days (disk space narrowing).
- **Treatment:**
  - Do not aspirate; give anti-staph antibiotic.
  - Biopsy if no response to anti-staph antibiotic.

Delayed Spine Infection after Fusion

- If fusion has been obtained, perform an incision and drainage (I&D) and remove the hardware.
- Some advocate suppressing infections until the bone heals and then removing the hardware (although sometimes bone will not fuse in the face of infection).
- Most common bacteria: *P. acnes* and *Staphylococcus epidermidis*.

Spinal Muscular Atrophy

- Type I: Birth to age 6, poor survival.
- Type II: 6 months to 5 years of age.
- Type III: Appears between 2 and 17 years of age.
- Degeneration of *anterior horn cells* leads to weakness, atrophy.
- EMG normal.
- Muscle biopsy shows denervation.
- Hip: Valgus deformity of femur with subluxation common; observe.
- Spine: Scoliosis common; progression correlates with muscle weakness.
- Bracing for scoliosis poorly tolerated.
- Surgery for pts > 10 years old, FVC > 40%.
- Anterior approach contraindicated.

Sacral Agenesis

- Associated with imperforate anus, sacral dimples, meningocele, popliteal webbing.
- Associated with maternal alcohol and drug use.
- Must stabilize pelvis to allow sitting and free use of hands.

Sacroiliac Joint Infection

- Obtain MRI as this is often confused with septic hip.

▶ PEDIATRIC UPPER EXTREMITY (SEE HAND SECTION FOR A COMPLETE DISCUSSION OF CONGENITAL HAND ABNORMALITIES)

Brachial Plexus Birth Injury

- Horner's sign is poor prognostic indicator for recovery.
- IR, adduction contracture common.

- Treat with PT initially to increase ROM.
- Get MRI prior to surgery to evaluate glenoid (frequently retroverted).
- Minor deformity: Anterior release with terres major and lattissimus transfers.
- Major deformity: Humeral derotational osteotomy.

Sprengel's Deformity

- Associated with Klippel-Feil syndrome.
- High, small scapula typically on right.
- Observe vs. Woodward procedure.

Congenital Pseudoarthrosis of the Clavicle

- On right side, unless situs inversus (then left).
- Possible vascular etiology.
- **Treatment:** If symptomatic, internal fixation with bone graft.

Congenital Dislocation of the Radial Head

- Concave radial head.
- Posterior dislocation, bowing.
- **Treatment:** If symptomatic, radial head excision at maturity.

Radioulnar Synostosis

- 60% bilateral.
- Forearm overpronated.
- Elbow flexion/extension usually normal.
- Surgery for decreased function: Rotational osteotomies (not excision of synostosis).

Radial Club Hand (Radial Deficiency)

- Longitudinal failure of formation.
- Associated with TAR (thromocytopeia-absent radius), VACTERRAL, Fanconi's anemia, Holt-Oram (heart disease).
- Radial artery, median nerve, FCR can also be affected.
- Type IV (absent radius) most common.
- Biceps function is key to managing this issue.
- Do not change shape of hand if no biceps function.
- Centralize if biceps function is intact and elbow has decent ROM.
- Requires early casting/splinting to stretch radial tissues.
- Surgical results: High risk of recurrent deformity, decreased wrist ROM.

Ulnar Club Hand (Ulnar Deficiency) (Figure 9-1)

- Not associated with systemic disorders (like radial club hand), but can be associated with other musculoskeletal deformities, especially hand.
- Wrist is stable, elbow function decreased.
- Only if function is severely disturbed should wrist stabilization be performed.

FIGURE 9-1. **Ulnar club hand.** Ulnar deficiency, not typically associated with systemic disorders.

Cleft Hand, Lobster Claw Hand, Ectrodactyly (Central Deficiency) (Figure 9-2)

- Central absence of at least one digit.
- Other digits may fuse (syndactyly).
- Typical deformity: AD, often bilateral, more common in boys, may involve the feet.
- Atypical deformity: Sporadic; associated with cardiac and gastrointestinal abnormalities.
- Associated with cleft palate, heart disease, imperforate anus, deafness.

▶ PEDIATRIC LOWER EXTREMITY

Developmental Dysplasia of the Hip (DDH)

- **Risk factors:** First born, female, breech, positive family history, oligohydramnios.
- Associated with torticollis and metatarsus adductus.
- Ortolani or Barlow positive means the hip is *reducible*.
- If reducible, one can treat with a *Pavlik harness*.
- Blocks to reduction: Iliopsoas contracture, capsular constriction (hour glass), inverted labrum, pulvinar, enlarged ligamentum terres.
- Ultrasound is not a screening tool; use to follow Pavlik treatment or for equivocal exam.

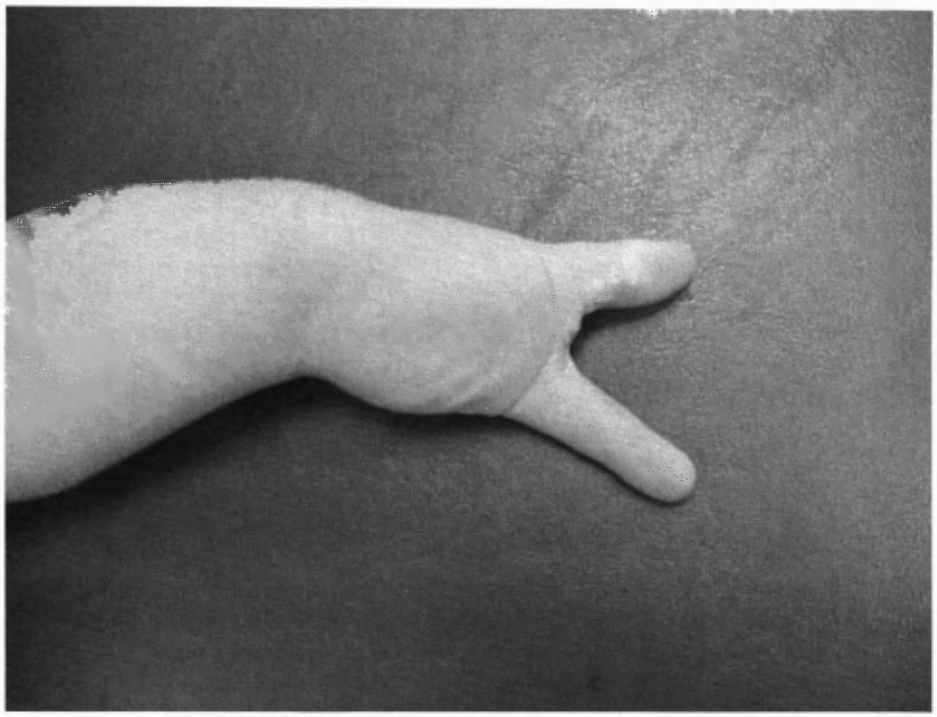

FIGURE 9-2. Cleft hand. Central deficiency, absence of central digit(s).

- May need femoral osteotomy until 4 years of age; after this, acetabular osteotomy may be needed.
- **Acetabular index:** Normal is < 30 degrees (> 30 degrees is considered dysplastic).
- **Treatment options:**
  - Hip reduction best for children < 4 years old.
  - Acetabulum remodels up to 6 years old
  - Do not attempt reduction for kids > 8 years old.
  - **Pavlik harness for infants:**
    - 90% success.
    - 90 degrees flexion, 50 degrees abduction.
    - Overabduction can lead to AVN.
  - Pelvic osteotomies (improves anterior and anterolateral coverage):
    - Salter: Open triradiate cartilage, for mild cases.
    - Pemberton: For moderate and severe; most versatile; cut to triradiate cartilage and use as hinge.
    - Dega: For severe; best for posterolateral dysplasia in CP.
    - Ganz PAO: Osteotomy of choice in older or adult patient; leaves pelvic ring intact.
    - Shelf: Adds bone graft to edge of acetabulum; generally a salvage option.
    - Chiari: Salvage option that medializes cup (iliac cut).
  - Shelf, Chiari: Require metaplasia.

Pelvic osteotomies improve anterior and anterolateral coverage of the femoral head.

Congenital Coxa Vara

- **X-rays:** Inverted "Y" bilateral.
- **Treatment:** Valgus osteotomy if ≤ 90 degrees.

Legg-Calvé-Perthes (LCP) Disease

- Idiopathic avascular necrosis (AVN) of femoral head.
- Phases: Synovitic (0–3 months), fragmentation (3–9 months), re-ossification (9–24 months), remodeling (24 months to 4 years).
- Limited hip abduction and IR.
- Male-to-female ratio: 4:1.
- Age 4–8 years.
- Never bilateral simultaneously.
- Bilateral ~12%, yet *asymmetric*.
- Poorer prognosis with onset < 6 years of age.
- Treatment:
  - If < 8years old: Activity modification, non op.
  - If > 8 years old: Surgery improves outcome (varus osteotomy).
  - Any child with < 50% lateral pillar height: No improvement with surgical containment; salvage procedure after re-ossification.
- Diseases that mimic LCP: Gaucher, spondyloepiphyseal dysplasia (SED), multiple epiphyseal dysplasia (MED), glycogen storage diseases—these can have symmetric involvement.

Slipped Capital Femoral Epiphysis (SCFE)

- Obese, male, rapid growth, limp, thigh pain.
- Can present as *knee pain*.
- Fracture through *hypertrophic zone of physis*.
- Weakened perichondral ring.
- Neck displaces in *external rotation and anteriorly*.
- **Stable** (can walk with crutches; AVN risk minimal).
- **Unstable** (cannot walk; AVN risk significantly high).
  - Acute: < 3 weeks.
  - Chronic: > 3 weeks.
- **X-ray:** Klein's line, blanch sign of Steel, wide physis.
- Patient needs endocrine workup if < 10 years old or weight < 50th percentile; pin contralateral hip if endocrine abnormality is discovered.
- Threads of fixation screw or pin need to cross physis.
- Pacific islanders have a higher incidence of SCFE.

The lateral X-ray view is typically the best view to visualize a subtle slip in a patient with SCFE.

SCFE can present as knee pain.

Femoral Torsion

- Most common cause of in-toeing.
- Excessive anteversion.
- Will resolve somewhat but not completely.
- If functional limitations persist: Rotational osteotomy with blade plate after age 9.

Proximal Femoral Focal Deficiency (PFFD)

- 50% have *fibular hemimelia*.
- Absent anterior cruciate ligament (ACL) is common.
- Lateral-ray deletion is common.
- Repair pseudoarthrosis if in femoral neck.

Congenital Short Femur

- Absent ACL is also common (see PFFD).
- Can lengthen ~30%.

Leg Length Discrepancy (LLD)

- ~9 **mm/year** growth from distal femur.
- ~6 **mm/year** growth from proximal tibia.
- Girls grow until *~14 years of age*.
- Boys grow until *~16 years of age*.
- **Epiphysiodesis** for LLD of 2.5–4.0 cm.
- **Lengthen** (distraction osteogenesis) for > 4–5 cm.
- Distraction osteogenesis: Lengthen 1 mm/day.
- For leg with flexion contracture, get CT scanogram to determine length.

Pediatric Amputations

- *Diaphyseal* overgrowth due to appositional growth.
- **Disarticulations** have *less overgrowth*.
- Fit upper extremity prosthesis at *6 months of age* (when baby can sit up).
- Fit lower extremity at *1 year* (when child starts to walk).

Congenital Knee Dislocation

- Treatment is closed reduction and casting with knee flexion.

Tibial Torsion

- Internal:
  - Less common cause of in-toeing.
  - Will gradually resolve.
  - Does not affect agility.
  - No surgery.
- External:
  - Presents in later childhood.
  - Decreased agility.
  - Benefits from rotational osteotomy.

Osgood-Schlatter Disease

- Microfractures of the immature tibial tubercle apophysis due to overuse.
- **Treatment:** Activity modification, symptomatic.

Patella Ossification

- Males at 4–5 years old.
- Females at 3 years old.

Nail Patella Syndrome

- Nail dystrophy.
- Hypoplasia of the lateral elbow.
- Absence or hypoplasia of the patella.
- Iliac horns.

Discoid Lateral Meniscus

- If asymptomatic, *do not treat.*
- If symptomatic (pain, mechanical symptoms) or lack extension: Saucerize the lateral meniscus.

In a patient with fibular hemimelia and lateral-ray deletions, if there are four or more good rays, consider limb salvage and reconstruction; if not, amputation is best.

Fibular Hemimelia

- LLD.
- *Ball-and-socket ankle.*
- Absent cruciate ligaments.
- Equinovalgus foot.
- If three good rays or fewer, *consider amputation* and early prosthetic fitting.

Tibial Hemimelia

- AD.
- Equinovarus foot.

Congenital Pseudoarthrosis of the Tibia

- *Anterolateral* bow associated with neurofibromatosis (50%–80%).
- Do not do an osteotomy as first-line treatment; attempt to prevent fracture first.
- If fracture occurs, consider intramedullary (IM) nail and bone graft.

Posteromedial Bowing of the Tibia

- Spontaneously corrects.
- Associated with *calcaneovalgus foot;* will correct on its own (no surgery).
- 2–5-cm LLD at maturity.

Infantile Blount Disease

- Abnormality of proximal medial tibial physis.
- Genu varum.
- If *Drenan angle is > 13 degrees*, then pathologic.
- **Langeskoild stages I–IV:** Brace and knee–ankle–foot orthosis (KAFO).
- **Stages V and VI:** Treatment is early osteotomy and overcorrection into valgus.

Clubfoot

- Equinovarus hindfoot, forefoot supination, and adductus with midfoot cavus.
- Male > female.
- 20% positive family history.
- Associated with arthogryposis, myelodysplasia, Larsen's, diastrophic dwarfism but is usually isolated.
- Ponsetti casting:
  - Forefoot is first supinated and the foot is abducted to reduce navicular.
  - Calcaneus is not touched.

- Counterpressure applied to talus.
  - Dorsiflexion is last deformity corrected.
- 50% success rate with casting alone (Ponsetti, 90% with casting and Achilles lengthening).

Congenital Vertical Talus

- Convex pes valgus, associated with myelodysplasia and chromosomal abnormalities.
- Longitudinal axis of talus is not in line with first metatarsal.
- *Navicular is dorsally dislocated.*
- Does not correct with plantar flexion or dorsiflexion on lateral radiograph.

Calcaneovalgus Foot

- Associated with posterior medial bow.
- Excessive dorsiflexion at birth.
- **Treatment:** Home stretching.

Metatarsus Adductus

- Associated with DDH.
- Associated with late medial cuneiform obliquity (not hallux valgus).
- Treatment: Observe, reassurance; straight or reverse last shoes or casting and stretching can help.
  - No surgery.

Adolescent Bunion

- Nonoperative in most cases.
- If operative treatment is undertaken, *recurrence* is the most common complication.

If a patient presents with a cavus foot, do a thorough neurologic exam and obtain MRI to rule out potential neurologic causes.

Cavus Foot

- Check for hairy patch on back (myelodysplasia).
- Consider spine MRI to rule out neural causes.

Flexible Flatfoot

- Treat with orthotics.

Accessory Navicular

- Midfoot pain.
- If symptomatic, always treat with cast immobilizaion. Surgical excision for refractory cases.

Köhler Disease

- *Navicular AVN.*
- Resolves spontaneously.
- Treat symptomatically (immobilize).

Peroneal Spastic Flatfoot

- Calcaneal navicular coalition is the most common cause (anteater sign).
- Check for other coalitions.
- Resection is good in those < 14 years old for calcaneal navicular coalition.
- Talocalcaneal coalition: Computed tomography (CT):
  - If < 50% of joint, resect coalition.
  - If < 50% involvement, fuse it.

Freiberg's Infraction

- Second metatarsal head osteonecrosis.
- If conservative treatment fails, *debride joint.*

Curly Toes

- **Treatment:** Tenotomy of short and long flexors.

▶ DYSPLASIAS AND SYNDROMES

Achondroplasia

- Fibroblast growth factor-3 (FGF-3) receptor.
- AD.
- Epiphyseal–heterotrophic zone.
- Effects intramembranous ossification.
- Disproportionate dwarf.
- Short limb (rhizomelic), quantitative defect.
- Narrow foramen magnum, narrow IP distance in L-spine, *stenosis,* and bowed legs.
- Frontal bossing, enlarged skull, characteristic facial features.
- Bracing ineffective for genu recurvatum/varum; need osteotomy.
- Not more prone to DJD.

Pseudoachondrodysplasia

- Type of SED.
- Cartilage oligomeric matrix protein (COMP) abnormality (see MED).
- Similar to achondroplasia, AD.
- *Normal face* (different than achondroplasia).
- Epiphyseal; fragmented epiphysis.
- Windswept knees common.
- Prone to DJD.

Spondyloepiphyseal Dysplasia (SED) (Figure 9-3)

- Short-trunk and short-limb dwarf.
- Epiphyseal.
- *Congenital form:* Type II collagen abnormality (see Diastrophic Dysplasia and Kneist Syndrome); cleft palate, lordosis, *platyspondyly,* AD.
- *Tarda:* SEDL gene, *X-linked,* kyphosis, hip pain, thick vertebrae, hip dysplasia.

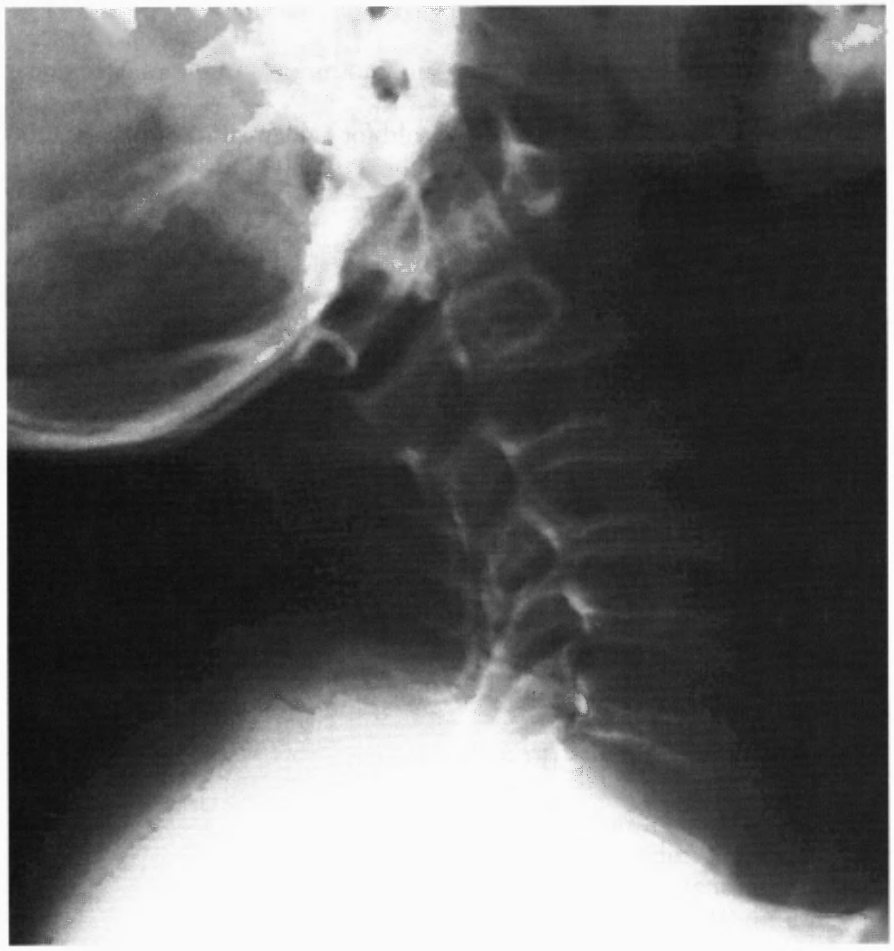

FIGURE 9-3. Spondyloepiphyseal dysplasia. The most consistent radiologic findings are a dysplastic odontoid process and flattened vertebrae.

Multiple Epiphyseal Dysplasia (MED)

- COMP or type IX (and type II) collagen abnormality.
- Short-limb disproportionate dwarf, age, AD.
- Epiphyseal; irregular epiphyseal ossification.
- Late waddling gait.
- Severe form is called Fairbanks.

Chondrodysplasia Punctate

- Multiple punctate calcifications; flat facies, stippled epiphysis.
- AD or autosomal recessive (AR); AR is fatal by 1 year of age.

Kneist Syndrome

- Type II collagen COL2A1 gene, parathyroid hormone (PTH) receptor problem (see Diastrophic Dysplasia and SED congenital).
- AD.
- Short trunk, disproportionate joint contractures, retinal detachment, dumbbell femora, scoliosis.

Dysplasia Epiphysealis Hemimelica (Trevor Disease)

- Epiphyseal osteochondroma.
- Metaphyseal, bowed legs, hemienlarged epiphysis.

Metaphyseal Chondrodysplasia

- AD/AR, metaphyseal, wide eyes, bowed legs.
- **Jansen's:** PTH receptor disorder, rare, AD, more severe, short-limb dwarf.
- **Schmid's:** Type X collagen disorder, AD, less severe.
- **McCusick's:** AR, "cartilage hair hypoplasia"; chickenpox susceptible.

Diastrophic Dysplasia

- Type II collagen disorder (see SED) and sulfate transport protein disorder.
- "Twisted dwarf."
- Cauliflower ear, hitchhiker thumb, short-limb dwarf.
- Kyphoscoliosis; rigid clubfeet.
- Not good candidates for limb lengthening.

Cleidocranial Dysplasia (Dysostosis)

- Core-binding factor (cbfal) disorder.
- *Proportionate* dwarf; affects bones that undergo intramembranous ossification.
- *Absent clavicles*, delayed physeal closure.

Mucopolysaccharidoses (Table 9-1)

- Hydrolase enzyme deficiency.
- *Proportionate* dwarf.
- Thick bones, *bullet metacarpals*.

Spondylometaphyseal Dysplasia

- Short, scoliosis, platyspondyly.
- Coxa vara, AD.

Morquio syndrome is the most common of the mucopolysaccharidoses and the only one with normal intelligence and urinary excretion of keratan sulfate.

TABLE 9-1. Mucopolysaccharidoses

Type	Name	Inheritance	Intelligence	Urinary Excretion
I	Hurler's (worst prognosis)	AR	↓	Dermatan/Heparan
II	Hunter's	XR	↓	Dermatan/Heparan
III	Sanfilippo's	AR	↓	Heparan
IV	Morquio's (most common)	AR	Normal	Keratan

AR, autosomal recessive; XR, X-linked recessive.

Diaphyseal Dysplasia

- Femurs are very wide throughout.
- Lack metaphyseal modeling.

Osteopetrosis

Gaucher mucopolysaccharidoses, MED, and SED (usually symmetric involvement) can mimic Perthes disease (asymmetric involvement).

- Osteoclast dysfunction.
- Dense bones.
- Obliterate medullary canal.
- *Anemia.*
- **Treatment:** Bone marrow transplant.

Gaucher Disease

- Can mimic Perthes disease.
- AVN and hepatosplenomegaly.

Marfan Syndrome

Marfan's patients can have superior lens dislocation, and patients with homocystinuria can have inferior lens dislocations.

- Fibrillin disorder, chromosome 15.
- Superior lens dislocation (and lateral), mitral valve prolapse.

Homocystinuria

- Methionine metabolism.
- Marfanoid-like habitus with stiffening joints.
- Inferior lens dislocation.

Down Syndrome

- Trisomy 21.
- Fuse C-spine if symptomatic or ADI > 10 mm (high complication rate).
- Patellofemoral instability.

Osteogenesis Imperfecta

- Type I collagen defect.
- Type II: Lethal early.
- Progressive bowing, scoliosis, kyphosis, basilar invagination.
- *Blue sclera.*
- Familial.
- Multiple fractures.
- IV bisphosphonate therapy can increase cortical thickness.

▶ PEDIATRIC TRAUMA

Fracture Remodeling

- Bone remodeling potential is partially based on the location of the fracture and the amount of growth that occurs there (Table 9-2).
- More growth means more remodeling potential.

TABLE 9-2. Percentage of Proximal and Distal Bone Growth

Bone	Proximal Growth	Distal Growth
Radius	25%	75%
Ulna	80%	20%
Humerus	80%	20%
Femur	30%	70%
Tibia	55%	45%
Fibula	60%	40%

Physeal Fractures

- Through zone of provisional calcification.

Galeazzi Fracture

- Distal radius fracture with distal radioulnar joint (DRUJ) disruption.
- For dorsal DRUJ dislocation: Splint in *supination*.

Supracondylar Humerus Fracture

- Most common nerve injury is anterior interosseous nerve (AIN).
- Varus malunion is most common (gunstock deformity).

Lateral Condyle Fracture

- If intra-articular, needs open reduction and internal fixation (ORIF).
- Potential complications: Late cubitus valgus and tardy ulnar nerve palsy.

Medial Epicondyle Fracture

- Treat nonoperatively.
- If ulnar nerve is trapped in joint, explore and perform ORIF.

Both-Bone Forearm Fracture

- Accepted reduction parameters (controversial):
  - If < 9 years old: Complete displacement, 15 degrees angulation, 45 degrees rotation.
  - > 9 years old: Bayonet opposition, 10 degrees angulation, 30 degrees rotation.

Radial Head Fracture

- Avoid transcapitellar pins.
- < 30 degrees angulation: Splint or cast.
- 30–60 degrees angulation: Attempt closed reduction (can use k-wire as joystick).
- > 60 degrees angulation: ORIF.

Olecranon Fracture

- Very common in osteogenesis imperfecta.

When treating pediatric fractures, conservative management is almost always the right answer.

Humerus Fracture

- Diaphysis and higher: Treat nonoperatively.
- 80% of growth at proximal humerus: Excellent remodeling potential.

AVN Risk with Femoral Head/Neck Fractures

- Femoral head fracture: 75%–100% AVN.
- Basicervical fracture: 50% AVN.
- Cervicotrochanteric fracture: 25% AVN.
- Intertrochanteric fracture: Low AVN risk.

Femoral Neck Nonunion

- Consider ORIF with valgus osteotomy.

Femoral Shaft Fractures

- 0–2 years of age: *Do not operate*, but immediate spica.
- 2–5 years of age: Spica is gold standard; if shortened more than 2 cm, consider traction followed by spica vs. ORIF vs. flexible nails.
- 5 years of age to skeletal maturity: ORIF vs. flexible nails vs. external fixation.
- *Overgrowth* may occur after healing.
- Do not use nail with piriformis starting point if the physis is open because the vascular supply is in the piriformis fossa with an *increased chance of* AVN.
- If patient has opening on varus/valgus stress of the knee, obtain stress x-rays to rule out distal femoral physeal injury.
- Most common complaint: Pain at nail insertion site.

OCD Lesions

- Active teenagers.
- First, immobilize until pain resolves.
- Begin motion; no sports for 4–6 months.
- Surgery for refractory cases: Transarticular or retroarticular drilling.
- Poor results with excision alone.

Intercondylar Eminence Fractures

- Functional equivalent of ACL rupture.
- Aspirate and attempt to reduce in extension and long leg cast.

- If completely displaced or irreducible, open or arthroscopic fixation is required.
- Beware entrapment of *anterior horn medial meniscus.*

Tibial Tubercle Fracture

- If extra-articular: Closed reduction and cast.
- Intra-articular: ORIF. Meniscus may be injured (arthroscopy with ORIF); periostium prevents reduction.

Patella Sleeve Fracture

- Will need operative fixation.

Toddler's Fracture

- Normal x-ray, yet toddler is unable to bear weight (rule out infection).
- Place the child in a cast.

Proximal Metaphyseal Fracture

- Prone to valgus deformity.
- Typically, deformity resolves with time.

Tillaux Fracture

- Fracture of the lateral distal tibia, which is attached to anterior tibiofibular ligament.

Triplane Fracture

- Distal tibia fracture that appears as Salter-Harris type III on AP x-ray and Salter-Harris type IV on lateral x-ray.

Corner Fractures

- Consider possible abuse.
- Notify protective services.

Odontoid Fracture

- Closed reduction and halo (use more pins, torque should be about half the age).

Thoracic and Lumbar Compression Fracture

- Treat symptomatically.

NOTES

CHAPTER 10

The Spine

General Spine 219

Anatomy 219

Normal Disk Aging 219

Cauda Equina Syndrome 219

Spinal Cord Injury (SCI) 219

Autonomic Dysreflexia 220

Miscellaneous 220

Cervical Spine 221

Herniated Nucleus Pulposus (HNP) C5–6 221

Anterior Cervical Decompression and Fusion (ACDF) Complications 221

Carotid Sheath 222

Sympathetic Chain 222

Stenosis 222

Neck Flexion 222

Rheumatoid C-Spine 222

Superior Migration of the Odontoid (SMO) 222

Atlantoaxial Instability (AAI) 222

Cervical Myelopathy 222

C1 Fracture (Jefferson) 223

Odontoid Fracture 223

Hangman's Fracture (Bilateral Pars or Pedicle Fracture of C2) 223

Ankylosing Spondylitis 224

Pseudosubluxation 224

Halo Complication 224

Pediatric Halo 225

Burst Fracture 225

Chance Fracture 225

C-Spine Fusion 225

Lumbar Spine 225

Dermatome Highlights 225

Posterior Elements 225

Low Back Pain 225

Dural Tear 226

Herniated Nucleus Pulposus 226
Tension Signs 226
Lumbar Stenosis 226
Transperitoneal Approach to L5–S1 226
Infection 227
Postoperative Diskitis 227
Spine Tumors 227
Winking Owl 227
Adenocarcinoma Metastases 227
Tumors in Posterior Elements 227
Tumors in Anterior Elements 227
Chordoma 228
Neurofibromatisis 228
Plasmacytoma 228
Isthmic Spondylolisthesis 228
Degenerative Spondylolisthesis 228
Adult Spine Deformity 228
Adult Scoliosis 228
Kyphosis 229

Anatomy

- There are 8 cervical roots.
- Cervical roots exit the C-spine above the pedicle of the matching vertebrae (e.g., C2 nerve root exits above the C2 pedicle).
- All other roots exit beneath the corresponding vertebrae (e.g., L2 nerve root exits beneath L2 pedicle).
- C1–2 primary restraint: Transverse ligament.
- Rupture of transverse ligament: 3–5 mm ADI.
- C1–2 secondary restraint: Alar and apical ligaments.
- Rupture of secondary restraint: > 5 mm ADI, or < 14 mm PADI.

Normal Disk Aging

- Fewer glycosaminoglycans.
- Less water.
- Less chondroitin sulfate and more noncollagen glycoprotein (keratin sulfate).
- Decreased cell number.

In the aging spine, normal lumbar lordosis decreases; kyphosis of the thoracic spine increases; coronal balance is usually unchanged.

Cauda Equina Syndrome

- Low back pain.
- Saddle anesthesia.
- Urinary retention.
- *Surgical emergency.*

Spinal Cord Injury (SCI)

- **Incomplete SCI:** Stabilize to protect recovery, decompress at plateau (early) (see Table 10-1).
- **Complete SCI:** Stabilize operatively for rehabilitation.

Neurogenic Shock

- Hypotension, relative *bradycardia.*
- Treatment: Swan-Ganz cardiac monitoring, pressors.

Neurogenic shock will present with hypotension and relative bradycardia, whereas hypovolemic shock will present with hypotension and tachycardia.

TABLE 10-1. Incomplete Spinal Cord Injury

Anterior cord syndrome	Motor loss, some sensory preservation, *worst prognosis.*
Central cord syndrome	Most common, *UE > LE weakness*, fair prognosis.
Brown-Séquard syndrome	*Penetrating trauma,* ipsilateral paralysis, contralateral pain/temp, best prognosis.
Posterior cord syndrome	Motor preserved below, but *position/vibratory sense out;* rare.
Conus medullaris syndrome	Isolated loss bowel/bladder function (usually T12–L1, can be T11–L2).

LE, lower extremity; UE, upper extremity.

Steroids

- 30 mg/kg first hour, then 5.4 mg/kg/hr for 23 hours if < 3 hours from injury.
- Continue for 48 hours if 3–8 hours from injury.

Gunshot Wounds

- If bowel is violated: 7 days broad-spectrum IV antibiotics.
- Do not remove fragments unless causing neuro symptoms.

Autonomic Dysreflexia

- Headache, agitation, hypertension.
- Can be fatal.
- **Treatment:** Check Foley, disimpact stool.

Miscellaneous

- **The Oswestry Disability Index** is the most specific lumbar spine outcomes instrument.
- **Nucleus pulposus:** Resists compressive loads; mainly type II collagen.
- **Annulus fibrosis:** Mainly type I collagen.
- **A sequestered herniated disk** will show greatest resorption.
- **T5:** Narrowest pedicle (except a T7 concave side in scoliosis).
- **Artery of Adamkiewicz:** Most often at T9–11 on *left* side.
- **Dural ectasia** can be seen with Marfan syndrome (60%), neurofibromatosis (NF), and Ehlers-Danlos syndrome.
- **Thoracolumbosacral orthosis (TLSO)** with *thigh extension* to immobilize the lumbosacral junction. Without extension will only immobilize to L1–L2.
- A corset brace does not change spinal motion; it reduces intradiskal pressure.
- **S2–5 roots** are *dorsal* and *central* to **L5–S1 roots.**
- **Bladder innervation:** S2, S3, S4.
- **Instability:** If unilateral, facetectomy; > 50%, both facets.
- **Short-form 36** is an excellent tool for monitoring patients' perception of *treatment outcome* of cervical myelopathy.
- **The spinal canal** is 95% expected cross-section at age 5.
- **Patrick's test (FABER):** Flexion, ABduction, External Rotation of the hip isolates the **sacroiliac (SI) joint.**
- **Kernig's sign:** Supine, flex head/neck to elicit root or meningeal irritation.
- **Lasègue's sign:** Straight leg raise (SLR) with immobile hip flexed.
- **Femoral stretch test:** Prone or lateral, extend hip with knee flexed—checks for femoral neuritis.
- **Pulmonary embolism** after spine surgery: Vena cava filter. Heparin has more complications.
- **Decompression** should be done on the side of the pathology (i.e., an infection in the anterior elements gets an anterior decompression).
- **Nicotine** inhibits bone formation (higher risk for nonunion).
- **Segmental instability of the C-spine:** 3.5-mm translation or 11 degrees angulation on flex/ex films.
- **Segmental instability of L-spine:** 4-mm translation or 10 degrees angulation on flex/ex films.
- **Biomechanics:**
  - Anterior column devices:
    - *Structural support*: Bone graft, cages, arthroplasty.
      - Act as interbody devices.

Os odontoideum is an absolute contraindication to playing football.

An athlete with an acute cervical disk herniation should not return to play until symptoms resolve.

Halo pins: Adults: 4 pins at 8 in·lb torque each; Peds: 8 pins at 4 in·lb torque each.

- *Cantilever support*: Plates and rods.
  - Act as tension bands.
- Flexion: Loads graft.
- Extension: Unloads graft.
- An anterior plate moves the axis of rotation *anteriorly*.
- Posterior column devices:
  - *Structural support*: Interprocess devices (not used much now).
  - *Cantilever devices*: Plates, rods, pedicle fixation, spinous process wiring.
    - Act as tension bands.
    - Prevent flexion.
    - Little resistance to extension.

▶ CERVICAL SPINE

Herniated Nucleus Pulposus (HNP) C5–6

- Most common cervical herniation.
- *Posterolateral* disk affects C6 root (most common) (see Table 10-2).
- *Far lateral* affects C5 root.
- **Magnetic resonance imaging (MRI)**:
  - < 40 years old: ~14% false positives.
  - > 40 years old: ~28% false positives.

Anterior Cervical Decompression and Fusion (ACDF) Complications

- Recurrent laryngeal nerve injury risk higher at *lower* C-spine levels (C6–7).
- Most commonly due to larynx on endotracheal tube by retractors.
- Dysphagia risk: Higher at *upper* C-spine levels (C3–4).
- Nonunion rate is 2%–10%.
- Increases with increased number of fusion levels.
- Airway compromise.
- Vertebral artery injury.
- Persistent hoarseness:
  - Needs direct laryngoscopy.
  - Ear, nose, and throat (ENT) consult—possible Teflon injection.
- **Nonunion:** If asymptomatic, observe.
- Single-level ACDF is NOT a contraindication to play for athletes and is the option of choice if nonsurgical management fails.

TABLE 10-2. Common Cervical Radiculopathies

Level	Motor Weakness	Sensory Involvement	Reflex Affected
C5	Deltoid, shoulder external rotators	Lateral shoulder and upper arm	Biceps
C6	Biceps and wrist extension	Radial forearm, thumb, and index finger	Brachioradialis
C7	Triceps, wrist flexion, finger extension	Middle finger, posterolateral arm	Triceps

Carotid Sheath

- Contains the internal jugular, internal carotid, and vagus nerve.

Sympathetic Chain

- Is on the lateral border of the longus colli muscle at C6.
- Injury can cause Horner syndrome.

Degenerative spondylolysthesis of the C-spine: C3–4 and C4–5; degenerative changes are most commonly at C5–6 and C6–7.

Stenosis

- < 13 mm (normal is ~17 mm).
- Prognosis depends on the severity of *preoperative myelopathy.*

Neck Flexion

- Spinal cord elastic deformation; spinal canal *lengthens.*

Rheumatoid C-Spine

- **Ranawat I:** Neck pain.
- **Ranawat II:** Dysesthesias, upper motor neuron (UMN) signs, normal strength.
- **Ranawat III:** Objective weakness.
  - A: Ambulatory.
  - B: Nonambulatory.
- Postoperative neurologic recovery dependent on atlantoaxial interval:
  - 14 mm or greater: No increased risk of neurologic compromise.
  - 10–14 mm: Increased risk of paralysis, better prognosis than an interval that is < 10 mm.
  - 10 mm or less: Poor prognosis for recovery (25% of Ranawat IIIb).

THE SPINE

Superior Migration of the Odontoid (SMO)

- Tip of dens above foramen magnum.
- **Surgical indications:**
  - Space available for the cord (SAC) < 14 mm.
  - Ranwat IIIA.
  - SMO/BI (basilar invagination): If BI, should consider fusing to the occiput.

The most important clinical predictor of clinical outcome in a patient with cervical myelopathy is gait changes.

Atlantoaxial Instability (AAI)

- AAI 8–10 mm or neurologic signs: Consider surgery.
- Withhold from contact sports if AAI is > 5 mm.

Cervical Myelopathy

- **Gait changes** are the most important clinical predictor.
- Usually caused by cervical spondylosis.
- Fixed cervical kyphosis > 10 degrees is a *contraindication* to posterior decompression.
- Laminectomy alone can result in progressive kyphosis; need fusion too.

Quick Reference: Treatment of Symptomatic Cervical Spondylosis

Characteristic	Anterior or Posterior Fusion?
Fusing 3 or more levels	Posterior
Fusing fewer than 3 levels	Anterior
Elderly patient	Posterior
Revision	Posterior
Kyphosis	Anterior (*no* laminoplasty)
Lordosis	Posterior

C1 Fracture (Jefferson)

- Open-mouth x-ray showing > 7-mm spread of lateral masses indicates transverse ligament injury.
- **Bony avulsion** will typically heal in halo.
- **Soft tissue avulsion** needs surgery.

Odontoid Fracture

- **Type II:** Treat with halo unless elderly, 5-mm initial displacement, > 10 degrees angulation or irreducible, then C1–2 posterior spinal fusion.
- **Type II:** Treat with C1–2 fusion if nonunion in halo vest.
- **Type III:** Treat with halo.
- Transarticular screws best stabilize flexion, extension, and rotation in C1–2 fusion.
- **Risk factors for nonunion:** Smoking, displacement > 6 mm, age > 60 years, poor reduction.
- **Obesity** is NOT a risk factor for nonunion.

Hangman's Fracture (Bilateral Pars or Pedicle Fracture of C2)

- **Mechanism:** Hyperextension followed by flexion.
- **Type I:**
  - Vertical fracture, no angulation.
  - < 2–3-mm fracture displacement.
  - Can treat with *hard collar.*
- **Type II:**
  - > 3-mm fracture displacement.
  - > 11 degrees angulation.
  - Associated with wedge compression.
  - Will need closed extension traction/reduction and *halo.*
  - Acceptable reduction: < 4 mm translation and < 10 degrees angulation.
- **Type IIA:**
  - Minimal translation with *severe angulation.*
  - DO NOT DISTRACT THIS FRACTURE!
  - Treatment: Extension with *compression* and halo. Fusion after 6 weeks if not healing.

Never distract a Type IIA C2 (Hangman's) fracture as paralysis will occur.

- Type III:
  - Jumped facets.
  - Will need open reduction, PSF, and halo.
- **Kyphotic deformity:** Reduce in extension, *not traction.*

Ankylosing Spondylitis

- Patients are at high risk for *extension-type C-spine fracture.*
- If delayed neurologic deficit, consider *epidural hematoma.* Requires evacuation and laminectomy decompression.
- Fractures are inherently unstable and require fusion.
- X-rays:
  - Marginal osteophytes (bamboo spine).
  - Compared to diffuse idiopathic skeletal hyperostosis (DISH): Nonmarginal.

Pseudosubluxation

When placing halo pins, keep them below the equator of the head and keep the anterior pins lateral to the midpoint of eyebrow (> 4.5 cm from midline).

- Usually occurs in patients < 4 years old.
- Usually occurs at C2–3 (secondary to horizontal facet orientation in children).
- Key to differentiate from true subluxation:
  - There is no history of significant trauma.
  - The deformity reduces on extension films.

Halo Complication

- Most common to least common: Pin loosening > infection > discomfort > dural/sinus puncture (see Figure 10-1).
- **Anterior pins:** Beware of frontal sinus, supratrochlear nerve, supraorbital nerve.

FIGURE 10-1. Halo complication. Head CT showing penetration of the frontal sinus by an anterior pin.

Pediatric Halo

- Use more pins (6–8).
- Less torque (4–5 ft·lb); adults require 8 ft·lb.
- If < 2 years old, Minerva cast is a treatment consideration.

Burst Fracture

Consider operative management if:

- > 50% canal compromise.
- > 20 degrees kyphosis.
- > 50% loss of vertebral body height.

Chance Fracture

- **Mechanism:** Flexion/distraction.
- High incidence of *abdominal visceral injury.*
- **Treatment:**
  - **Bony chance:** Typically cast/brace.
  - **Soft tissue chance:** Often fusion with instrumentation.

C-Spine Fusion

- C1–C2 transarticular screw danger: Vertebral artery injury when directed too caudad.

▶ LUMBAR SPINE

Dermatome Highlights

- **L3:** Thigh
- **L4:** Medial leg
- **L5:** Dorsum of foot
- **S1:** Lateral/plantar foot
- **S2–5:** Perianal sensation

Posterior Elements

- Bear 20% vertical load in upright position.

Low Back Pain

- X-ray only if concern for:
  - Tumor
  - Infection
  - Trauma
  - Cauda equina syndrome (CES)
  - Failed conservative treatment (not in first month) because 95% of patients improve in first 4–6 weeks.
- **L4–5:** Most common level for disk disease.
- Most common risk factor: Exposure to vibration.

L5 nerve root compression can cause weakness of the extensor hallucis longus with normal ankle and patellar reflexes.

Dural Tear

- Get pia-arachnoid plug in first few days.
  - Bulbous dura edges have *fibroblastic proliferation.*

Herniated Nucleus Pulposus

- **Posterior lateral** (most common) compresses lower root. If L4–5 level, the L5 root would be compressed.
- **Foraminal (far lateral)** compresses upper root. If L4–5 level, the L4 root would be compressed.
- MRI with gadolinium will best identify recurrent disk herniation and can distinguish disk from scar.
- Natural history: 90% better in 1 month with non-op.
- Increase intradiskal pressure (lowest to highest):
  - Supine
  - Standing
  - Sitting
  - Sitting leaning forward
- **Surgical indications:**
  - CES
  - Progressive weakness
  - Persistent disabling pain
- **Operative complications:**
  - Dural tear (treat with watertight closure).
  - Recurrence.
  - Diskitis (treat with needle biopsy and antibiotics).
  - Vascular catastrophe.
  - Most common complication of total disk arthroplasty: Transient radicular leg pain.

Extruded disk herniations respond better to steroid injection than contained herniations.

Tension Signs

- **L5–S1:** SLR.
- **L3–4:** Femoral nerve stretch test.

Poor bone quality is a major risk for pull-out of pedicle screws.

Lumbar Stenosis

- **Conservative treatment**:
  - Williams flexion exercises.
  - Nonsteroidal anti-inflammatory drugs (NSAIDs).
  - Brace
  - Injections
- **Surgery** (decompress and fuse) for patients with persistent pain or progressive weakness.
- Migration of interbody fusion cages is associated with a posterior approach; NOT with design, use of BMP, or pseudarthrosis.

Persistent leg pain after dikcectomy: Incomplete or recurrent dikcectomy vs. perineural (epidural) fibrosis.

Transperitoneal Approach to L5–S1

- Must protect *superior hypogastric plexus* during exposure.
- **Retrograde ejaculation** can result from injury to the *superior hypogastric plexus.* Dissect from *left to right* to minimize this risk.
- Sympathetic trunk at risk along the medial boarder of the psoas; injury will cause a cold, pale foot.

Infection

- Spinal infection (most specific and sensitive) test: Combined technetium-99 and gallium 67 citrate scans.
- Usually hematogenous, endplate erosion > disk destruction.
- Disk is involved on MRI (tumor does not typically involve disk).
- Most common presenting sign or symptom: Back pain.
- **Treatment:**
  - CT-guided needle biopsy/blood culture. Open biopsy if CT-guided fails.
  - Rest.
  - IV antibiotics for ~12 weeks.
  - Surgery if tissue destruction, significant deformity, abscess, or neurologic deficit.
    - Anterior debridement and decompression.
    - Possible autologous strut graft.

Postoperative Diskitis

- ~2–4 weeks postop.
- Low back pain.
- Low-grade fever.
- Increased white count.
- **Diagnosis and treatment:**
  - MRI with gadolinium.
  - Needle biopsy.
  - Rest and IV antibiotics.

▶ SPINE TUMORS

Winking Owl

- X-ray finding of missing pedicle due to metastases.

Adenocarcinoma Metastases

- Most commonly go to the spine.
- Due to Batson's plexus (valveless).
- Unless a mass appears in the setting of active cancer elsewhere, a CT-guided biopsy is needed to guide treatment.
- In a patient with metastases to the spine and neuro compromise, decompression and fusion should be performed if the patient has a reasonable life expectancy.

Tumors in Posterior Elements

- Typically *benign:* Osteoid osteoma, osteoblastoma.
- **Treatment:** Excisional vs. intralesional biopsy.
  - Curettage has high recurrence rate.

Tumors in Anterior Elements

- Typically *malignant:* Ewing's sarcoma, osteosarcoma, lymphoma, myeloma, metastases.
- Other possible nonmalignant: Hemangioma, giant cell tumor, eosinophilic granuloma.

The pretreatment neurologic status of the patient is the main determinant of postoperative neurologic status when treating spine tumors.

Chordoma

- Midline: In clivus or sacrum (top or bottom).
- **Pathology:** Physaliphorous cells.
- **Treatment:** En bloc resection with negative margins; they are resistant to radiation and chemotherapy.

Neurofibromatisis

Multiple foraminal enlargement (lateral x-ray).

Plasmacytoma

- Sensitive to irradiation.
- If structurally unstable: Fuse then irradiate.

▶ ISTHMIC SPONDYLOLISTHESIS

- **L5–S1:** L5 root compression (*foraminal stenosis*).
- **Treatment:** Conservative management unless pain persists > 6 months or progressive deficit.
- **Slip progression:**
  - 5% of patients with spondylolysis.
  - More common in girls.
  - Rare after skeletal maturity.

▶ DEGENERATIVE SPONDYLOLISTHESIS

- If slip progresses: Posterior-lateral fusion.
- With associated spinal stenosis (produces neurogenic claudication): Decompression and fusion.

▶ ADULT SPINE DEFORMITY

Adult Scoliosis

- **Canal stenosis:** In concavity of curve.
- **< 30-degree curve:** *Rarely progresses.*
- **> 50-degree curve:** *Commonly progresses.*
- **Surgical indications:**
  - Curve progression
  - Intractable curve pain
  - Cosmesis
- High failure rate if instrumentation does not extend to sacrum.
- Can stop at L5 only if L5–S1 has no structural problems (e.g., prior laminectomy, facet arthrosis, spondylolysis).
- Lumbosacral fusion is improved with fusion to both the sacrum and ilium.

Kyphosis

- **Osteoporosis:** Medical management, kyphoplasty/vertebroplasty.
- A vertebral compression fracture associated with osteoporosis increases the risk of adjacent compression fractures as the sagittal alignment shifts anteriorly.
- **Scheurmann's:** Observe unless persistent pain or patient feels it is an unacceptable deformity.
- Instrumentation must extend to first lordotic segment to avoid junctional kyphosis.
- **Posttraumatic:** Consider fusion if > 55 degrees of deformity.

NOTES

CHAPTER 11

Miscellaneous Facts

Imaging 233
- Magnetic Resonance Imaging (MRI) 233
- Computed Tomography (CT) 234
- Bone Scan 234
- Arthrography 234
- Dual-Energy X-ray Absorptiometry (DEXA) 234
- Ultrasound (US) 234

Rehabilitation 234
- Muscle Contractions 234
- Rotator Cuff Repair 235
- Vascular Claudication 235
- Endurance Training 235
- Strength Training 235
- Stroke and Cord Injury Patients 235
- Motor Exam 235
- Autonomic Dysreflexia 236
- Polio 236
- Gait 236
- Miscellaneous 237

Amputations 237
- Upper Extremity Amputation 237
- Above-Knee Amputation (AKA) 237
- Below-Knee Amputation (BKA) 237
- Ankle/Foot Amputation 238
- Energy and Oxygen 238
- Vascular and Diabetes 238
- Wound Healing 238
- Pediatric Amputations 239
- Prosthetics 239
- BKA Prosthetic Concerns 239
- Miscellaneous 240

Orthotics 240
Charcot Joints 240
Miscellaneous Medically Related Issues 241
Abuse 241
Miscellaneous Diseases 241
Caffey Disease (Infantile Cortical Hyperostosis) 241
Atlantoaxial Rotatory Subluxation 241
Emotional Hyperhidrosis (Sweaty Feet) 241
Miscellaneous Medications 241
Perioperative Problems 242
Transfusion 242
Deep Venous Thrombosis (DVT) 242
Pulmonary 242
Cardiac 243
Nutrition 243
Practice Principles 243
Definitions 243
Malpractice 243
Statistics 243
Types of Tests 245
Types of Studies 245
Levels of Evidence (Per *Journal of Bone and Joint Surgery*) 245
Miscellaneous 246
Malignant Hyperthermia 246

Magnetic Resonance Imaging (MRI)

- **T1:** Weighted toward fat; best for anatomic structure (see Table 11-1).
- **T2:** Weighted toward water; contrasts normal and abnormal tissue.
- **Contraindications:** Pacemakers, aneurysm clips, metal in certain locations.
- Cortical bone, tendon, ligament, fibrocartilage are low on T1 and T2.
- **Synovial cyst:** Dark T1, bright T2; needle aspirate after MRI (+/–).
- Helpful to diagnose avascular necrosis (hip, knee, humerus, etc), scaphoid fracture, elderly hip fracture.

Cortical bone, tendon, ligament, and fibrocartilage are low on T1 and T2.

TABLE 11-1. MRI Characteristics

Tissue	T1	T2
Cortical bone	Dark	Dark
Ligaments	Dark	Dark
Tendon	Dark	Dark
Fibrocartilage	Dark	Dark
Meniscus	Dark	Dark
Hyaline	Gray	Gray
Red bone marrow	Gray	Gray
Muscle	Gray	Gray
Normal fluid	Dark	Bright
Osteomyelitis	Dark	Brighter
Marrow edema	Dark	Bright
Meniscal tear	Bright	Gray
Yellow bone marrow	Bright	Gray
Fat	Bright	Gray
Pus	Gray	Bright
Disk		
Central	Gray	Bright
Peripheral	Dark	Gray

Tumors that can be cold on bone scan: Multiple myeloma, renal, thyroid, and enostosis.

Computed Tomography (CT)

- Better for bony anatomy inspection.
- Leg length discrepancy, spinal stenosis, subtalar coalition identification, and osteolysis extent.

Bone Scan

- Technetium-99m phosphate complexes denote increased blood flow and metabolism.
- Absorbed onto bone in areas of infection, tumor, or trauma.
  - Phase 1: Blood flow, immediate.
  - Phase 2: Blood pool, 30–45 minutes.
  - Phase 3: Delayed, about 4 hours.
- Cold on bone scan: Multiple myeloma, renal tumors, thyroid tumors, enostosis.
- **Gallium scan:**
  - Gallium 67 citrate localizes inflammation and tumor.
  - Difficult to delineate infection and cellulitis.
- **Indium scan:** Indium 111–labeled white blood cells accumulate in areas of infection, *not* in tumor beds.

Arthrography

Can be utilized in a variety of joints to diagnose loose bodies or cartilage defects.

- Shoulder: Rotator cuff tear and adhesive capsulitis (historical).
- Pediatric hip dysplasia.
- MRI is improving and making this technique less pertinent.
- MR arthrogram: Improved visualization over standard MRI.

Dual-Energy X-ray Absorptiometry (DEXA)

- Helpful in predicting fracture risk.

Ultrasound (US)

- Color Doppler US has improved sensitivity for detecting deep venous thrombosis (DVT).
- Highest for detecting thigh DVTs.

▶ REHABILITATION

Muscle Contractions

- **Eccentric:** Contraction while the *muscle lengthens.*
- **Concentric:** Contraction with *shortening of the muscle.*
- **Isotonic:** Concentric and eccentric motions.
- **Isometric:** Contraction with muscle remaining a *constant length.*
- **Isokinetic:** *Speed* is controlled and maximum exertion occurs throughout the range of motion (ROM) (need Cybex).

Rotator Cuff Repair

- Postoperative: Pendulum and passive forward flexion and ER.
- Intermediate: Closed kinetic chain.
- 12 weeks: Open kinetic chain resistance.
- For return to play: Plyometrics.

Vascular Claudication

- Pain improves with stopping and standing still.
- Starts distally and moves proximally.

Endurance Training

- Increased aerobic capacity.
- Decreased heart rate.
- Improves lipid profile.
- Increased bone mineral density with weight-bearing activities.
- Normalizes blood pressure.

Strength Training

- Increases muscle strength.
- Increases muscle cross-sectional area and myosin filament volume.
- Increases type II fiber area.
- Decreases body fat percentage.
- Preserves bone mineral density.
- Improves gait speed.

Stroke and Cord Injury Patients

- Delay surgical intervention for 6 months in cerebrovascular accident (CVA); 12–18 months for traumatic brain injury.
- **Balance** is the best predictor for ambulation potential.
- **Functional level** corresponds to the most distal intact dermatome and most distal motor level:
  - **Motor level** after spinal cord injury: Defined as intact motor at least 3/5.
  - **C4**: Patients require high back and head support; dependent transfers.
  - **C5**: Mouth-driven accessories, control motorized wheelchair; assisted transfers.
  - **C6**: Patients can operate manual wheelchairs, use flexor hinge wrist and hand orthosis; independent transfers.
  - **C7**: Patients can feed and groom themselves.

Functional motor level of spinal cord–injured patient is intact motor of at least 3/5.

Motor Exam

Grading

- 0 = Total paralysis.
- 1 = Palpable and/or visible movement.
- 2 = Active movement, full ROM with gravity removed.
- 3 = Active movement, full ROM against gravity.
- 4 = Active movement, full ROM against moderate resistance.
- 5 = Active, full ROM against full resistance.

Upper Extremities

There is some overlap, but here is a general framework:

- **C4:** Diaphragm.
- **C5:** Elbow flexors (biceps and brachialis).
- **C6:** Wrist extensors (extensor carpi radialis longus, extensor carpi radialis brevis).
- **C7:** Elbow extensors (triceps).
- **C8:** Finger flexors (flexor digitorum profundus to middle finger).
- **T1:** Small finger abductor (abductor digiti minimi manus).

Lower Extremities

There is some overlap, but here is a general framework:

- **L2:** Hip flexors (iliopsoas).
- **L3:** Knee extensors (quadriceps).
- **L4:** Ankle dorsiflexors (tibialis anterior).
- **L5:** Long toe extensors (extensor hallucis longus).
- **S1:** Ankle plantar flexors (gastrocnemius–soleus).

Autonomic Dysreflexia

- Injuries above T6.
- Acute sympathetic hyperactivity.
- Chest tightness, sweating, headache.
- Hypertension, bradycardia, hyperthermia.
- Bladder distention, infection, pressure, *fecal impaction*.
- **Treatment:** Catheterize, disimpact, etc.
- Can be fatal.

Polio

- Anterior column, muscle paralysis, normal sensation.
- Postpolio syndrome: Aging with loss of neurons.
- Do *not* treat postpolio syndrome with exercising, as this can make things worse.

Gait

- **Gait cycle:** Initial contact, stance, toe off, swing:
  - **Step:** Heel of one foot to the heel of the other.
  - **Stride:** Same foot heelstrike to heelstrike.
  - **Foot flat:** The most stable portion of gait.
  - **Cycle:** Initial contact to initial contact.
  - **Cadence:** Steps per minute.
  - **Weight bearing:** Both feet on ground, 10% of phase.
  - **Center of gravity:** Anterior to S2 (some say anterior to T10).
  - Trunk and arms are 70% of body weight.
- **Walking:**
  - Has a double-limb support phase.
  - Stance phase is 60% and swing phase is 40%.
- **Running:**
  - Has a free-float phase.
  - Most muscle activity is eccentric because this is more efficient (3–9 times).

- **Pathologic gaits:**
  - **Antalgic gait:** Shortened stance phase on that side.
  - **Abductorlurch:** Weak gluteusmedius/minimus (superior gluteal nerve).
  - **Flatfoot gait:** Weak gastrocnemius (posterior tibial nerve).
  - **Steppage gait:** Weak tibialis anterior and peroneals (peroneal nerve injury).
    - Equinus and varus foot with back-set knee.
  - **Hemiplegia:** Equinus and greater hip flexion.
- A **cane** helps to shift center of gravity toward injured side and thus lessens joint reaction forces due to shorter lever arm.
- **Leg length discrepancy:**
  - Greater mechanical work by long leg.
  - Greater stance time on long leg.
  - Step length longer on long leg.
  - Overall walking velocity is slower.
  - Increased ground reaction forces on long limb.

Long leg has greater mechanical work, longer stance time, longer step length, and increased ground reaction forces.

Miscellaneous

- **Muscle fiber adaptation** is best influenced by neuromuscular facilitation.
- **Frozen shoulder:** Treat with physical therapy first, before manipulation and possible lysis of adhesions.
- **Ankle sprain:** Treat with strength and proprioception training.
- **Postexercise soreness** is due to inflammation.

Muscle fiber adaptation is influenced by neuromuscular facilitation.

▶ AMPUTATIONS

Upper Extremity Amputation

- Wrist disarticulation advantage vs. transradial:
  - Better suspension with distal radial flare.
  - Preserved forearm rotation.
- **Voluntary opening hook:**
  - Terminal device activated by shoulder abduction and flexion.
  - Elbow mechanism is controlled by shoulder extension and depression.
  - Step-up hinge for short transradial.
- Harness ring at C7 on intact side.
- **Upper extremity prosthetic limb** use is best when fitted within 30 days (85% vs. 30%).
- **Myoelectric prosthesis** is best for sedentary work.
- A farmer with arm amputation does better with voluntary opening prosthesis.

Above-knee amputees benefit greatly from having an adductor myodesis (70% muscle force loss without the myodesis).

Above-Knee Amputation (AKA)

- Perform an adductor myodesis.
- Adductor magnus attachment loss results in 70% loss of muscle force.
- Transfemoral amputation utilize hydraulic knee.
- AKA patients need 5–10 degrees of adduction of the femur for better prosthetic fit.

Below-Knee Amputation (BKA)

- Transtibial amputation: 12–15 cm below knee joint to ensure adequate lever arm.
- BKA patients need 7–10 degrees of flexion for better prosthetic fit.

- Traumatic BKA: Lower back pain is a common late concern.
- Elderly patient and BKA: 31%–50% return to preoperative function level (only 10% after AKA).

Ankle/Foot Amputation

Attempt to perform great toe amputations distal to the FHB insertion.

- **Ankle disarticulation:** Bevel malleoli.
- **Syme amputation:** Patent *tibialis posterior artery* is a prerequisite.
- Equinus deformity after midfoot or hindfoot amputation is a common concern; combine a percutaneous tendoachilles lengthening to help minimize this risk.
- **Isolated second toe amputation** should be distal to proximal phalanx flare. This technique helps minimize hallux valgus.
- **Great toe amputation** distal to flexor hallucis brevis (FHB) insertion if possible.

Energy and Oxygen

Energy expenditure is inversely proportional to limb length.

- Energy expenditure is *inversely proportional* to limb length.
- Transfemoral amputees have near maximum energy expenditure with "normal" walking.
- Energy expenditure compared with normal limb:
  - AKA, 65% more.
  - Bilateral BKA, 40% more.
  - Short BKA, 25% more.
  - Long BKA, 10% more.
- More proximal amputation results in decreased self-selected and maximum walking speed.
- Oxygen consumption is increased as well with more proximal amputation.

Vascular and Diabetes

- Postamputation survival at 3 years is only 50%.
- Reamputation rate is 56%.
- 25% have contralateral amputation within 2 years.
- Patients older than 75 rarely walk again after amputation.
- Fracture in diabetes, non–weight bearing for extended period.

Wound Healing

Can be improved if the following are present:

- Transcutaneous oxygen tension > 30 mm Hg (ideally > 45 mm Hg).
- Toe pressures > 40 mm Hg.
- < 20 mm Hg will not heal.
- Ankle-brachial index (ABI) ≥ 0.45.
- Albumin > 3.0 g/dL.
- Total lymphocyte count (TLC) > 1500/mm^3.
- Hemoglobin > 10 g/dL.
- If blood supply is sufficient in a febrile patient who has undergone a partial foot amputation, give an organism-specific antibiotic and local wound treatment until nutritional status improves; then wound closure or amputation at a higher level can be considered.

Pediatric Amputations

- Risk overgrowth, most common at humerus.
- Consider through-joint amputation or stump capping.

Pediatric amputations have a propensity for overgrowth; consider capping or throughjoint amputations.

Prosthetics

- **Polycentric knee** (four-bar linkage) is best for BKA, knee disarticulations, and bilateral amputees.
- **Constant-friction knee:** Only a single speed; not good for older patients.
- **Fluid-control knee** (hydraulic and pneumatic): Adjusts cadence; best for active patients.
- Polycentric is preferred for stability and hydraulic for cadence—can combine these concepts.
- **Prosthetic feet:**
  - **SACH:** Solid Ankle Cushioned Heel (previous standard); problems with contralateral foot overload.
  - **Articulated dynamic response feet** decrease shear and absorb energy better.

BKA Prosthetic Concerns

- See Table 11-2 for a summary of BKA prosthetic concerns.
- **Ascend stairs:** Lead with sound side.
- **Descend stairs:** Lead with prosthetic side—it is always lower (closer to the ground).
- **Pistoning** can be due to:
  - Poor socket fit.
  - Volume changes.
  - Ineffective suspension mechanism.

TABLE 11-2. BKA Prosthetic Concerns

Foot Position	Gait Abnormality
Posterior placement	Increased knee flexion/instability
Forward placement	Increased knee extension (patellar pain) but stable
Inset	Varus strain, pain (proximal-medial, distal-lateral), circumduction
Outset	Valgus strain, pain (proximal-lateral, distal-medial), broad-based gait
Dorsiflexed	Increased patellar pressure
Plantar flexed	Drop off, patellar pressure, increased knee extension
Foot soft	Increased knee extension and foot slap
Foot hard	Increased knee flexion and lateral rotation

Prosthetic lower extremity is lower when ascending or descending stairs. When ascending, lead with sound side; when descending, lead with prosthetic limb.

Upper extremity amputees are more likely to use a prosthesis if early prosthetic fitting was implemented.

- Socket with insufficient flexion results in prolonged knee extension after heelstrike.
- If it feels too long:
  - Fitting is too loose.
  - Knee is extended.
  - Foot is plantar flexed.
- **Long prosthesis:** Circumduction gait, vaulting, abducted gait, trunk bending.
- **Uneven ground amputee:** Articulated dynamic response foot preferred by some.
- **Prosthetic stability** is improved with force line posterior to hip and anterior to knee.
- **Trauma:**
  - Amputation for some grade IIIB and grade IIIC open fractures and > 6-hour warm ischemia time, and/or posterior tibial nerve laceration.
  - Better function and lower cost than limb salvage.
  - Greater infection and longer return to work if limb salvage is attempted.
- **Tumor:**
  - Limb salvage patients become more sedentary.
  - Amputees are more active.
  - Knee fusion patients have reduced activity.
- **Pediatrics:**
  - Fit prosthesis for upper extremity at 4–6 months (sitting) and 2–3 years for active device.
  - Fit prosthesis for lower extremity at 8–12 months (when the child would normally start walking).

Miscellaneous

- **Knee disarticulation:** Attach cruciates to patellar tendon.
- **Joint disarticulations:** Advantage is direct load-bearing limbs.
- **Bilateral amputees:** Set wheelchair axle more posterior so patient does not fall backward.
- **Phantom limb pain:** Occurs in 60%–70% of adult lower extremity amputations.
- **Chronic swelling** can lead to verrucous hyperplasia.

▶ ORTHOTICS

Charcot joints have much more destruction than is clinically evident.

- **Orthotics** are not choices for fixed deformities.
- **Hallux rigidus:** Combine a bar with a rocker bottom.
- **Extra depth shoes** for diabetics.
- **Drop foot:** Flexible Ankle-Foot Orthosis (**AFO**); fixed rigid deformity cannot be corrected with AFO.
- **L2 paraplegia:** Knee-Ankle-Foot Orthosis (**KAFO**); body weight line posterior to hip and anterior to knee in order for patient to be able to stand.

Charcot Joints

- Charcot neuropathy: Bisphosphonate treatment offered.
- **Treatment:**
  - Prolonged non–weight bearing or modified weight bearing.
  - Total contact casts.

Miscellaneous Medically Related Issues

- **Tobacco** increases the relative risk for hip and distal radius fracture.
- **Reflex sympathetic dystrophy (RSD), sympathetic maintained pain (SMP), chronic regional pain syndrome (CRPS).**
  - **Diagnosis:** Nonanatomic pain, swelling, trophic changes, hypersensitivity, osteopenia.
  - **Treatment:**
    - Early sympathetic block combined with gentle, pain-free active-assist ROM and alpha-blocking agents.
    - Phenoxybenzamine treats RSD by *blocking alpha receptors* (thus vasodilating small arterioles).

Tobacco increases the relative risk for hip and radius fractures while weakening the healing fracture.

▶ ABUSE

- **Fractures:** Corner fracture; bucket-handle; posterior rib; multiple wide skull, scapular, or sternal fractures.
- Abused children are most commonly in the *infant to 4-year-old group* (50% < 1 year old, 78% < 3 years old).
- Consider domestic abuse when the injury is inconsistent with the offered explanation.
- Orthopaedists are obligated to report any suspected cases of abuse.

▶ MISCELLANEOUS DISEASES

Caffey Disease (Infantile Cortical Hyperostosis)

- Benign self-limiting disease.
- Soft tissue swelling and bony thickening (mandible and long bones).
- Febrile illness.
- Tenderness over bones.
- **Treatment:** Observation and nonsteroidal anti-inflammatory drugs (NSAIDs).

Atlantoaxial Rotatory Subluxation

- Most common after upper respiratory infection; head tilted and rotated to other side.
- If nontraumatic and persists for 7 days, use a chin halter traction device for 4 weeks.
- Dynamic CT to confirm diagnosis.

Emotional Hyperhidrosis (Sweaty Feet)

- Autosomal dominant.
- Eccrine glands.
- **Treatment:** Frequent sock changes and powders and washes. If this fails, try *20% aluminum chloride in anhydrous ethanol* (apply qhs in vapor-impermeable material).

▶ MISCELLANEOUS MEDICATIONS

- **Percocet** for 2 weeks could show *elevated* liver function tests.
- **NSAIDs** inhibit *cyclooxygenase*.
- Chemo medications have several limiting side effects (see Table 11-3).

TABLE 11-3. Chemotherapy and Limiting Side Effects

Chemo Medication	Limiting Side Effect
Doxorubicin (Adriamycin)	Cardiac toxicity
Vincristine	Neurotoxicity
Bleomycin	Pulmonary fibrosis
Cisplatin	Nephrotoxicity

- **Anabolic steroids** are more effective with healing than corticosteroids. In muscle contusion injury models, corticosteroids appeared good early but results worsened with time.
- **Methotrexate:** Halt for 2 weeks around surgery due to concerns of wound healing, fluid balance, and glomerular filtration rate changes.
- **Embrel** (etanercept):
  - Stop preoperatively due to wound healing issues.
  - Some advise stopping for 3 months prior, but patient disease progression often prohibits this approach.
  - Mechanism of action: Solute binds to tumor necrosis factor-alpha (TNF-α).
- **Infliximab** (Remicade): Monoclonal antibody that binds to TNF-α.
- **Leflunomide** inhibits pyrimidine synthesis.
- **Adalimumab** (Humira): Monoclonal antibody for TNF-α.
- **Anakinra** (Kineret): Interleukin-1 recombinant soluble human receptor protein.

Embrel is a soluble binder of TNF-α.

▶ PERIOPERATIVE PROBLEMS

Transfusion

- Blood transfusion 1:500,000 risk—*Yersinia enterocolitica* (gram-negative).
- Platelet transfusion 1:12,000 risk—*Staphylococcus* (gram-positive).

Deep Venous Thrombosis (DVT)

Virchow's triad includes stasis, hypercoagulable state, and intimal injury.

- **Virchow's triad:** Stasis, hypercoagulable state, intimal injury.
- Venography, US, CT.
- DVT in pelvic trauma: Consider placing vena caval filter.
- Pulmonary embolism: Tachypnea, 90%; tachycardia, 60%; electrocardiographic changes, 25%.

Pulmonary

- **Acute respiratory distress syndrome (ARDS):** 50% mortality despite critical care.
- **Fat emboli syndrome:**
  - Early fracture stabilization lowers incidence.
  - Occurs earlier than pulmonary embolism.
  - Fatal in 10%–15%.
- **Treatment:** Supportive; high levels of positive end-expiratory pressure.

Cardiac

- Risk factors:
  - Myocardial infarction or pulmonary edema within 6 months.
  - Unstable angina or angina with minimal exertion.
  - Aortic stenosis.

Nutrition

- **Nutritional status:** Arm circumference is the best indicator.
- Bacterial translocation results from intestinal mucosal atrophy.
- **Ogilvie syndrome:** Ileus often after total joint replacement.

▶ PRACTICE PRINCIPLES

Definitions

- **Impairment:** The loss of a physiologic or anatomic structure or function (not necessarily disabled); measurable difference in function (objective).
- **Disability:** Inability to perform an act (because of the impairment) that a normal human can.
- **Handicap:** Documented impairment that limits activity.
- **Disease:** A pathologic condition of a body part.
- **Illness:** The total effect of an injury or disease on the entire individual.
- **Negligence:** Failure to exercise degree of care a "reasonable" physician should apply.
  - Includes residents (same standard of care as the attendings).
  - First patient encounter initiates patient-doctor relationship.

Malpractice

- Malpractice coverage:
  - **Occurrence:** Covers all claims that occurred during the period of the policy.
  - **Claims made:** Covers claims only during time of coverage.
  - **Tail:** Covers those acts for a time period after.
- An orthopaedic surgeon is most likely to be sued due to an unexpected result of treatment. Attending physicians' responsibility for residents is "vicarious liability."
- Copies of a patient's medical record must be made available at a reasonable cost, even if they have not paid their bill.

▶ STATISTICS

- Prevalence:
  - Total number of occurrences of a condition in a population.
  - Total number of affected individuals at a single point in time/total number at risk.
- Incidence:
  - Those conditions diagnosed or identified in a population.
  - Number of new cases in a specified time period.
- Accuracy:
  - Closeness of multiple variates to the true value.
  - Ability to correctly identify data collected.

- **Precision:**
  - Closeness of repeated measurements.
  - The ability to repeat measurements (same data point).
- **Validity:** Degree to which the measurement represents a true value.
- **Reliability:** Ability of researchers to repeat the same measurement.
  - Interobserver
  - Intraobserver
- **Bias:** Flaw of impartiality.
  - **Selection bias:** Error in study population.
  - **Observation bias:** Error in recall.
  - Reduce bias with masking and standardization.

Tests with higher sensitivities are better screening tests.

- **Sensitivity:**
  - Positive results/all with condition.
  - Good *screening test* marker.
- **Specificity:** Negative results/all without condition.
- **Positive predictive value:** All positive results with the condition/all positive test results.
- **Negative predictive value:** All negative results without condition/all negative tests results.
- **Research hypothesis:** Scientist's theory is true.
- **Null hypothesis:** Experimental treatment has no (null) effect; that which the scientist hopes to statistically reject.
- **Type I error (alpha error):**
  - False-positive; rejecting a true null hypothesis.
  - Protect against this via significance levels.
  - Showing a significant difference when there is *not* one.
- **Significance level:** An indication of the probability of making a type I error—failing to find an effect when there is in fact one to find.
- **Type II error (beta error):**
  - False-negative; accepting the false hypothesis as true.
  - Incorrectly concluding that there is no difference when there is a difference.
  - Protect against this with power.
- **Power:**
  - Likelihood that a statistically significant difference would be found between two groups if a difference truly exists.
  - Probability that one will reject the null hypothesis when the alternative hypothesis is true.
  - Directly influenced by the *number of subjects*.

Power of a study is dependent on the number of subjects tested and the frequency of the disease.

- The most important parameter needed when determining *sample size* for a research study.
- ***p* value:**
  - Probability that the null hypothesis is false.
  - Magnitude of chance that the conclusion was reached incorrectly.
- ***p* value** of 5% (0.05) means that the probability that the difference noted between two study groups were due to chance alone is 5%.
- **Power analysis:**
  - Determines sample size; key variable is the expected difference.
  - Rule of 3: If the condition has an occurrence of 1:10, then 10 × 3 patients needed for a statistically reliable study.
- **Mean:** Average number.
- **Median:** Middle number.
- **Mode:** Most frequent.
- **Variance:** Measure of the spread of the data.
- **Standard deviation:** Square root of the variance.
- **Confidence interval:** Within two standard deviations of the mean (95%).

Types of Tests

- **Regression analysis:** Determines the relationship between independent and dependent variables.
- **One-sample t-test:** Compares the sample mean to a known mean.
- **Two-sample t-test:** Compares the mean values between independent groups.
- **ANOVA** (analysis of variance):
  - T-test extension to more than two variables.
  - Determines whether a significant difference exists between means of more than two independent variables with normal distribution.
- **Chi-square test:** Used to find p value; requires discrete, dichotomous, independent variables tested (positive or negative):
  - Sample size > 50 in all groups.
  - Occurrence > 5–10 per group.
- **Fisher's exact test:** Used to find p value; modification of the chi-square test; corrects for smaller numbers of observation.
- **Discrete data:** Use p value, chi-square test, Fisher's exact test.
- **Continuous data:** Height and weight—use Student's t-test and ANOVA.
  - One-sample t-test: Compares the sample mean with the standard variable.
  - Independent two-sample t-test: Compares sample mean values between two independent groups.
  - Paired t-test: Allows comparison of samples, not independent.
  - ANOVA: Used for more than two independent groups.

Types of Studies

- Descriptive:
  - **Case reports:** Presentation of one patient; no controls and no frequency data.
  - **Case series:** Presentation of a number of patients; no controls and no frequency data.
  - **Correlation studies:** Larger sample sizes that identify associations between disease and another variable; defines associations.
  - **Cross-sectional studies:** Study a group at one point in time; snapshot in time.
- Analytic:
  - **Case control:** Subjects are selected for having a key item and then compared; retrospective.
  - **Prospective cohort:** Follow disease-free group over time to see what happens (studies exposure).
  - **Meta-analysis:** Combines several studies for greater power.
  - **Outcomes research:** Patient's perspective.
  - **Intervention studies:** Clinical trial; prospective, random, blind.

Levels of Evidence (Per *Journal of Bone and Joint Surgery*)

- **Level 1:** Well-designed randomized clinical trial (prospective, controlled).
- **Level 2:** Prospective cohort (prospective, uncontrolled).
- **Level 3:** Case control study (retrospective, controlled).
- **Level 4:** Case series (retrospective, uncontrolled).
- **Level 5:** Expert opinion.

The most common nosocomial surgical infection is urinary tract infection.

- **Urinary tract infection** is the most common nosocomial surgical infection (6%–8%).
- **Statute of limitations:** 18 years old (for minors) or 2 years (for adults) after incident.
- **Worker's compensation** patients tend to have worse self-assessed function and health status than others.
- Complete orthopaedic history and physical best identifies musculoskeletal problems during pre-participation exams.
- Encourage calcium intake in women after puberty.

Malignant Hyperthermia

- Autosomal dominant.
- Triggered by halothane and succinylcholine.
- Impaired function of the sarcoplasmic reticulum and calcium homeostasis.
- Associated with Duchenne's muscular dystrophy, arthrogryposis, and osteogenesis imperfecta.
- **Treatment:** Dantrolene.

INDEX

Note: Page numbers referencing figures are italicized and followed by an "*f*." Page numbers referencing tables are italicized and followed by a "*t*."

1-α hydroxylase, 3
30/60/90 rule, 179
4 Cs of viability, 36
5 Ps of compartment syndrome, 36

A

A2 pulley, 22
AAI (atlantoaxial instability), 200, 222
ABC (aneurysmal bone cyst), 177
ABCs of general trauma, 34
abductor lurch, 87, 237
abductor pollicis brevis (APB), 128
above-knee amputation (AKA), 237
abrasive wear type, 15
abuse, child, 241
AC (acromioclavicular) injuries, 41, 111, *112f*
accessory navicular, 163, 208
accuracy, defined, 243
ACDF (anterior cervical decompression and fusion) complications, 221
acetabular fracture, 51–52
acetabular periprosthetic fracture, 82
acetabulum, 78
acetublar screw anterior superior quadrant, 80
Achilles tendon
  injuries, 158
  rupture, 66–67
  tendinitis, 158
achondroplasia, 9, 209
ACL (anterior cruciate ligament), 28, 116–118
acromioclavicular (AC) injuries, 41, 111, 112*f*
acrosyndactyly, 141
active myocarditis, 124
acute peroneal tendon dislocation, 67, 122
acute respiratory distress syndrome (ARDS), 242
adalimumab, 242
adamantinoma, 176–177
adductor myodesis, 237
adenocarcinoma metastases, 227
adequate resuscitation, 34
adhesive capsulitis, 108–109
adhesive wear type, 15
adolescent bunions, 208
adolescent idiopathic scoliosis, 198–199
adult spine deformity, 228–229
AIN (anterior interosseous nerve), 22, 45, 137
AKA (above-knee amputation), 237
Albers-Schönberg disease, 3
alkaptonuria, 9
allograft
  fracture through, *83f*
  proximal humerus with radical resection reconstructed with, *189f*
  revision THA, 77
alpha error, 244
alveolar cell sarcoma, 183
amputations, 134–135, 237–240
anabolic steroids, 7, 242
anakinra, 242
analysis of variance (ANOVA), 245
analytic studies, 245
anatomy
  elbow, 113
  of general spine, 219
  hand, 128
  joint arthroplasty, 102–103
  shoulder, 107
aneurysmal bone cyst (ABC), 177
angiosarcoma, 182
ankle. *See also* foot and ankle
  arthroscopy, 153
  and foot amputation, 238
  fracture, 65–66
  fusion, 161
  osteochondral lesions of talus, 153
  snowboarder's injury, 153
  sprain, 152
  trauma, 164
ankle scope, 28
ankylosing spondylitis, 9, 39, 224
annulus fibrosis, 220
ANOVA (analysis of variance), 245
antalgic gait, 237
anterior approach
  arthrodesis, 80
  hip, 26
anterior cervical decompression and fusion (ACDF) complications, 221
anterior cord syndrome, 36, *219t*
anterior cruciate ligament (ACL), 28, 116–118
anterior glenohumeral dislocation, 42
anterior instability, 109–110
anterior interosseous nerve (AIN), 22, 45, 137
anterior SC joint dislocation, 40
anterior talofibular ligament (ATFL), 28, 152
anterior tibiotalar osteophytes, 122
anterolateral approach, 26
anteroposterior compression (APC) injury, 50
Antoni A neurilemmomas, 181
Antoni B neurilemmomas, 181
APB (abductor pollicis brevis), 128
APC (anteroposterior compression) injury, 50

Apert syndrome, 140
ARDS (acute respiratory distress syndrome), 242
arthritis
  foot and ankle, 160–161
  gout, 131
  juvenile rheumatoid, 131
  miscellaneous, 132
  overview, 131
  psoriatic arthritis, 131
  rheumatoid arthritis, 131
  thumb carpometacarpal joint, 131
arthrodesis, 79–80, 94–95, 99, 161
arthrography, 234
arthrogryposis, 140, 163, 196
arthroscopy, ankle, 153
articulated dynamic response feet, 239
Askin's tumor, 176
aspirin, 13
ATFL (anterior talofibular ligament), 28, 152
atlantoaxial instability (AAI), 200, 222
atlantoaxial rotatory subluxation, 241
auricular hematoma, 123
autocrine, 8
autonomic dysreflexia, 220, 236
autosomal dominant, 138–139
avascular necrosis (AVN)
  of lunate, 115
  overview, 85
  risk with femoral head/neck fractures, 214
axillary nerve, 9
axonotmesis, 8, 138

B

Baclofen, 197
Bankart lesion, 110, *111f*
Bartonella henselae, 12, 180
base deficit, 35
Basset's ligament, 152
Batson's venous plexus, 179
Baxter's nerve, 159
Becker's muscular dystrophy, 196
below-knee amputation (BKA), 237–240
bending rigidity, 101
benign fibrous hystiocytoma (BFH), 174
benign lesions, 174
benign schwannoma, 181
benign tumor staging, 184
Bennett's fracture, 146, 148
beta error, 244
BFH (benign fibrous hystiocytoma), 174
bias, 244
bicolumn distal humerus fracture, 113
bilateral amputees, 240
bilateral C-spine facet subluxation/dislocation, 39
bilateral pars, 223–224
bilateral TKA, 91
biologic fixation, hip replacement, 75
biomaterials, bone, 14
biomechanics, joint arthroplasty, 101
biopsies, orthopaedic tumor, 187
bisphosphonates, 175, 190
BKA (below-knee amputation), 237–240
bone
  defects, 77
  tumor-like conditions of, 177–180
  tumors, 175–177, 188
bone grafts, 5, 77. *See also* allograft
bone scans, 234
bone-producing lesions, 170–171
Botox, 197
Boutonniere deformity, 128, 134
Bowen disease, 145, 184
Bowler's thumb, 138
brachial plexus injuries, 40, 201–202
brittle, 14
Broden's x-ray views, 152
Brodie's abscess, 180
Brown-Séquard syndrome, 36, *219t*
bucket handle meniscal tear, *120f*
Buerger disease, 132
bunionette, 156
bunions, 208
Burner/Stinger injury, 123
burst fracture, 40, 225

C

C1 fracture, 223
C1–2 instability, 37
C2 Hangman's fracture, 37
CA (coracoacromial) ligament, 19
café au lait spots, 177
Caffey disease, 241
calcaneal apophysitis, 122
calcaneal-navicular ligament, 29
calcaneovalgus foot, 208
calcaneus fracture, 68–69
calcaneus trauma, 164
calcaneus x-ray views, 152
calcific tendonitis, 109, *110f*
calcifying aponeurotic fibroma, 180
calcinosis, 144, 183
calcitonin, 3
calcium pyrophosphate deposition (CPPD), 9, 131, 161
camptodactyly, 140
canale x-ray views, 152
cancellous bone graft, 5
cardiac perioperative problems, 243
carotid sheath, 24, 222
carpal boss, 144, 184
carpal instability, combined (CIC), 130
carpal instability, dissociative (CID), 130
carpal instability, nondissociative (CIND), 130
carpal tunnel syndrome (CTS), 136
carpometacarpal (CMC) joint, 131
cartilage, 102
cartilage-producing lesions, 121, 171–173
case control, 245
case reports, 245
case series, 245
cat scratch disease, 12, 180
cauda equina syndrome, 219
cavus, 160
cavus foot, 208
cement fixation, hip replacement, 75–76
cemented TKA, 89
cementless TKA, 92
central cord syndrome, 36, *219t*
cephalic vein, 21
cephalomedullary hip screw, 54
ceramics, THA wear, 84
cerebral palsy (CP)
  great toe, 155
  hand tendon transfers, 141
  pediatrics, 197
cerebrovascular accident (CVA)
  overview, 160
  rehabilitation, 235

cervical myelopathy, 222–223
cervical neuropraxia, 123
cervical radiculopathies, *221t*
cervical spine, 221–225
cervical trauma, 37
Chance fractures, 40, 225
Charcot joints, 240
Charcot restraining orthotic walker (CROW), 165
Charcot-Marie-Tooth (CMT) disease, 159–160, 197
chemotherapy
  limiting side effects, *242t*
  orthopaedic tumors, 188–189
CHF (congestive heart failure), 91
Chiari osteotomy, 79
child abuse, 241
Chi-square test, 245
chondroblastoma, 172
chondrocalcinosis, 28
chondrodysplasia punctate, 210
chondromyxoid fibroma, 172
chondrosarcoma, 144–145, 172–173, 184
Chopart amputation, 163
chordoma, 174, 228
chromosomal translocations, 176, 191
chronic Achilles rupture, 158
chronic infections, 180
chronic paronychia, 142
chronic posterior glenohumeral dislocation, 110
chronic recurrent multifocal osteomyelitis (CRMO), 180
CIC (carpal instability, combined), 130
CID (carpal instability, dissociative), 130
CIND (carpal instability, nondissociative), 130
clavicle fractures, 41
claw toes, 156
clear cell chondrosarcoma, 173
clear cell sarcoma, 183
cleft hand, 203, *204f*
cleidocranial dysplasia, 211
Cleland's ligaments, 22
clinodactyly, 141
clubfoot, 207–208
CMC (carpometacarpal) joint, 131
CMT (Charcot-Marie-Tooth) disease, 159–160, 197
coax saltans, 116
Coleman block test, 160
collagen types, 124
common peroneal nerve palsy, 159
commotio cordis, 124
compartment syndrome
  of foot, 71
  overview, 36
  with tibial shaft fracture, 64
  vascular hand lesions, 133
complete spinal cord injury, 219
component fixation, 101
component positioning, TKA, 89–90
compression neuropathies, 136
computed tomography (CT), 234
concentric muscle contraction, 234
concussion, 123
confidence interval, 244
congenital coxa vara, 204
congenital dislocation of radial head, 202
congenital hand disorders, 138–141
congenital knee dislocation, 206
congenital pseudoarthrosis
  of clavicle, 202
  of tibia, 207
congenital radial head dislocation, 114
congenital short femur, 205
congenital spine deformity, 199
congenital vertical talus, 163, 208
congestive heart failure (CHF), 91
constant-friction knee, 239
Continuous data test, 245
conus medullaris syndrome, *219t*
coracoacromial (CA) ligament, 19
corner fractures, 215
coronoid fracture, 46
correlation studies, 245
cortical bone fracture, *83f*
cortical bone graft, 5
corticosteroids, 3
coumadin, 13
CP. *See* cerebral palsy
CPPD (calcium pyrophosphate deposition), 9, 131, 161
CR (cruciate-retaining) systems, 89
"creeping substitution", 6
CREST, 133
cricothyrotomy, 36
CRMO (chronic recurrent multifocal osteomyelitis), 180
cross-finger flap, 135
cross-sectional studies, 245
crouched gait, 197
CROW (Charcot restraining orthotic walker), 165
cruciate-retaining (CR) systems, 89
cruciate-sacrificing (PS) systems, 89
cruciform ligament, 24
crystalloid isotonic solutions, 34
C-spine fusion, 225
CT (computed tomography), 234
CTS (carpal tunnel syndrome), 136
cubital tunnel syndrome, 113, 137
cuboid fracture, 69
curly toes, 209
CVA. *See* cerebrovascular accident

D

dancer's fracture, 123
Danis-Weber ankle fracture classification, 65
DDH (developmental dysplasia of hip), 76–77, 203–204
dedifferentiated chondrosarcoma, 173
deep external pudendal artery, 26
deep venous thrombosis (DVT)
  arthrodesis, 80
  perioperative problems, 242
degenerative joint disease (DJD), 52
degenerative spondylolisthesis, 228
delayed spine infection after fusion, 201
deltoid ligament, 152
Denis sacral fracture classification, 50–51
dermatofibrosarcoma protuberans (DFSP), 180
dermatome highlights, 225
descriptive studies, 245
desmoid tumors, 180
desmoplastic fibroma, 173
developmental dysplasia of hip (DDH), 76–77, 203–204
DEXA (dual-energy x-ray absorptiometry), 234
DFSP (dermatofibrosarcoma protuberans), 180
diabetes, 238
diabetic foot, 162–163
diagnostic tumor continuum, 185
dial or spherical osteotomy, 79
diaphyseal dysplasia, 212

diastrophic dysplasia, 163, 211
digit replant, 134
direct lateral approach, 27
disability, defined, 243
discoid lateral meniscus, 207
discrete data test, 245
disease, defined, 243
diskitis, 201
dislocation
  elbow, 113
  in THA, 81–82
distal biceps rupture, 113, *114f*
distal bone growth, *213t*
distal femur fractures, 58–59
distal humerus fracture, 45
distal radius fracture, 48–49
distraction osteogenesis, 6
DJD (degenerative joint disease), posttraumatic, 52
dorsal dislocation of proximal interphalangeal, 145
dorsal ligaments, 130
dorsal lip avulsions, 69
dorsal MCP dislocation, 146
dorsal osteophytes, *154f*
dorsal wrist pain, 129–130
double crush phenomenon, 136
Down syndrome, 156, 212
dual-energy x-ray absorptiometry (DEXA), 234
Duchenne's muscular dystrophy
  equinovarus foot, 163
  overview, 196
ductile, defined, 14
duplication, hand disorders, 139
Dupuytren disease, 143–144
dural ectasia, 220
dural tear, 226
DVT. *See* deep venous thrombosis
dynamic stabilizers, 17
dysostosis, 211
dysplasias, 209–212

E

eccentric muscle contraction, 234
ectrodactyly, 203
ECU (extensor carpi ulnaris) subluxation, 129
Ehlers-Danlos syndrome, 200
eikenella corrodens, 142
elastic limit, 14
elastic region, 14
elastofibroma dorsi, 173
elbow, 46, 113–114, 147
electromyography/nerve conduction velocity (EMG/NCV), 136
embrel, 242
emotional hyperhidrosis, 241
enchondroma, 144, 171–172, 184
endurance limit, 14
endurance training, 235
energy expenditure, amputees, 238
enostosis, 170
eosinophilic granuloma, 177
epidermal inclusion cyst, 145, 183
epiphyseal tumors, 185
epithelioid sarcoma, 144–145, 183, 184
equinovalgus, 198
equinovarus, 198
Erb-Duchenne paralysis, 23
Essex-Lopresti radial head fracture, 46
Essex-Lopresti tongue-type fracture, 69
estrogen, 3
Ewing's sarcoma, 176
excursion 3-5-7 rule, 141
extended trochanteric osteotomy, 78
extensor carpi ulnaris (ECU) subluxation, 129
extensor tendons, 133
extra-abdominal desmoid, 180
extruded disk herniations, 226

F

fabella, 28
FABER test, 220
fascioscapulohumeral muscular dystrophy, 196
fast-twitch type II muscle fibers, 7
fat emboli syndrome, 35, 103, 242
fatigue failure, 14
fatigue wear type, 15
fatty tissue lesions, 181
FCU (flexor carpi ulnaris) tendinitis, 129
FD (fibrous dysplasia), 177–178
felon treatment, 142
femoral cut, TKA, 88
femoral head blood supply, *27t*
femoral head fracture, 53
femoral neck nonunion, 214
femoral neck stress fracture, 54, 116, *117f*
femoral nerve, 26
femoral periprosthetic fracture, 82
femoral shaft fractures, 56–58, 214
femoral stretch test, 220
femoral torsion, 205
femoral-acetabular impingement, 115
fibrinolytic system, 13
fibrochondrocyte, 120
fibromatosis, 180
fibrosarcoma
  of bone, 173
  recurrence rate, 192
fibrous cortical defect, 173
fibrous dysplasia (FD), 177–178
fibrous lesions of bone, 173
fibular hemimelia, 207
fight bites, 142
first-generation cementing technique, *75t*
Fisher's exact test, 245
flaps, 135
flatfoot gait, 237
flexed thumb, 140
flexible flatfoot, 208
flexion–distraction injury, 39–40
flexor carpi ulnaris (FCU) tendinitis, 129
flexor pollicis brevis (FPB), 128
flexor tendons, 133
floating elbow, 113
floating facet, 39
floating shoulder, 41
fluid replenishment, 123
fluid resuscitation, 34
fluid-control knee, 239
fluoroquinolones, 158
foot and ankle
  acute peroneal tendon dislocation, 122
  amputation, 163, 238
  anatomy, 151–152
  arthritic disease, 160–161
  congenital foot topics, 163
  foot nerve topics, 158–159
  gait, prosthetics, and rehabilitation, 165
  great toe, 153–158
  heel pain, 153
  infection, 162–163
  injuries, 152–153
  key facts, 122–123
  lateral process of talus fracture, 122
  navicular stress fracture, 122
  neurologic disorders, 159–160

syndesmosis injury, 122
talar osteochondral lesion, 122
trauma, 163–164
tumors, 163
Turf Toe, 122
Windlass mechanism, 121–122
FPB (flexor pollicis brevis), 128
FREAS, 138
free fibula transfer, 85
free nerve endings, *9t*
Freiberg's infraction, 157, 209
Friedreich's ataxia, 196
Froment sign, 22
frostbite, 162
frozen shoulder, 108–109, 237
full-thickness skin grafts, 135
fusions
ankle, 161
carpal instability, 130
C-spine, 225
delayed spine infection after, 201

G

gait, 165, 236–237
Galeazzi fracture, 47
Gallium scan, 234
gamekeeper's thumb, 115, 146
gamma irradiation, 15, 101
ganglion, 144, 182, 183
gas gangrene, 11
Gaucher disease, 9, 212
general spine, 219–221
general trauma, 34–36
genetic keys, *10t–11t*
giant cell arteritis, 132
giant cell tumor
of bone, 175–176
of tendon sheath, 144, 183
glenohumeral dislocations, 42–43
glenoid arthritis, 99
glomus tumor, 144, 183
Gorham disease, 174
gout, 9, 131, 161
Grayson's ligaments, 22
great toe, 153–158
greater occipital nerve, 24
groin flap, 135
gunshot wounds
femur, 57
spinal cord, 220
Gustillo open fracture classification, *35t*

H

hallux rigidus, 153
hallux valgus (HV), 153–156
hallux varus, 156
halo complication, 224
hamate hook fracture, 129
hammer toes, 156
hamstring injury, 124
hand
anatomy, 128
arthritis, 131–132
congenital disorders, 138–141
Dupuytren disease, 143–144
fingertip amputation, 134–135
flaps, 135
gamekeeper's thumb, 115
infections, 142–143
key facts, 115
Kienböck disease, 115
mallet finger, 114–115
nerves, 135–138
overview, 125–127
replantation, 134
skin grafts, 135
tendon transfers, 141–142
tendons, 133–134
thumb, 135
trauma, 145–147
tumors, 144–145, 183–184
vascular hand lesions, 132–133
wrist, 128–130
handicap, defined, 243
Hand-Schüller-Christian disease, 177
Hangman's fracture, 223–224
Hardinge approach, 27, 80
Hawkins sign, 164
head–neck ratio, 81
heat stroke, 124
heel pain, 153
heel spurs, 28
hemangioendothelioma, 174
hemangioma, 174, 182
hematology, 102
hematopoietic bone lesions, 174–175
hemiplegia, 237
hemorrhagic shock, *34t*
Henry approach to elbow, 21
heparin, 13
hereditary motor sensory neuropathy (HMSN), 159–160
herniated nucleus pulposus (HNP), 221, 226
herpetic whitlow, 143
herringbone pattern, 173
heterotopic ossification (HO), 100–101, 113
high tibial osteotomy (HTO), 93
high ulnar nerve palsy, 142
high-pressure injection injuries, 148
hip
arthroscopy, 86
dislocation, 52–53
loosening, 85
osteotomy, 79
overview, 115–116
hip fusion takedown, 79
histiocytic lesions of bone, 174
histiocytosis, 177
HMSN (hereditary motor sensory neuropathy), 159–160
HNP (herniated nucleus pulposus), 221, 226
HO (heterotopic ossification), 100–101, 113
homocystinuria, 9, 212
hook of hamate fracture, 115
Horner syndrome, 23, 138
HTO (high tibial osteotomy), 93
humeral head, 17
humeral shaft fracture, 44–45
humerus fracture, 214
HV (hallux valgus), 153–156
hypercalcemia, 178
hypercoagulable state, 13
hypertrophic cardiomyopathy, 124
hypertrophic zone, 6
hypoparathyroidism, 4
hypophosphatemic rickets, 4
hypoplastic thumb, 140

I

idiopathic transient osteoporosis of the hip (ITOH), *4f*, 87
IGF, 2
IGHL (inferior glenohumeral ligament), 107
iliotibial (IT) band friction syndrome, 121
illness, defined, 243
IM (intramedullary) nailing, 44, 56, 59, 63
imaging, 233–234
immunostains, 188
impaction grafting, 79
impairment, defined, 243

incidence, defined, 243
incomplete cord syndromes, 36
incomplete spinal cord injury, 37, *219t*
Indium scan, 234
infantile blount disease, 207
infantile cortical hyperostosis, 241
infantile idiopathic scoliosis, 199
infection
  arthrodesis, 80
  foot and ankle, 162–163
  hand, 143
  joint arthroplasty, 99–100
  lumbar spine, 227
  pediatric orthopaedic, 200–201
  tumor-like conditions of bone, 180
inferior glenohumeral dislocation, 42
inferior glenohumeral ligament (IGHL), 107
infliximab, 242
in-growth technology, 75
inserts, 165
intercondylar eminence fractures, 214–215
internal iliac artery, 26
interosseous (IO) ligament, 128
interphalangeal joint of great toe fusion, 161
intersection syndrome, 128
intertrochanteric hip fracture, 54–55
intervention studies, 245
intractable plantar keratosis (IPK), 157
intramedullary (IM) nailing, 44, 56, 59, 63
intramedullary chondrosarcoma, 172
intrinsic minus hand, 128
intrinsic plus hand, 128
involucrum, 180
IO (interosseous) ligament, 128
IPK (intractable plantar keratosis), 157
ipsilateral C-spine lamina and pedicle fracture, 39
ipsilateral femoral neck fracture, 57
isokinetic muscle, 7, 234
isometric muscle, 7, 234
isotonic muscle, 7, 234
isthmic spondylolisthesis, 228
IT (iliotibial) band friction syndrome, 121
ITOH (idiopathic transient osteoporosis of the hip), *4f*, 87

J

Jaffe-Campanacci syndrome, 173
joint arthroplasty
  anatomy, 102–103
  associations, 102
  biomechanics, 101
  cartilage, 102
  component fixation, 101
  definitions, 102
  fat emboli syndrome, 103
  hematology, 102
  heterotopic ossification, 100–101
  infection, 99–100
  shoulder, 96–99
  total hip replacement
    acetabular periprosthetic fracture, 82
    arthrodesis, 79–80
    avascular necrosis, 85
    biologic fixation, 75
    cement fixation, 75–76
    developmental dysplasia of hip, 76–77
    dislocation in THA, 81–82
    femoral periprosthetic fracture, 82
    hip arthroscopy, 86
    hip loosening, 85
    hip/pelvis osteotomy, 79
    osteolysis, 82–83
    revision THA, 77–79
    search for ideal bearing surface, 84–85
    stress shielding, 76
    techniques, 76
    THA wear, 83–84
  total knee arthroplasty
    arthrodesis, 94–95
    bilateral, 91
    component positioning, 89–90
    knee osteotomy, 93–94
    ligament balancing, 96
    patellofemoral articulation, 91
    periprosthetic fracture, 92–93
    prosthetic design, 88–89
    revision, 91–92
    surgical technique, 88
    unicompartmental knee arthroplasty, 91
    valgus knee, 91
    varus knee, 91
    wear, 90
  wear, 101
joint disarticulations, 240
Jones fracture, 70, 123
Journal of Bone and Joint Surgery, 245
JRA (juvenile rheumatoid arthritis), 9, 131
jumper's knee, 121
juvenile hallux valgus, 155
juvenile idiopathic scoliosis, 199
juvenile rheumatoid arthritis (JRA), 9, 131
juvenile Tillaux fracture, 164

K

Kernig's sign, 220
Kienböck disease, 115, 129
Kirner's deformity, 141
Klippel-Feil syndrome, 200
Klumpke's paralysis, 23
knee. *See also* total knee arthroplasty
  anterior cruciate ligament, 28, 116–118
  cartilage lesions, 121
  disarticulation, 240
  dislocation, 59–60
  iliotibial band friction syndrome, 121
  key facts, 121
  lateral, 28
  lateral collateral ligament, 119
  ligament healing, 119
  medial, 27
  meniscus, 119–120
  patella, 121
  popliteus, 28
  posterior cruciate ligament, 28, 118–119
  posterolateral corner, 119
Kneist syndrome, 210
Kocher approach to elbow, 21
Köhler disease, 208

L

L5 nerve root compression, 225
Langerhans' cell histiocytosis, 177
Larsen syndrome, 196
Lasègue's sign, 220

lateral collateral ligament (LCL), 119
lateral compression (LC) injury, 50
lateral epicondylitis, 113
lateral inferior geniculate artery, 28
lateral knee, 28
lateral process of talus fracture, 122
lateral proximal interphalangeal dislocation, 146
lateral subtalar dislocation, 164
lateral tibiotalar dislocation, 164
Lauge-Hansen ankle fracture classification, 65
LC (lateral compression) injury, 50
LCL (lateral collateral ligament), 119
LCP (Legg-Calvé-Perthes) disease, 205
leflunomide, 242
leg length discrepancy (LLD), 206, 237
Legg-Calvé-Perthes (LCP) disease, 205
leiomyosarcoma, 182
lesser toe deformity, 156–157
Letournel acetabular fracture classification, *51t*
Letterer-Siwe disease, 177
levels of evidence, 245
ligament balancing, 96, *97t*
ligament healing, 119
ligament of Landsmeer, 128
ligament of Struthers, 21
ligament of Testut, 130
linear region, 14
lipoblastoma, 181
lipoma, 181
liposarcoma, 181, 192
lisfranc ligament
  fracture–dislocation, 70
  injuries, 164
  overview, 151–152
Lister's tubercle, 129
Little Leaguer's shoulder, 43
LLD (leg length discrepancy), 206, 237
LMWHs (low-molecular-weight heparins), 13
lobster claw hand, 203
loose cemented stem, 78
lovenox, 13
low back pain, 225
low ulnar nerve palsy, 142
lower extremities. *See also* pelvis and lower extremity trauma
  foot and ankle, 121–123
  hip, 115–116
  knee, 116–121
  motor exam, 236
  pediatric orthopaedics, 203–209
  spine and head injuries, 123–124
low-molecular-weight heparins (LMWHs), 13
LT (lunotriquetral) instability, 130
Ludloff approach, 27
lumbar radiculopathies, *25t*
lumbar spine, 225–227
lumbar stenosis, 226
lung metastases, 179
lunotriquetral (LT) instability, 130
"luxatio erecta", 42
Lyme disease, 12, 162
lymph node metastases, 182
lymphoma, 174

M

Madelung's deformity, 140
Madura foot, 162
Mafucci disease, 172
magnetic resonance imaging (MRI), 233
malignant fibrous histiocytoma (MFH), 174, 180
malignant hyperthermia, 246
malignant lesions, bone, 174
malignant peripheral nerve sheath tumor (MPNST), 182, 192
malignant tumor staging, 184–185
mallet finger, 114–115, 145
mallet toe, 157
malpractice, 243
mangled extremity severity score (MESS), 36
Mannerfelt lesion, 131
mantle defects, 75
Marfan syndrome, 9, 212
MC FIE, 187
McCune-Albright syndrome, 178
MCL (medial collateral ligament), 22
MCP (metacarpophalangeal) hyperextension dislocations, 146
MDOS (multiple organ dysfunction syndrome), 34
mean, defined, 244
MED (multiple epiphyseal dysplasia), 210
medial antebrachial cutaneous nerve, 21
medial approach, 27
medial collateral ligament (MCL), 22
medial femoral circumflex artery, 26
medial knee, 27
medial patellofemoral ligament, 61
medial plantar nerve entrapment, 159
medial subtalar dislocation, 164
medial tibial stress syndrome, 95
medial tibiotalar dislocation, 164
median, defined, 244
median nerve
  arm/forearm, 21–22
  compression, 136–137
medications, 241–242
Meissner corpuscles, *8t*, 135
melanoma, 145, 184
meniscus, 28, 119–120
Merkel cells, *9t*, 135
mesenchymal chondrosarcoma, 173
MESS (mangled extremity severity score), 36
meta-analysis, 245
metacarpal fractures, 146, *147f*
metacarpophalangeal (MCP) hyperextension dislocations, 146
metal-on-metal postoperative radiographs, *86f*
metaphyseal chondrodysplasia, 211
metaphyseal fibrous defect, 173
metaphyseal osteomyelitis, 11
metaphysis, 6
metastatic bone disease, 178–179
metastatic malignancy, 170
metatarsal fractures, 70
metatarsal trauma, 164
metatarsophalangeal (MTP) joint dislocation, 71
metatarsophalangeal (MTP) synovitis, 157
metatarsus adductus, 208
methotrexate, 242
MFH (malignant fibrous histiocytoma), 174, 180
MHE (multiple hereditary exostosis), 172
middle glenohumeral ligament (MGHL), 107

midfoot deformity, 161
midwaist scaphoid fracture, *148f*
Milwaukee shoulder, 112
Mirel's tumor criteria, 179
Moberg flap, 135
modes, defined, 244
modified brostrom, 152
modulus of elasticity, 14
mononucleosis, 124
Monteggia fracture, 48, 114
Morquio syndrome, 211
Morton's neuroma, 158
MOT (myositis ossificans traumatica), 171
motor exam, 235–236
MPNST (malignant peripheral nerve sheath tumor), 182, 192
MRI (magnetic resonance imaging), 233
MTP. *See metatarsophalangeal entries*
mucopolysaccharidoses, 211, *211t*
mucous cysts, 132
multidrug-resistance gene, 171
multiple epiphyseal dysplasia (MED), 210
multiple hereditary exostosis (MHE), 172
multiple hereditary osteochondroma, 172
multiple lesions, orthopaedic tumors, 187
multiple myeloma, 175
multiple organ dysfunction syndrome (MDOS), 34
Mumford failure, 112
muscles
  contractions of, 234
  of foot, 151
  isokinetic, 7, 234
  isometric, 7, 234
  isotonic, 7, 234
  lesions of, 182
musculocutaneous nerve, 21
myasthenia gravis, 8
myelodysplasia, 198
myeloma, 170
myelomeningocele, 163
myoelectric prosthesis, 237
myofibroblast, 8
myositis ossificans traumatica (MOT), 171

N

nail patella syndrome, 206
nasotracheal intubation, 36
navicular fracture, 69, 122, 164
neck flexion, 222
necrotizing fasciitis, 143, 162
negative predictive value, 244
negligence, 243
nerves
  foot, 158–159
  hand, 135–138
  injuries, arthrodesis, 80
neural tissue lesions, 181–182
neurapraxia, 8, 24, 138
neurilemmoma, 144, 181, 183
neurofibroma, 181
neurofibromatisis, 228
neurofibromatosis (NF), 181, 200
neurofibrosarcoma, 181
neurogenic shock, 219
neurologic disorders, 159–160
neuroma, 157
neuromuscular foot, 198
neuromuscular hip dysplasia, 197–198
neuropathic joint, 8
neurotmesis, 8, 138
NF (neurofibromatosis), 181, 200
nicotine, 220
nightstick fracture, 47
nine foot compartments, 151
nodular fasciitis, 180
nonossifying fibroma, 173
normal disk aging, 219
NSAIDs (nonsteroidal anti-inflammatory drugs), 13
nucleus pulposus, 220
null hypothesis, 244
nutrition, 243

O

observation bias, 244
obturator nerve, *26t*
OCD (osteochondral defect), 121, 214
OCE (osteochondral exostosis), 171
ochronosis, 9
odontoid fractures, 37–38, *39f*, 215, 223
OFD (osteofibrous dysplasia), 178
Ogilvie syndrome, 243
olecranon fracture, 46, 214
Ollier disease, 172
oncogenes, 191
one-sample t-test, 245
on-growth technology, 75
onychocryptosis, 162
open femur fractures, 57
open fractures
  ankle, 66
  overview, 35
open pelvis fracture, 50
open reduction and internal fixation (ORIF), *47t*, 86
opposition transfers, 142
order of nerve recovery, 136
ORIF (open reduction and internal fixation), *47t*, 86
orthopaedic trauma. *See also* pelvis and lower extremity trauma; upper extremities
  brachial plexus injuries, 40
  general trauma, 34–36
  spinal cord/plexus injuries, 36–40
orthopaedic tumors
  benign tumor staging, 184
  biopsy, 187
  bisphosphonate therapy, 190
  bone tumors of unknown origin, 175–177
  bone-producing lesions, 170–171
  cartilage-producing lesions, 171–173
  chemotherapy, 188–189
  common chromosomal translocations, 191
  diagnostic tumor continuum, 185
  epiphyseal tumors, 185
  fatty tissue lesions, 181
  fibrous lesions of bone, 173
  hand, 183–184
  hematopoietic bone lesions, 174–175
  histiocytic lesions of bone, 174
  immunostains, 188
  lesion on both sides of joint, 186
  malignant tumor staging, 184–185
  MC FIE, 187
  multiple lesions, 187
  muscle lesions, 182
  neural tissue lesions, 181–182
  oncogenes, 191
  pediatric tumor, 185

prognostic factors, 185
radiation, 189–190
RANKL, 191
sacral lesions, 186
sarcomas of soft tissue, 183
soft tissue lesions, 180
with soft tissue mineralization, 185–186
surface lesions, 186
synovial disorders, 182–183
tibial lesions, 186
treatment, 190
tumor miscellaneous, 191–192
tumor resection, 188
tumor suppressor gene, 191
tumor workup, 187
tumor-like conditions of bone, 177–180
vascular lesions, 174, 182
orthoses, 165
orthotics, 240–241
OS (osteosarcoma), 170–171
Os peroneum, 67
OS trigonum syndrome, 151
Osgood-Schlatter disease, 206
osteoblastoma, 170
osteoblasts, 2
osteocalcin, 2
osteochondral defect (OCD), 121
osteochondral exostosis (OCE), 171
osteochondral lesions of talus, 153
osteochondroma, 172
osteoclasts, 2
osteoconduction, 5
osteofibrous dysplasia (OFD), 178
osteogenesis imperfecta, 212
osteoid osteoma, 145, 163, 170, 184
osteoinduction, 5
osteolysis, 82–83
osteomalacia, 3
osteomyelitis, 11, 201
osteonectin, 2
osteopetrosis, 3, 212
osteopontin, 2
osteoporosis, 3, 229
osteosarcoma (OS), 170–171
osteosclerotic myeloma, 175
Oswestry Disability Index, 220
outcomes research, 245
ovarian carcinoma, 192
overhead athlete, 111
Oxford mobile-bearing system, *92f*
oxygen, 238

P

p value, 244
Pacinian corpuscles, *8t*, 21, 135
Paget disease, 178
Paget's sarcoma, 178
paracrine, 8
parathyroid adenoma, 4
Parona's space, 128, 143
parosteal osteosarcoma, *171t*
patella
dislocation, 61
fracture, 60–61
ossification, 206
overview, 121
sleeve fracture, 215
tendon rupture, 61
patellar tendinitis, 121
patellofemoral articulation, 91
pathologic fracture, 171
pathologic gaits, 237
Patrick's test, 220
PCL (posterior cruciate ligament), 28, 118–119
pectoralis major, 17
pediatric amputations, 206, 239
pediatric both-bone forearm fracture, 47
pediatric femur fracture, 58
pediatric halo, 225
pediatric lateral condyle fracture, 45
pediatric medial epicondyle fracture, 45
pediatric olecranon fracture, flexion type, 46
pediatric orthopaedics
diseases, 196–201
dysplasias, 209–212
lower extremity, 203–209
syndromes, 210, 212
trauma, 212–215
upper extremity, 201–203
pediatric supracondylar humerus fracture, 45
pediatric tumors, 185
pedicle fracture of C2, 223–224
pelvic crush injury, 49
pelvic osteotomies, 79, 204
pelvic ring injuries, 49–50
pelvis and lower extremity trauma
acetabular fracture, 51–52
Achilles tendon rupture, 66–67
acute peroneal tendon dislocation, 67
ankle fracture, 65–66
calcaneus fracture, 68–69
compartment syndrome of foot, 71
cuboid fracture, 69
distal femur fractures, 58–59
femoral head fracture, 53
femoral neck fracture, 53–54
femoral neck stress fracture, 54
femoral shaft fracture, 56–58
hip dislocation, 52–53
intertrochanteric hip fracture, 54–55
knee dislocation, 59–60
lisfranc fracture–dislocation, 70
metatarsal fracture, 70
MTP joint dislocation, 71
navicular fracture, 69
open ankle fracture, 66
Os peroneum, 67
patella dislocation, 61
patella fracture, 60–61
patella tendon rupture, 61
pediatric femur fracture, 58
pelvic ring injuries, 49–50
phalangeal fracture, 71
quadricep tendon rupture, 61
sacral fracture, 50–51
subtalar dislocation, 68
subtrochanteric hip fracture, 55–56
syndesmotic disruption, 66
talar neck fractures, 67
talar process fracture, 68
tibial plafond, 64–65
tibial plateau fracture, 61–62
tibial shaft fracture, 62–64
"turf toe", 71
Pemberton osteotomy, 79
periacetabular osteotomy, 79
perioperative problems, 242–243
periosteal chondroma, 172
periosteal OS, *171t*
periprosthetic fracture, 92–93, 99
peroneal spastic flatfoot, 209
peroneal tendons, *29f*, 158
peroneus brevis, 151
Perthes disease, 212
PFFD (proximal femoral focal deficiency), 205
phalangeal fracture, 71
phantom limb pain, 240
Phemister's law, 100, 191
phosphate diabetes, 4
physaliferous cells, 174

pigmented villonodular synovitis (PVNS), 163, 182
PIN (posterior interosseous nerve), 22, 48, 113, 138
Pin Palsy, 142
PIP (proximal interphalangeal) dislocation, 146
pisiform fracture, 115
pistoning, 239
pitcher's elbow, 114
plantar fasciitis, 153
plantar fibroma, 153
plantar plate, 156
plasmacytoma, 228
plastic region, 14
plexus injuries. *See* spinal cord injury
PLRI (posterolateral rotatory instability) elbow, 22, 113
PMMA (polymethylmethacrylate), 101
PNET (primitive neuroectodermal tumor), 176
POEMS syndrome, 175
Poland syndrome, 140
polio, 160, 236
pollicization, 140
POLO (Pull Out, Lift Off), 95
polyarteritis nodosa, 132
polycentric knee, 239
polymethylmethacrylate (PMMA), 101
polyostotic form, 178
Ponsetti casting, 207
popliteal artery, 28
positive predictive value, 244
posterior approach, hip, 27
posterior cord syndrome, 36, *219t*
posterior cruciate ligament (PCL), 28, 118–119
posterior glenohumeral dislocation, 42–43
posterior interosseous nerve (PIN), 22, 48, 113, 138
posterior knee dislocation, *59f*
posterior SC joint dislocation, 40–41
posterior tibial tendon (PTT), 151, 157
posterolateral corner, 119
posterolateral rotatory instability (PLRI) elbow, 22, 113
posteromedial bowing of tibia, 207
postganglionic brachial plexus injuries, 40
postoperative diskitis, 227
posttraumatic ankle arthrosis, 65
posttraumatic degenerative joint disease, 52
posttraumatic subtalar arthrosis, *68t*
power, defined, 244
power analysis, 244
practice principles, 243
precision, 244
precoated stems with PMMA, 101
prefabricated antibiotic and soft tissue temporary spacer, *100f*
preganglionic brachial plexus injuries, 40
preoperative Hgb, 101
prepatellar abscess, 121
press-fit technique, 76
press-fit TKA, 89
prevalence, defined, 243
primitive neuroectodermal tumor (PNET), 176
prognostic factors, orthopaedic tumor, 185
proliferative zone, 6
pronator syndrome, 136
proportionate dwarf, 211
prospective cohort, 245
prosthetics
  below-knee amputation, 239
  foot and ankle, 165
  shoulder arthroplasty, 97
  total knee arthroplasty, 88–89
protective sensation, diabetic, 162
proteoglycans, 2, 7, 124
proximal bone growth, *213t*
proximal femoral focal deficiency (PFFD), 205
proximal humerus fracture, 43–44
proximal interphalangeal (PIP) dislocation, 146
proximal metaphyseal fracture, 215
PS (cruciate-sacrificing) systems, 89
pseudoachondrodysplasia, 209
pseudogout, 161
pseudohypoparathyroidism, 4
Pseudomonas aeruginosa, 162
pseudosubluxation, 200, 224
psoriatic arthritis, 131, 132
PTT (posterior tibial tendon), 151, 157
Pull Out, Lift Off (POLO), 95
pulleys, 22
pulmonary embolisms, 220
pulmonary hypertrophic osteoarthropathy, 133
pulmonary perioperative problems, 242
PVNS (pigmented villonodular synovitis), 163, 182
pyoderma gangrenosum, 143
pyogenic granuloma, 145, 183

Q

quadricep tendon rupture, 61

R

RA (rheumatoid arthritis), 9, 86, 131, 155, 161
radial club hand, 139, 202
radial head fracture, 46, 214
radial nerve
  arm/forearm, 21–22
  compression, 138
  transfers, 142
radial tunnel syndrome, 138
radial-side wrist pain, 128–129
radiation, 189–190
radiocarpal arthritis, 132
radioulnar synostosis, 139, 202
radius approaches, 47
radius fracture, 47
RANKL, 2–3, 191
Ray resection, 163
Raynaud's lesion, 132
recurrent radial artery, 22
red, swollen MTP joint, 160
reflex sympathetic dystrophy (RSD), 95, 121
regression analysis, 245
rehabilitation, 99, 234–237
Reiter's syndrome, 9
reliability, 244
renal cell tumors, 191
replantation, hand, 134
research hypothesis, 244
reserve zone, 6
resuscitation, 34
retinoblastoma, 170
revision femoral stem, *83f*
revision THA, *78f*
revision TKA, 91–92
revision TSA, 99
rhabdomyosarcoma, 182
rheumatoid arthritis (RA), 9, 86, 131, 155, 161

rheumatoid C-spine, 222
rigid PTT deformity, 158
Rolando fracture, 148
rose thorn, 142
rotary dislocation, 146
rotator cuff
  repair, 235
  tears, 107–108
rotatory subluxation, 200
RSD (reflex sympathetic dystrophy), 95, 121
Ruffini end organs, *8t*
Russell-Taylor subtrochanteric hip fracture classification, 55

S

SACH (solid ankle cushioned heel), 239
sacral agenesis, 201
sacral fracture, 50–51
sacral lesions, 186
sacroiliac (SI) joint dislocations, 50
sacroiliac (SI) joint infection, 201
sacroiliac (SI) screws, 26
sagittal band, 22
Sanders calcaneus fracture classification, *68t*
sarcomas
  epithelioid, 144–145, 183–184
  Ewing's, 176
  Paget's, 178
  soft tissue, 183
  synovial cell, 192
SBC (simple bone cyst), 177
SC (sternoclavicular) joint dislocation, 40–41, 111–112
scalene block, 124
scaphoid fractures, 129, 146–147, *148f*
scaphoid nonunion, 132
scaphoid nonunion advanced collapse (SNAC), 129
scapholunate advanced collapse (SLAC) wrist, 130
scapholunate interosseous ligament, 22
scaphotrapeziotrapezoid (STT) arthritis, 129
scapula fracture, 41, *42f*
scapular winging, 110–111
scapulothoracic dissociation, 41–42
SCFE (slipped capital femoral epiphysis), 205
Schatzker tibial plateau fracture classification, 62
Scheuermann's kyphosis, 199, 229
SCI. *See* spinal cord injury
sciatic nerve, 9, 26, *26t*
scleroderma, 133
scoliosis, 196–199
second-generation cementing technique, *75t*
SED (spondyloepiphyseal dysplasia), 209–210
selection bias, 244
senile osteoporosis, 3
sensitivity, 244
septic joints, 201
sequestrum, 180
seronegative spondyloarthropathies, 161
serum protein electrophoresis (SPEP), 175
sesamoids, 157
Sever disease, 122
SGHL (superior glenohumeral ligament), 107
shoe nail puncture, 162
shoulder
  acromioclavicular injuries, 111
  additional key facts, 112
  adhesive capsulitis, 108–109
  anatomy, 107
  anterior instability, 109–110
  arthroplasty, 96–99, 112
  calcific tendonitis, 109
  chronic posterior glenohumeral dislocation, 110
  overhead athlete, 111
  rotator cuff tears, 107–108
  scapular winging, 110–111
  shoulder arthroplasty, 112
  SLAP lesions, 108
  sternoclavicular dislocation, 111–112
SI. *See sacroiliac entries*
sickle cell disease, 12, 87
significance level, 244
simple bone cyst (SBC), 177
simple finger fracture, 146
skin grafts, 135
SLAC (scapholunate advanced collapse) wrist, 130
SLAP (superior labral anterior–posterior) lesions, 108
SLE (systemic lupus erythematosus), 133
slipped capital femoral epiphysis (SCFE), 205
slow-twitch type I muscle fibers, 7
Smith-Peterson approach, 26
SMO (superior migration of odontoid), 222
SNAC (scaphoid nonunion advanced collapse), 129
snapping hip, 116
snowboarder's fracture, 68
sodium deficiency, 124
soft tissue
  lesions, 180
  sarcomas, 183
  tumors, 188
solid ankle cushioned heel (SACH), 239
solitary plasmacytoma, 175
spacticity, 197
specificity, 244
SPEP (serum protein electrophoresis), 175
spinal cord injury (SCI)
  ankylosing spondylitis, 39
  bilateral C-spine facet subluxation/dislocation, 39
  burst fracture, 40
  C1–2 instability, 37
  C2 Hangman's fracture, 37
  cervical trauma, 37
  complete, 219
  cricothyrotomy, 36
  flexion–distraction injury, 39–40
  gunshot wounds, 220
  incomplete cord syndromes, 36
  incomplete spinal cord injury, 37, *219t*
  ipsilateral C-spine lamina and pedicle fracture, 39
  nasotracheal intubation, 36
  neurogenic shock, 219
  neurologic level, 36
  odontoid fractures, 37–38
  rehabilitation, 235
  steroid protocol, 36
  steroids, 220
  unilateral C-spine facet fracture, 38–39
spinal muscular atrophy, 201
spine
  adult spine deformity, 228–229
  cervical spine, 221–225
  degenerative spondylolisthesis, 228
  general spine, 219–221

spine (*Cont.*):
head injuries and, 123–124
isthmic spondylolisthesis, 228
lumbar spine, 225–227
tumors, 227–228
spinoglenoid cysts, 108, *109f*
split-thickness skin grafts, 135
spondyloepiphyseal dysplasia (SED), 209–210
spondylolysis, 200
spondylometaphyseal dysplasia, 211
sporothrix, 12
sports medicine
lower extremities
foot and ankle, 121–123
hip, 115–116
knee, 116–121
spine and head injuries, 123–124
upper extremities
elbow, 113–114
hand, 114–115
shoulder, 107–112
sprain, ankle, 152
Sprengel's deformity, 202
spring ligament, 29
squamous cell carcinoma, 144, 145, 184
standard deviation, 244
static stabilizers, 17
statistics, 243–244
statute of limitations, 246
stem breakage, 75
stenosis, 222
steppage gait, 237
sternoclavicular (SC) joint dislocation, 40–41, 111–112
steroids
anabolic, 7, 242
corticosteroids, 3
spinal cord injury, 220
strength training, 235
stress shielding, 76
stress–strain graph, *15f*
stroke
overview, 160
rehabilitation, 235
STT (scaphotrapeziotrapezoid) arthritis, 129
studies, 245
subacromial steroid injection, 124
subcutaneous granuloma annulare, 180
subscapularis avulsion, 96
subtalar dislocation, 68
subtalar instability, 152
subtrochanteric hip fracture, 55–56
subungual exostosis, 163
superficial arch, 128
superficial peroneal nerve, 9, 123
superficial radial nerve, 22
superior glenohumeral ligament (SGHL), 107
superior labral anterior–posterior (SLAP) lesions, 108
superior migration of odontoid (SMO), 222
supracondylar femur fracture, *93f*
supracondylar process, 113
suprascapular nerve, 9
sural nerve, 151
surface lesions, 186
Swan-Neck deformity, 128, 134
sweaty feet, 241
symbrachydactyly, 141
Syme's amputation, 163, 238
sympathetic chain, 222
symphylangism, 139
symptomatic cervical spondylosis, *223t*
syndactyly, 139
syndesmosis injury, 122
syndesmotic disruption, 66
syndromes, 210, 212
synovial cell sarcoma, 192
synovial cells, 124
synovial disorders, 182–183
systemic lupus erythematosus (SLE), 133

T

Takayasu's arteritis, 132
talar neck fractures, 67
talar osteochondral lesion, 122
talar process fracture, 68
talus
trauma, 164
vascular supply, 151
tarsal coalition, 163
Tarsal Tunnel syndrome, 159
Telangiectatic OS, 170–171
tendons
Boutonniere deformity, 134
disorders, 157–158
extensor, 133
flexor, 133
overview, 133
repair, 133
Swan-Neck deformity, 134
transfers, 141–142
Tennis Elbow, 113
tension pneumothorax, 35
tension signs, lumbar spine, 226
teres major, 17
teres minor, 17
tests, 245
TFCC (triangular fibrocartilage complex) tear, 129
TGF-β, 2
THA, *see* total hip arthroplasty
Thenar flap, 135
third body wear type, 15
Thomspson approach, 21
thoracic and lumbar compression fracture, 215
thoracic outlet syndrome, 138
thoracolumbosacral orthosis (TLSO), 220
thromboangiitis obliterans, 132
thumb, 135
thumb carpometacarpal joint, 131
thyroid metastases, 179
tibial cut, 88
tibial hemimelia, 207
tibial lesions, 186
tibial plafond, 64–65
tibial plateau fracture, 61–62
tibial shaft fracture, 62–64
tibial torsion, 206
tibial tubercle avulsion, 121
tibial tubercle fracture, 215
tillaux fracture, 215
TKA. *See* total knee arthroplasty
TLSO (thoracolumbosacral orthosis), 220
tobacco, 241
toddler's fracture, 215
toe walking, 197
total ankle arthroplasty, 161
total hip arthroplasty (THA)
with modular system, *77f*
polyethylene wear, *85f*
wear, 83–84
total hip replacement
acetabular periprosthetic fracture, 82
arthrodesis, 79–80
avascular necrosis, 85
biologic fixation, 75
cement fixation, 75–76
developmental dysplasia of hip, 76–77
dislocation in THA, 81–82

femoral periprosthetic fracture, 82
hip arthroscopy, 86
hip loosening, 85
hip/pelvis osteotomy, 79
miscellaneous, 86–87
osteolysis, 82–83
revision THA, 77–79
search for ideal bearing surface, 84–85
stress shielding, 76
techniques, 76
THA wear, 83–84
total knee arthroplasty (TKA)
arthrodesis, 94–95
bilateral, 91
component positioning, 89–90
knee osteotomy, 93–94
ligament balancing, 96
miscellaneous, 95–96
osteolysis, *90f*
patellofemoral articulation, 91
periprosthetic fracture, 92–93
prosthetic design, 88–89
revision, 91–92
surgical technique, 88
unicompartmental knee arthroplasty, 91
valgus knee, 91
varus knee, 91
wear, 90
total shoulder arthroplasty, 99
toughness, bone, 14
toxic shock syndrome, 11
transfusion complications, 242
transmetatarsal, 163
transperitoneal approach to L5–S1, 226
transverse patella fracture, *60f*
trapezius winging, 110
trauma. *See also* pelvis and lower extremity trauma; upper extremities
brachial plexus injuries, 40
foot and ankle, 164
general, 34–36
hand, 145–147
pediatric orthopaedics, 212–215
spinal cord/plexus injuries, 36–40
trauma x-ray series, 35
traumatic mydriasis, 123
Trevor disease, 211
triangular fibrocartilage complex (TFCC) tear, 129
triceps, 21
triplane fracture, 215
triple arthrodesis, 161
tumor suppressor gene, 191
tumoral calcinosis, 112, 192
tumors
hand, 144–145
orthopaedic
benign tumor staging, 184
biopsy, 187
bisphosphonate therapy, 190
bone tumors of unknown origin, 175–177
bone-producing lesions, 170–171
cartilage-producing lesions, 171–173
chemotherapy, 188–189
common chromosomal translocations, 191
diagnostic tumor continuum, 185
epiphyseal tumors, 185
fatty tissue lesions, 181
fibrous lesions of bone, 173
hand, 183–184
hematopoietic bone lesions, 174–175
histiocytic lesions of bone, 174
immunostains, 188
lesion on both sides of joint, 186
malignant tumor staging, 184–185
MC FIE, 187
multiple lesions, 187
muscle lesions, 182
neural tissue lesions, 181–182
oncogenes, 191
pediatric tumor, 185
prognostic factors, 185
radiation, 189–190
RANKL, 191
sacral lesions, 186
sarcomas of soft tissue, 183
soft tissue lesions, 180
surface lesions, 186
synovial disorders, 182–183
tibial lesions, 186
treatment, 190
tumor resection, 188
tumor suppressor gene, 191
tumor workup, 187
tumor-like conditions of bone, 177–180
tumors with soft tissue mineralization, 185–186
vascular lesions, 182
vascular lesions of bone, 174
spinal, 227–228
turf toe, 71, 122, 156
two-sample t-test, 245
Type I error, 244
Type I postmenopausal bone disorder, 3
Type II error, 244
Type II senile bone disorder, 3

U

UCBL (University of California Berkley Lab), 165
UHMWPE (ultra-high-molecular-weight polyethylene), 84
UKA (unicompartmental knee arthroplasty), 91
ulna fracture, 47
ulnar club hand, 139, 202–203
ulnar impaction syndrome, 49
ulnar nerve
compression, 137
elbow, 22
lesions, 22
ulnar styloid fracture, 49
ulnar tunnel syndrome, 137
ulnar-side wrist pain, 129
ultimate strength, 14
ultra-high-molecular-weight polyethylene (UHMWPE), 84
ultrasound (US), 234
unicompartmental knee arthroplasty (UKA), 91
unilateral C-spine facet fracture, 38–39
University of California Berkley Lab (UCBL), 165
upper extremities
amputation, 237
elbow, 113–114
hand, 114–115
motor exam, 236
pediatric orthopaedics, 201–203
prosthetic limbs, 237
shoulder, 107–112
trauma
acromioclavicular injuries, 41
clavicle fractures, 41
coronoid fracture, 46

upper extremities (*Cont.*):
distal humerus fracture, 45
distal radius fracture, 48–49
elbow dislocation, 46
floating shoulder, 41
Galeazzi fracture, 47
glenohumeral dislocations, 42–43
humeral shaft fracture, 44–45
Little Leaguer's shoulder, 43
Monteggia fracture, 48
olecranon fracture, 46
pediatric both-bone forearm fracture, 47
pediatric lateral condyle fracture, 45
pediatric medial epicondyle fracture, 45
pediatric olecranon fracture, flexion type, 46
pediatric supracondylar humerus fracture, 45
PIN injury, 48
proximal humerus fracture, 43–44
radial head fracture, 46
radius approaches, 47
radius/ulna fracture, 47
scapula fracture, 41
scapulothoracic dissociation, 41–42
sternoclavicular joint dislocation, 40–41
ulnar impaction syndrome, 49
ulnar styloid fracture, 49
urinary tract infection, 246
urogenital injuries, 50
US (ultrasound), 234

V

valgus knee, 91
validity, 244
Vancouver classification, 82
variance, 244
varus knee, 91
vascular amputations, 238
vascular claudication, 235
vascular lesions
of bone, 174
hand, 132–133
pediatrics, 182
vascularized grafts, 135
vertebra plana, 177
viability, 4 Cs of, 36
Virchow's triad, 13, 242
vitamin D, 3–4
volar dislocation of PIP, 145
volar ligaments, 130
Volkmann's ischemic contractures, 133
voluntary opening hook, 237
Von Recklinghausen's lesions, 181, 200
von Willebrand factor, 13

W

Wallerian degeneration, 138
warfarin, 13
Wartenberg syndrome, 138
Watson-Jones approach, 26
Windlass mechanism, 121–122
Winking Owl tumor, 227
worker's compensation, 246
wound healing, amputation, 238
wrist, 128–130

X

x-rays, 35, 152

Y

yield points, 14
yield strength, 14
Young's modulus, 14

Z

zone/quadrant risks, arthrodesis, 80

NOTES

NOTES